BRITISH HEART JOURNAL

Volume IV
1942

LONDON
Reprinted by offset litho for
WM. DAWSON & SONS LTD
4 Duke Street, Manchester Square, London. W.1
By permission of the British Medical Association
1957

EDITORS

MAURICE CAMPBELL
D. EVAN BEDFORD

EDITORIAL BOARD

CRIGHTON BRAMWELL, MANCHESTER
BOYD CAMPBELL, BELFAST
JOHN COWAN, GLASGOW
FRANCIS R. FRASER, LONDON
A G. GIBSON, OXFORD
JOHN HAY, LIVERPOOL
SIR THOMAS LEWIS, LONDON
HENRY MOORE, DUBLIN
JOHN PARKINSON, LONDON
W. T. RITCHIE, EDINBURGH
K. D. WILKINSON, BIRMINGHAM
EDITOR OF BRITISH MEDICAL JOURNAL

APPOINTED BY

THE CARDIAC SOCIETY OF GREAT BRITAIN AND IRELAND

CONTENTS OF VOLUME IV

Numbers 1 and 2

		Page
Two Cases of Digitalis Poisoning	By K. Douglas Wilkinson	1
Congenital Heart Block.	By William Stein and J. S. Uhr	7
Congenital Pulmonary Stenosis with Left Ventricular Enlargement Associated with Atrial Septal Defect.	By Paul Wood	11
Infarction of the Cardiac Auricles (Atria)	By E. H. Cushing, H. S. Feil, E. J. Stanton and W. B. Wartman	17
Prognosis of Right Bundle Branch Block.	By George A. Perera, Samuel A. Levine, and Herman Erlanger	35
Dr. Samuel Johnson : The Medical History as Recorded by James Boswell	By Terence East	43
Inversion of T Waves after Long Paroxysms of Tachycardia	By Maurice Campbell	49

Number 3

A Curious Syndrome, with Signs Suggesting Cervical Arterio-venous Fistula, and the Pulses of Neck and Arms Lost	By Thomas Lewis and Joan Stokes	57
The Conducting System of the Vertebrate Heart.	By Francis Davis	66
A Sino-Auricular Node : A Historical Note	By Arthur Keith	77
Chest Leads in Congenital and Acquired Dextrocardia	By J. S. Richardson	80
Electrocardiographic Changes due to Trauma	By Hugh Barber	83
Electrocardiogram in Friedreich Disease	By William Evans and Gordon Wright	91
Intracardiac Tumours	By J. L. Hamilton-Paterson and L. I. M. Castleden	103
Graham Steell	By Crighton Bramwell	115

CONTENTS OF VOLUME IV (*continued*)

Number 4

Page

HEMIPLEGIA IN CYANOTIC CONGENITAL HEART DISEASE By Beryl Corner and Bruce Perry 121

CONGENITAL PULMONARY ATRESIA WITH CEREBRAL THROMBOSIS AND HEMIPLEGIA By Alastair Hunter and John M. Lipscomb 124

PARTIAL HEART BLOCK DUE TO DIGITALIS By Maurice Campbell 131

BLOOD PRESSURE AND OLD AGE By Trevor H. Howell 143

TRANSIENT INVERTED T WAVES AFTER PAROXYSMAL TACHYCARDIA By George M. Currie 149

PROGNOSIS OF PAROXYSMAL TACHYCARDIA AND PAROXYSMAL AURICULAR FILBRILLATION By W. Trevor Cooke and Paul D. White 153

FAINTING AND FITS IN CARDIAC INFARCTION By Harold Cookson 163

PROCEEDINGS OF THE CARDIAC SOCIETY OF GREAT BRITAIN AND IRELAND 174

INDEX 180

TWO CASES OF DIGITALIS POISONING

BY

K. DOUGLAS WILKINSON

From the Birmingham United Hospital

Received October 14, 1941

In 1785 Dr. William Withering of Birmingham wrote, " The Foxglove when given in very large and quickly repeated doses, occasions sickness, vomiting, purging, giddiness, confused vision, objects appearing green or yellow; increased secretion of urine, with frequent motions to part with it, and sometimes inability to retain it; slow pulse, even as slow as 35 in a minute, cold sweats, convulsions, syncope, death. I am doubtful whether it does not sometimes excite a copious flow of saliva.

" When given in a less violent manner, it produces most of these effects in a lower degree; and it is curious to observe that the sickness with a certain dose of the medicine does not take place for many hours after its exhibition has been discontinued; that the flow of urine will often precede, sometimes accompany, frequently follow the sickness at the distance of some days, and not unfrequently be checked by it. The sickness thus excited is extremely different from that occasioned by any other medicine; it is peculiarly distressing to the patient; it ceases, it recurs again as violent as before; and thus it will continue to recur for three or four days, at distant and more distant intervals.

" At first I thought it necessary to bring on and continue the sickness, in order to ensure the diuretic effects. Therefore my patients were ordered to persist until the nausea came on, and then to stop. But it soon appeared that the diuretic effects would often take place first, and sometimes be checked when the sickness or a purging supervened.

" The direction was therefore enlarged thus—Continue the medicine until the urine flows, or the sickness or purging take place. I found myself safe under this regulation for two or three years; but at length cases occurred in which the pulse would be retarded to an alarming degree, without any other preceding effect.

" The directions therefore required an additional attention to the state of the pulse, and it was moreover of consequence not to repeat the doses too quickly, but to allow sufficient time for the effects of each to take place, as it was found very possible to pour in an injurious quantity of the medicine before any of the signals for forbearance appeared.

" Let the medicine therefore be given in the doses, and at the intervals mentioned above:—let it be continued until it either acts upon the kidneys, the

stomach, the pulse, or the bowels; let it be stopped upon the first appearance of any of these effects, and I will maintain that the patient will not suffer from its exhibition, nor the practitioner be disappointed in any reasonable expectation.

"From some cases, which have occurred in the course of the present year, I am disposed to believe that the digitalis may be given in small doses, viz., two or three grains a day, so as gradually to remove a dropsy, without any other than mild diuretic effects, and without any interruption to its use until the cure be completed.

"If inadvertently the doses of the Foxglove should be prescribed too largely, exhibited too rapidly, or urged to too great a length, the knowledge of a remedy to counteract its effects would be a desirable thing."

Withering used the Foxglove to promote diuresis; his dosage was so admirable that it remains to-day the standard in general use. His directions were so simple that they cannot be improved, and he was well acquainted with digitalis poisoning, yet did not succeed in impressing upon his contemporaries the importance of the cautious doses he recommended. It is said that Dr. J. Lettson employed the medicine so incautiously that he killed several patients, and certainly many physicians regarded the digitalis as a dangerous drug.

Since Withering wrote we have learned of the active principles of digitalis—the glucosides—and of their action upon the myocardium for which they have a peculiar chemical affinity. Now we use digitalis chiefly in auricular fibrillation with the object of limiting the frequency of the ventricular contraction, prolonging the diastolic pauses, and so improving the nutrition of the heart.

These effects result from the blocking of impulses from the auricles travelling in the A-V bundle. Adequate doses of digitalis may cause complete heart block, either in auricular fibrillation or in sinus rhythm, and high grades of auriculo-ventricular dissociation can be produced relatively easily in hearts that have been damaged by rheumatism. The chemical affinity of digitalis glucosides for the myocardium is much greater than that of strophanthin, so that the effects of digitalis are much more lasting, poisoning may persist for a long time after the discontinuance of the drug, and as yet we have not found the antidote for which Withering hoped.

Even to-day digitalis is still used in dangerous doses, and in the hope of producing impossible results in unsuitable cases, so that poisoning is not uncommon. Marked slowing of the pulse rate and coupling as a result of the appearance of ventricular extrasystoles are the first two cardiac signs of digitalis intoxication. In the two cases here reported there was also widening of the QRS complexes.

First Case

Winifred B., aged 27, gave a history of rheumatic fever at the age of 10, goitre during adolescence, appendicectomy at the age of 18, but otherwise had enjoyed good health until July 1940. Then six-and-a-half months pregnant with her second child, she began to have attacks of paroxysmal tachycardia.

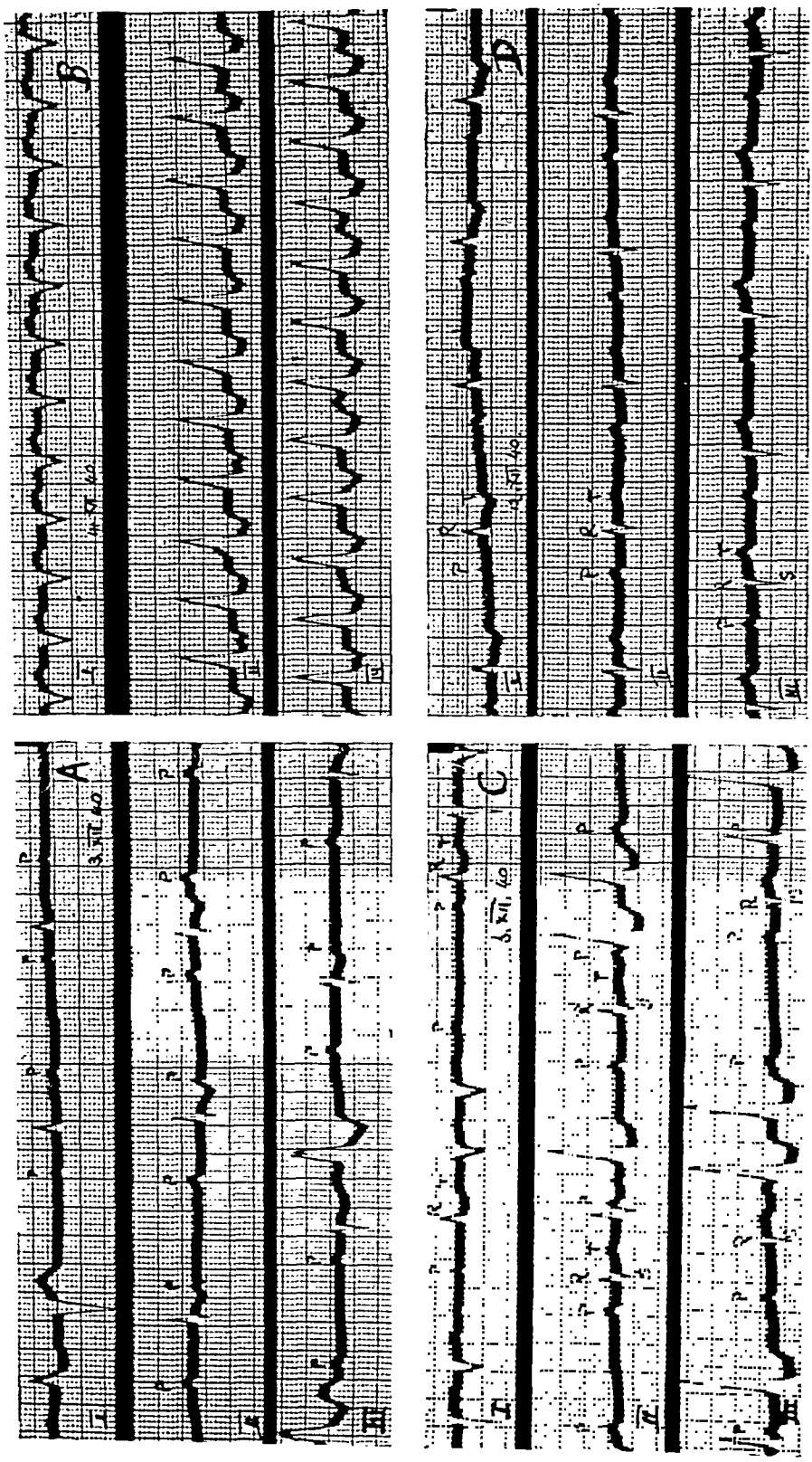

FIG. 1.—(A) Case 1; 3/12/40.—Complete A-V dissociation (auricular rate of 85 and ventricular rate of 34) with ventricular extrasystoles.
(B) Case 1; 4/12/40.—Paroxysmal ventricular tachycardia, rate about 150.
(C) Case 1; 6/12/40.—Ventricular extrasystoles, often in pairs; complete A-V dissociation still present.
(D) Case 1; 9/12/40.—Partial heart block still present, 12 days after the last dose of digitalis.

She was admitted to the Maternity Hospital, where she had a normal delivery, after which the attacks ceased; but a month or so later started again, and on November 27 she was ordered two grains of digitalis leaf every three hours. This she continued to take conscientiously until the day of admission, in spite of the persistence of the attacks of palpitation, nausea, vomiting, and disturbed vision.

When admitted to hospital, under my colleague Professor L. G. Parsons, on December 2, 1940, she was most gravely ill, but was not breathless nor cyanosed. The cardiac impulse could not be felt, the pulse was of small volume, infrequent (less than 50 per minute), and irregular with coupled beats. The tongue was furred and vomiting was frequent; in fact nausea almost prevented her taking anything by mouth and she had to be given rectal saline.

The electrocardiogram taken the day after admission showed a sinus rate of about 85, the P waves being small but quite easily identified; the ventricular rate was variable, about 34 per minute, and there were ventricular extrasystoles of constant form. There was complete auriculo-ventricular dissociation (Fig. 1A).

The paroxysms of ventricular tachycardia, for which the heroic doses of digitalis folia were prescribed in this case, were not modified by the large doses, for the attacks continued, and Fig. 1B shows such an attack on December 4, on which day her heart suddenly changed from an irregular rate of about 40 per minute to a regular rate of nearly 150; this attack only lasted about half an hour, and ceased as abruptly as it began, but she had several subsequent attacks.

Sometimes the ventricular extrasystoles occurred in pairs, which varied in form and appeared to arise from different foci; they were separated by a constant interval. This condition is well seen in Fig. 1C, where each normal ventricular complex is followed by two ventricular extrasystoles. Complete heart block appears to be present on this date also.

On December 8 she was given quinidine sulphate in doses of three grains every two hours for five doses, and this led to an improvement in that the paroxysms of tachycardia ceased; but the persistence of digitalis block is well seen in the record taken on December 12, where the rate has become regular at 64 per minute; the P–R interval was still 0·32 sec., although the digitalis had been stopped twelve days earlier (Fig. 1D). Subsequently she gradually improved and was discharged as cured on January 30, 1941.

Second Case

But adequate doses of digitalis can produce even greater changes in the electrocardiogram than those shown in the first case.

The second patient, William H., aged 57, was admitted under Professor W. H. Wynn on March 21, 1941.

He also gave a history of acute rheumatism as a child, but served in the Army from 1914 to 1920. He had appendicitis in 1933, and in 1939 was admitted to hospital with congestive heart failure. He recovered and returned

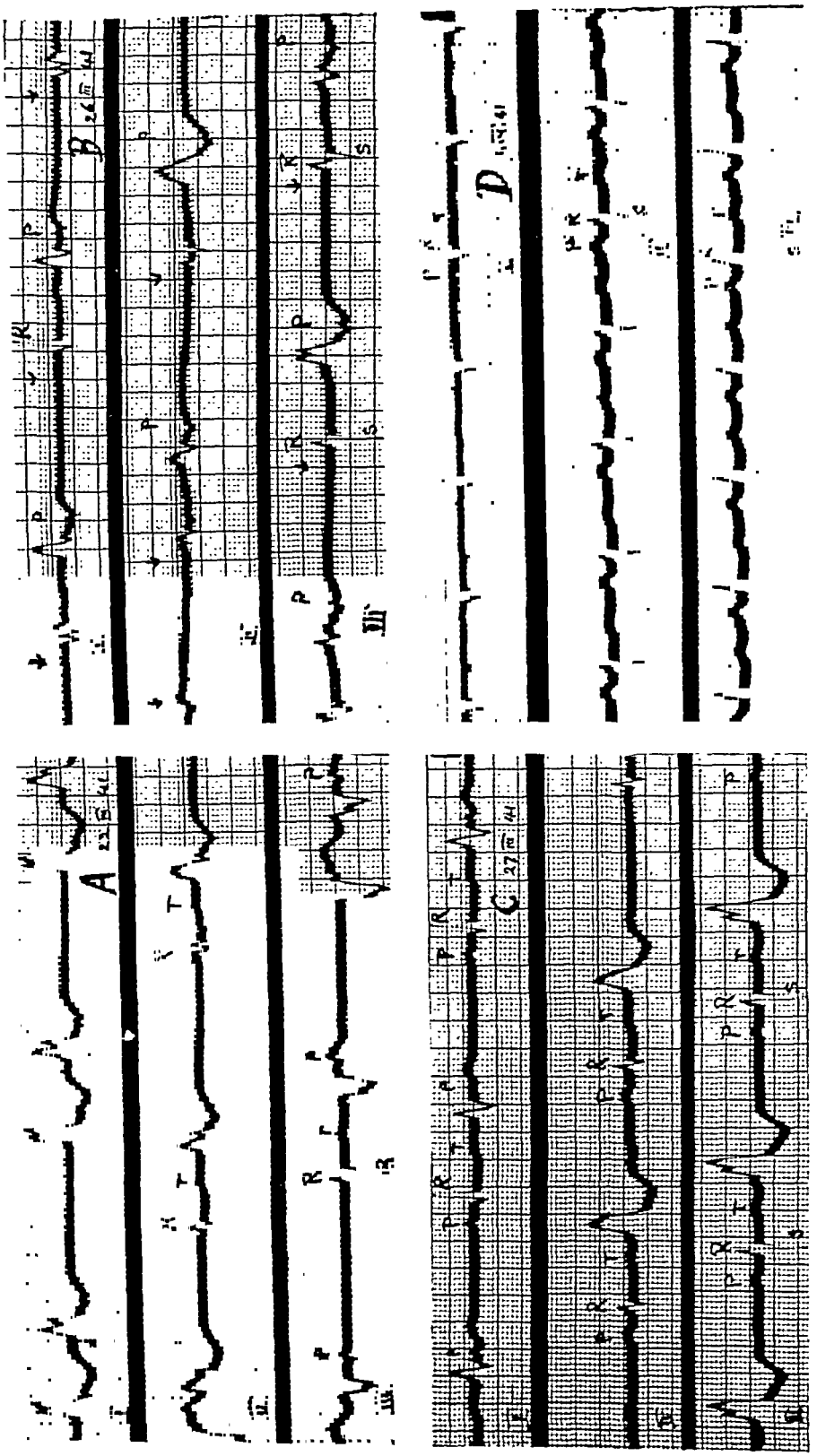

FIG. 2.—(A) Case 2; 22/3/41.—Coupled beats with most complexes of the bundle branch block type (see text).
(B) Case 2; 26/3/41.—Coupled beats with more normal ventricular complexes (see text).
(C) Case 2; 27/3/41.—Coupled beats still present, but P waves now obvious with P–R interval of 0·24 sec.
(D) Case 2; 1/4/41.—Regular sinus rhythm with a P–R interval of 0·20 sec.

to work. In December 1940, he became distressed by increasing dyspnœa and began to have some œdema of the legs. On admission he was plethoric, œdematous, cyanosed, and orthopnœic, and weighed 12 stone 7 pounds (the degree of œdema was shown by the fact that he lost 3 stone in sixteen days). The pulse was infrequent (about 50 per minute), of poor volume, and showed coupled beats. The blood pressure was 175/110. The cardiac impulse was five inches from the mid-line in the seventh left interspace; the heart sounds were distant and he was extremely ill. Before admission he had been taking digitalis, but the dosage was unknown.

The record of March 22, 1941, shows only two ventricular complexes (one in lead II and one in lead III) that are even approximately normal; the remainder appear fairly typical of bundle branch block of the common type, being wide (0·16 sec.), notched, and having T waves directed opposite to the initial deflection (Fig. 2A). This record also shows coupled beats, while the auricular complexes cannot be identified with certainty, but since the ventricular rate is about 30 per minute it seems probable that complete auriculo-ventricular dissociation was present.

Four days later a similar record was obtained, showing the nearly regular ventricle with a frequency of 30, each beat being followed by an extrasystole (Fig. 2B). Here again the ventricular complexes, both the initial complexes and the extrasystoles, show considerable variation in form, although they are separated by an almost constant interval of 0·6 sec., and the auricular complexes can only be identified occasionally: but a day later (Fig. 2C), P waves can be seen, the P–R interval being about 0·24 sec. and constant, and the ventricular complexes much less abnormal; coupling is still present, and the extrasystole is of an abnormal type.

From March 21 to March 28 the pulse varied from 70 to 32 per minute; during the second week it rose to an average of 80, and thereafter was above 80 and regular. On April 1, his electrocardiogram (Fig. 2D) showed a regular sinus rhythm of 77 with a P–R interval of 0·20 sec., the disappearance of extrasystoles, and a constant QRS deflection: S was still deep in leads II and III, but QRS now measured at most 0·09 sec., and T although rather flat was upright. He was discharged much improved on May 24, 1941.

Summary and Conclusions

Two cases of digitalis poisoning in patients with sinus rhythm are recorded. Each showed : (1) complete auriculo-ventricular dissociation; (2) coupled beats; and (3) marked abnormalities in the QRS-T complexes.

Recovery was slow and some degree of heart block persisted for twelve days after the digitalis was discontinued. One case showed bundle branch block as well as auriculo-ventricular block.

CONGENITAL HEART BLOCK:
REPORT OF A CASE

BY

WILLIAM STEIN AND J. S. UHR

From St. Peter's General Hospital, New Brunswick, N.J., U.S.A.

Received October 20, 1941

The comparative rarity of congenital heart block as recorded in medical journals warrants the addition of another case to this collection. Up to 1938 approximately 55 cases have been described.

There is no doubt that one of the reasons for not discovering these cases early in childhood is that signs and symptoms are usually absent or only minimal, and that the heart rate is inclined to be more rapid than in cases with acquired complete heart block (Campbell and Suzman, 1934). It is only when some other medical condition brings such a person to a physician that the heart block may be discovered. Sometimes this person may be examined by several competent doctors before the defect is accidentally stumbled upon. This is illustrated by the presentation of the following case.

A white, female child, aged 3 years, was brought to the hospital in February 1940 with the complaint of a purulent discharge from the right ear of one year's duration. This had started four months after an uneventful convalescence from measles, when she had been treated by a physician who made no comment about her heart. Two previous attacks of acute bronchitis also requiring the attention of a physician had caused no comment relative to her heart. Otherwise she had always been a normal-looking, well-nourished, and healthy, active youngster, without any cardiac signs or symptoms. She was a full-term baby, delivered normally, and experienced no difficulties in her babyhood. A clinical diagnosis of right acute mastoiditis was made. There were no other findings at this time. The intern made a note that he heard no murmurs over the praecordium but did not record the pulse or cardiac rate. The nurse's chart showed a pulse rate of 80. She had an operation on the same day.

During the entire time of operation the anæsthetist noted the pulse rate as being 56, and brought it to the surgeon's attention. Her condition despite this rate was good. The oto-laryngologist commented on the possibility of the low rate being due to an intradural abscess, and after completing a simple mastoidectomy asked for a neurological consultation.

Two days later the neurologist reported that he found no neurological signs, and suggested that a pædiatrician should look for some congenital anomaly because of the bradycardia.

It was then that a pædiatrician (J. S. U.) first saw her and noted "an extensive bradycardia and a low musical murmur, systolic in time, heard all over the præcordium, but loudest at the apex and fourth left intercostal space near the sternum." This was thought to be a murmur that could be accounted for most logically on the basis of a patent interventricular septum being present, inasmuch as after it had been heard it had always been present and had never varied in intensity, quality, or location.

An electrocardiogram revealed an auricular rate of 120, a ventricular rate of 70, complete heart block, a tendency to left axis deviation, and a diphasic T wave in lead IV F (Fig. 1).

Fluoroscopic and radiographic examination of the heart revealed enlargement of both the right and left ventricles and left auricle (Fig. 2). The lung

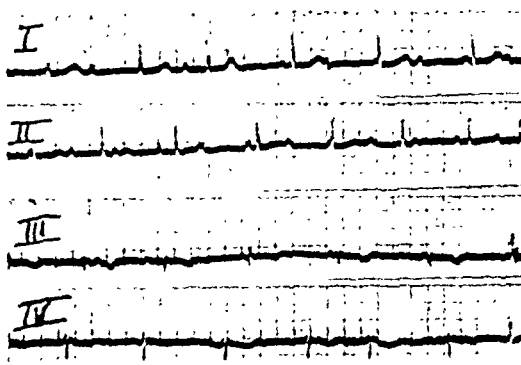

FIG. 1.—Electrocardiogram showing complete heart block (A, 120; V, 70).

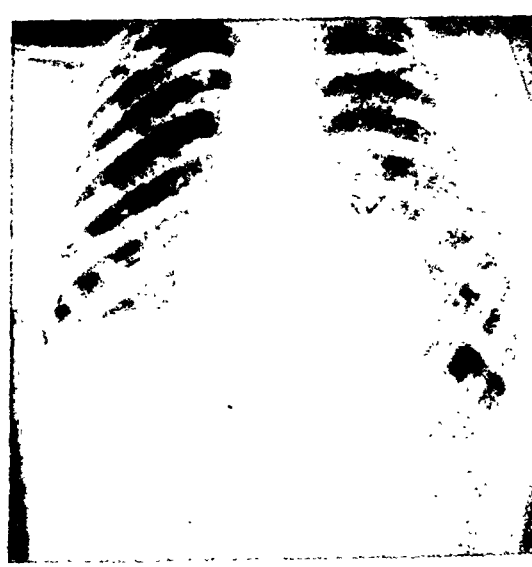

FIG. 2.—Radiogram of heart showing enlargement of the right and left ventricles.

fields were clear. Barium in the œsophagus in the right (I) oblique view showed an indentation of the œsophagus from a moderately enlarged left auricle.

Other laboratory findings were as follows. There was no abnormality of the urine except for a faint trace of albumin. Complete blood count: haemoglobin, 78 per cent; red blood corpuscles, 4,560,000; white blood corpuscles, 9050, with a normal differential count.

The rectal temperature on admission was 99·6° F. and varied from 100 to 99 until the patient was discharged.

The nurse's chart recorded a pulse average of from 56 to 52 during the patient's stay in hospital. The respirations averaged from 24 to 28 per minute.

The patient responded well to the operation and was discharged after two weeks, returning to the out-patient department for mastoid surgical dressings and follow-up in the pædiatric clinic. Two months later another electrocardiogram during one of her visits to the out-patient department again showed complete heart block.

Her convalescence from the right mastoidectomy was uneventful.

Discussion

Complete heart block represents an inability of the stimulating impulses originating in the sino-auricular node to pass through the auriculo-ventricular node and the main bundle of His, so that the auricles beat at their own rate while the ventricles contract at the rate governed by the auriculo-ventricular node that has taken over the function of pacemaker, which is usually 30 to 50 beats per minute, or if conduction from the latter is impaired also, then at their own ventricular rate, which is usually below 40 beats per minute. This heart block may be either congenital, which is rare, or acquired, which is more usual.

Yater (1929) reviewed 30 cases of congenital heart block reported up to that time, and established certain criteria that would permit one to classify a case as being congenital. These were the following five points:

1. Electrocardiographic evidence of the block existing.
2. A slow pulse that had been found present at an early age and had continued to be present.
3. The absence of any history suggestive of an infection that might have produced the block, as diphtheria, congenital or early acquired syphilis, rheumatic fever, or chorea.
4. A history of any one of the following: syncopal attacks, fainting spells (explained on the basis of the Adams-Stokes syndrome), vertigo, headaches, nausea and vomiting after unusual exertion, convulsions, dyspnœa, and/or cyanosis. (These findings may or may not be present and are not absolutely requisite for the criteria, but if present add further evidence.)
5. The presence of a congenital heart lesion, namely, patent interventricular septum (the latter at times being subject to an acquired endo-myocarditis, quite infrequent in this instance as far as the septum itself is concerned).

While theoretically it might be possible to explain the heart block on a prenatal myocarditis or syphilis involving the bundle of His or a developmental

defect affecting the bundle of His, these are most unlikely to occur for practical considerations.

This case fits the criteria of Yater (1929).

The ætiology of congenital heart block is organic and is based on the pathological presence of a patent interventricular septum. Such septal defects, both large and small, are a common deformity and are found relatively frequently. Why they occur clinically without the presence of heart block so often, is odd, but has been explained correctly as follows : The usual sight of the interventricular defect is anterior to the pars membranacea while the A-V bundle lies behind it (Leech, 1930). Inasmuch as the ventricular complexes in the electrocardiogram of complete heart block are normal, it follows that the lesion responsible for the block must be in the course of the main bundle of His, above the bifurcation close to the septum (Lampard, 1928).

The reason for the almost constant preservation of the muscular connection between the auricles and ventricles probably lies in the fact that the special bundle appears in the fifth week of fœtal life, whereas the membranous separation between auricles and ventricles take form between seven and ten weeks. The bundle is preserved between the posterior endocardial cushion and the posterior portion of the annular fibrosis (Yater, Leaman, and Cornell, 1934; Moll, 1912; and Tandler, 1913).

It is only when the A-V node or main bundle of His is caught in the congenital anomalous development of the septum, or is caught in the excessive formation of fibrous tissue of the membranous portion of the septum interfering with the continuity of the bundle, that heart block occurs (Aitken, 1932).

The prognosis in general is guarded. A few cases have reached mature adult life. It must be remembered that a patent interventricular septum is associated often with other congenital cardiac anomalies, the most frequent being the tetralogy of Fallot. These anomalies are overshadowed by the dangers of an engrafted endocarditis. If the concomitant anomalies are small and do not limit the functional capacity of the heart permitting the subject to survive early life, there is no reason to consider the prognosis unfavourable, barring an unlooked-for bacterial endocarditis.

References

Aitken, J. K. (1932). *Lancet*, 2, 24.
Campbell, M., and Suzman, S. S. (1934). *Amer. Heart J.*, 9, 304.
Lampard, M. E. (1928). *Arch. Dis. Childh.*, 3, 212.
Leech, C. B. (1930). *Amer. J. Dis. Child.*, 39, 131.
Moll, F. P. (1912). *Amer. J. Anat.*, 13, 249.
Tandler, J. *Anatomie des Herzens, Jena*, Gustav Fischer, 1913, p. 313.
Yater, W. M. (1939). *Amer. J. Dis. Child.*, 38, 112.
Yater, W. M., Leaman, W. G., and Cornell, V. H. (1934). *J. Amer. med. Ass.*, 102, 1,660.

CONGENITAL PULMONARY STENOSIS
WITH LEFT VENTRICULAR ENLARGEMENT ASSOCIATED WITH ATRIAL SEPTAL DEFECT

BY

PAUL WOOD

From the Department of Medicine, British Postgraduate Medical School, Hammersmith Hospital, London

Received December 6, 1941

Observations on the morbid anatomy of congenital heart disease are in advance of clinical studies, and although we have been supplied by pathologists with much information about the meaning and incidence of the various single or combined developmental abnormalities of the heart, such knowledge is of practical value to the clinician only when he can recognize them during life. Certain well defined, single or combined, lesions may now be easily diagnosed at the bedside, especially with the aid of X-ray and electrocardiographic examination. It is the object of this report to present the clinical features of another congenital syndrome which, if not a freak, may prove recognizable at the bedside.

It is well known that marked pulmonary stenosis, as part of the tetralogy of Fallot or otherwise, causes enlargement of the right ventricle and deviation of the electrical axis of the heart to the right. It is also well known that patency of the interauricular septum produces progressive enlargement of the right ventricle, and right axis deviation or even right bundle branch block. It is interesting, therefore, that a combination of these two lesions may apparently result in left ventricular enlargement and left axis deviation. These effects are illustrated by the following case.

Description of Case

A girl, aged 6, was first seen by me in April, 1935. She had been cyanosed from birth, and had never been able to walk. She did not sit up until she was two, and since then had only been able to shuffle about on her buttocks. Her mental development was normal at first, for she began to talk when she was one, and spoke short sentences at one and a half. Because of her legs she had to be carried about, and it was soon noticed that if she were held upright suddenly, or if she exerted herself too strenuously, she was subject to fainting attacks, in which she turned deep blue, gasped for breath, and finally lost consciousness. Recovery occurred in about a minute, and there were no convulsions. From the age of four she also suffered from severe right-sided headaches, which caused her to scream for an hour or so, and of which she had no recollection. During the fortnight preceding admission to hospital, her speech became slurred and difficult to understand, and excessive salivation was bothersome.

Her parents were healthy, and there were six other children, alive and well.

Examination revealed a very cyanosed child with clubbing of the fingers and toes



FIG. 1.—Clubbed fingers.

(Fig. 1). She was in no distress, and there was no dyspnœa. The temperature was normal, the pulse rate 100 beats per minute, and the respiration rate 20 per minute. There was no focal or general infection.

Cardiovascular system. The heart was central in position, a diffuse cardiac impulse being felt as much to the right as to the left of the sternum. There were no thrills, but there was a loud and significant systolic bruit, heard rather better to the right than to the left of the mid-line, and of maximum intensity at the level of the second and third interchondral spaces. It seemed to be conducted into the vessels of the neck. The second heart sound at the base was sharp and clear, and could be heard equally well on either side of the sternum. The heart sounds were not remarkable elsewhere.

The rhythm was normal, the cervical veins were not engorged, the liver was impalpable, there was no œdema, and there was no evidence of pulmonary congestion. The blood pressure varied between 125/90 and 110/85. All the main arteries of the limbs were normal to palpation.

An electrocardiogram (Fig. 2) showed left axis deviation, and P waves which were split, up to 0·10–0·12 sec. in duration, prominent in lead I, and inverted in lead III.

The skiagram (Fig. 3) and radioscopy revealed marked prominence of the ascending aorta, left ventricular dominance, and displacement of the whole heart to the right.

A blood count showed 10,400,000 red cells per c.mm., hæmoglobin 108 per cent, white cells 3400, 39 per cent of which were polymorphonuclear cells.

Central nervous system. There was a combination of left hemiplegia and paraplegia: there was weakness of the left side of the face, the palate was drawn up to the right, the tongue was protruded to the left, the left arm was weak, and both legs were spastic, with exaggerated tendon jerks and bilateral extensor plantar responses. There was no sensory loss.

Apart from the cardiovascular and nervous systems there were no other abnormalities, except a palpable spleen.

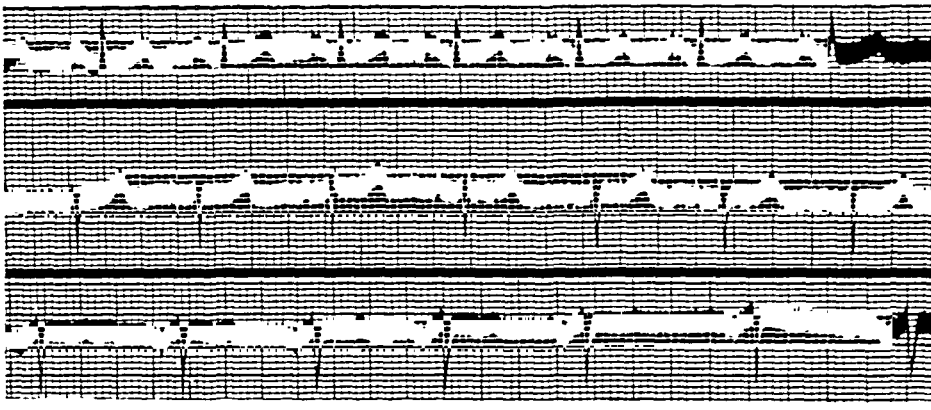

FIG. 2.—Electrocardiogram of case, showing left axis deviation.

FIG. 3.—Teleradiogram of heart: note the central position, the prominence of the ascending aorta, the shadow external to the ascending aorta (probably the superior vena cava), and the rounded, bulky left ventricle.

The diagnosis was congenital heart disease with permanent cyanosis, clubbing, and polycythæmia, but the exact lesion or combination of lesions could not be determined. For while the clinical features suggested marked pulmonary stenosis or atresia, the X-ray and cardiographic evidence left little doubt that the left side of the heart was carrying the burden.

The subsequent course threw no further light on the matter. She was observed for nearly two years, and repeated clinical, radioscopic, and cardiographic examinations merely confirmed the above findings. On one occasion

she was admitted with athetoid movements of the right arm, when her blood count was as high as 11,200,000 red cells per c.mm., and the hæmoglobin 124 per cent. At that time it was shown that the viscera were not transposed. On another occasion, night sweats, general malaise, slight fever, a palpable spleen, and a few granular casts and red cells in the urine, made me suspect superimposed bacterial endocarditis. The blood urea was 30 mg. per 100 c.c., the specific gravity of the urine varied between 1005 and 1025, and there was no albuminuria. A blood culture was not obtained.

On March 5, 1937, she was readmitted with frequent syncopal attacks associated with deepened cyanosis, and on March 29 she died in one of them. These attacks were similar to those of which she had complained for many years, and which have already been described. At this time she was eight years old.

Post-Mortem Examination

This revealed congenital pulmonary valvular stenosis, atrial septal defect, dominant hypertrophy of the left ventricle, and intense venous congestion throughout all the viscera, but especially marked in the meninges and brain.

The body was that of a well nourished female child: the weight was 36 lb.; the height, 4 ft.

The heart weighed 182 g. (normal for this age 95–105 g.). It was almost square in shape. The aorta was prominent, and the dominant chamber was the left ventricle (Fig. 4 and 5). This was dilated and considerably hypertrophied, its wall measuring 10 mm. in thickness at the apex, 16 mm. at the centre, and 18 mm. at the base. The interventricular septum bulged to the right, and was intact. The right ventricle was contracted, and its wall measured 12 mm. at the site of the moderator band, 8·5 mm. on either side of it, and 6 mm. at the base. The outflow tract of the right ventricle was elongated and narrow. The pulmonary valve (Fig. 4) consisted of two cusps, mainly fused together, leaving a narrow aperture slightly less than 5 mm. in diameter. Around the free margin of the cusps was a ring of granular, wart-like, vegetations, composed microscopically of hyaline thrombi without cellular reaction. The left auricle was considerably dilated and somewhat hypertrophied, its wall measuring 1–2 mm. in thickness. The right auricle was also enlarged, but a little less conspicuously. There was a large defect of the atrial septum, at the site of the fossa ovalis, the aperture measuring 2 cm. in diameter (Fig. 5).

The aortic, mitral, and tricuspid valves were normal. There was no coarctation of the aorta; the great vessels were normal; the coronary arteries were normal; and the ductus arteriosus was closed.

Microscopically, the muscle fibres of the left ventricle were thicker than those from any other chamber. Apart from some increased cellularity of the interstitium, and a trace of perivascular fibrosis here and there, there were no significant microscopic changes.

The other autopsy findings simply showed the effects of intense venous congestion, all the viscera being involved. The bone marrow was very hyperplastic, and microscopically this was shown to be due to normoblastic proliferation. The meninges over the whole of both hemispheres were intensely vascular and deeply congested, the vessels lying so close together as to be almost touching. The vascularity and congestion were such as to form a deep purple membrane, through which the underlying brain could not be seen. The grey matter of the brain, over practically the whole of both hemispheres, showed a fine granularity, and one section was deeply congested. On the posterior lateral aspect of the left occipital lobe there was an

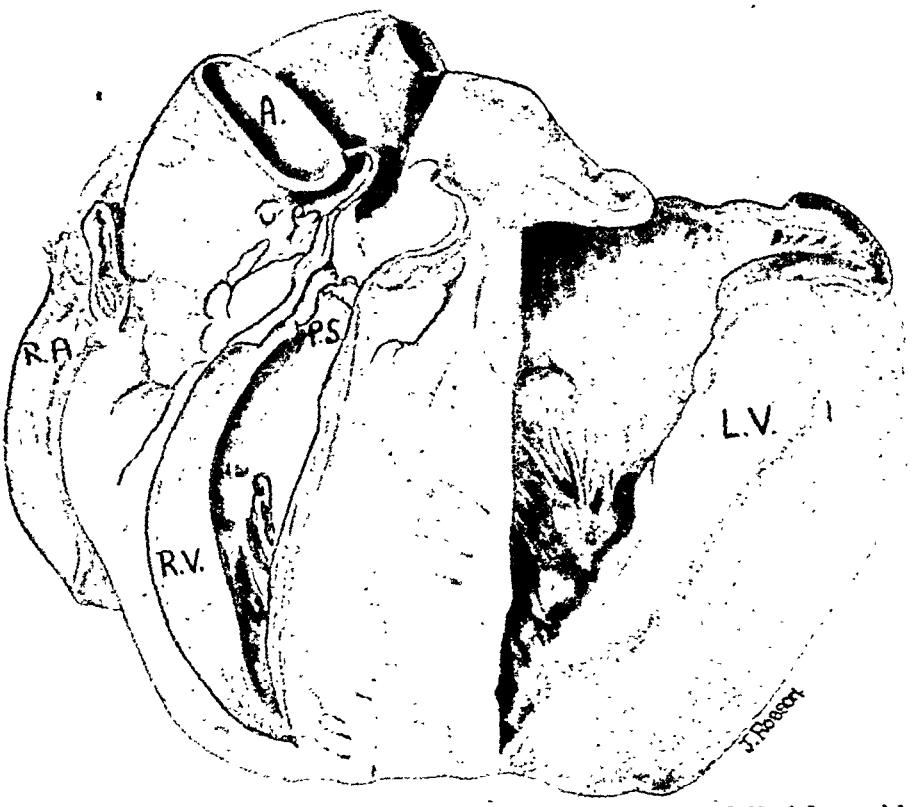

FIG. 4.—Drawing of the heart (to scale) from the front: A., aorta; L.V., left ventricle; P.S., pulmonary stenosis; R.V., right ventricle; R.A., right auricle.

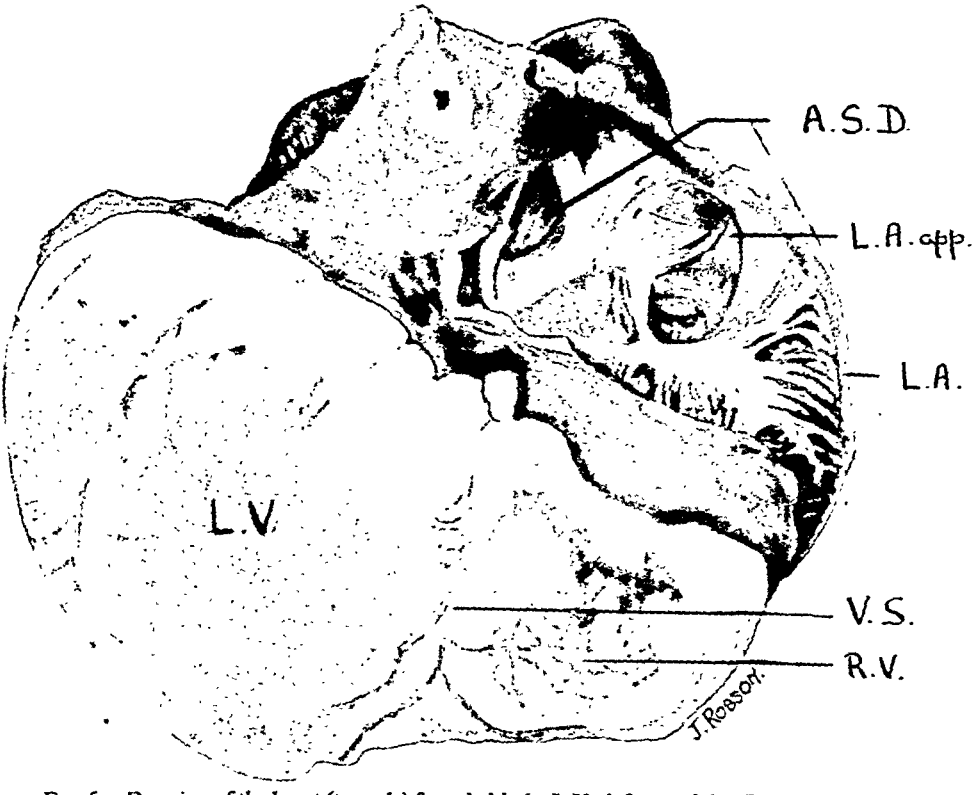

FIG. 5.—Drawing of the heart (to scale) from behind: L.V., left ventricle; R.V., right ventricle; L.A., left auricle; L.A. app., left auricular appendage; A.S.D., atrial septal defect at site of fossa ovalis.

area of softening, limited to the grey matter, which in this area was practically absent, being represented by a little semi-fluid matter. The pons, medulla, and cerebellum were less affected than the rest of the brain. The white matter appeared normal throughout.

Dr. Greenfield kindly examined the sections of the brain and meninges, and concluded that all the changes could be attributed to intense congestion. Some of the nerve cells were indistinct and shrunken. The nuclear chromatin had lost its normal pattern, and stained darkly and diffusely. The nucleolus was not, as a rule, visible. In some areas there was complete disappearance of all nerve cells. There was no apparent gliosis or other change. In the occipital lobe, the softened area previously described, consisted of collapsed neuroglial reticulum devoid of nerve cells.

Discussion

It is clear that this was a case of pulmonary valvular stenosis complicated by wide patency of the interauricular septum, there being no other abnormalities. Uncomplicated atrial septal defect is held to be responsible for the gross enlargement of the chambers on the right side of the heart which is associated with it (Bedford, Papp, and Parkinson, 1941). In these cases it is believed that there is a considerable shunt of blood from the left to the right auricle, there being reason to think that the pressure in the left auricle is normally higher than that in the right—for consider the mechanism of closure of the foramen ovale, and the behaviour of paradoxical emboli. The extra work thus given to the right side of the heart is the simplest explanation of the great enlargement found. The sudden development of extreme cyanosis when the right ventricle begins to fail is readily understood on the supposition that the rising pressure in the right auricle effects a reversal of flow through the atrial septal defect. In the case recorded here, extreme cyanosis was lifelong, and the left side of the heart was most enlarged, facts which indicate that the shunt was perpetually from right to left. It follows that the pressure in the right auricle must have been higher than that in the left. It is not obvious why this should have been so, for right ventricular failure was not clinically apparent. Had tricuspid stenosis been present as a congenital defect the case would have presented no difficulties, but the tricuspid valve was normal. One is driven to the conclusion that the pulmonary stenosis was responsible for the raised pressure in the right auricle.

Summary

A case is described which presented the following features:
(1) pulmonary valvular stenosis, (2) atrial septal defect, (3) left ventricular dominance, and (4) extreme permanent cyanosis.

The question arises whether this will prove a clinically recognizable congenital syndrome, or whether this is a freak case.

My thanks are due to the chief medical officer of the London County Council for his permission to publish this case; and I wish to express my appreciation and gratitude to Mr. J. Robson for his careful drawings of the heart.

Reference

D. E. Bedford, C. Papp, and J. Parkinson. *Brit. Heart J.* (1941), 3, 37.

INFARCTION OF THE CARDIAC AURICLES (ATRIA): CLINICAL, PATHOLOGICAL, AND EXPERIMENTAL STUDIES

BY

E. H. CUSHING, H. S. FEIL, E. J. STANTON, AND W. B. WARTMAN

From the Departments of Medicine and Surgery and the Institute of Pathology of Western Reserve University and the University Hospitals of Cleveland, U.S.A.

Received December 8, 1941

Infarction of the auricles * (atria) of the heart is generally considered a rare lesion of little clinical importance and few cases are reported. However, a study of the records at the University Hospitals of Cleveland showed that the auricles were involved in 31 (17·0 per cent) of 182 cases of myocardial infarction that were proven at autopsy during the seven year period from 1934 to 1940. This is the highest incidence of auricular infarction in any reported series, but is thought to be near the true incidence of the lesion, because during the period of investigation the auricles were specifically examined for infarcts.

In a previous publication (Feil, Cushing, and Hardesty, 1938) two cases of infarction of the right auricle were encountered in a pathological study of 34 cases of acute myocardial infarction. Bean (1938) reported a series of 300 cases of myocardial infarction in which two instances of auricular infarcts were encountered at autopsy. Auricular fibrillation was present in one of these cases. Clowe, Kellert, and Gorham (1934) described a verified case of rupture of the right auricle. They analysed 54 proved cases that had been reported and found that the rupture had occurred in the right auricle in 70 per cent of them. Laignal-Lavastine, Liber, and Bidou (1934) found a ruptured hæmorrhagic infarct in the right auricle, following thrombosis of the first portion of the right coronary artery and its auricular branches. Clerc and Levy (1925) studied a patient with mitral stenosis and infarction of the external and superior portions of the right auricle. The electrocardiogram showed what they termed " fibrillo-flutter." Lisa and Ring (1931) described rupture of the left auricle in a heart in which there was advanced coronary arteriosclerosis and a recent thrombus in the anterior descending branch of the left coronary artery. Daven-

* In the anatomical and pathological portions of this paper, starting with the section headed *Pathological Observations* on p. 20, a distinction is made between the words " atrium " and " auricle " in accordance with the B.N.A. terminology. Atrium is defined as the entire chamber, either left or right, at the base of the heart above the ventricle. The word " auricle " is reserved for the ear-like appendage of the atrium. In the discussion of the physiological and clinical aspects of the lesion, deference is made to long and common usage so that when the adjective " auricular " is employed it refers to the entire chamber and not to the appendage. Thus such terms as " auricular fibrillation," " auricular flutter " and " auricular mechanism " do not imply localization to the appendage.

port (1928) reported 92 cases of proved cardiac rupture in which the right auricle was affected in 3 per cent and the left in 1 per cent. Krumbhaar and Crowell (1925) studied 22 cases of rupture of the heart and reviewed 632 reported cases. The right auricle was involved in 5 per cent and the left in 2 per cent, and infarction was mentioned as a frequent cause. Infarction of the auricular musculature was seen three times in von Glahn's (1936) pathological material.

Recently Langendorf (1939) studied a case of auricular infarction, which was verified by autopsy, and reported deviations from the isoelectric line of the P–Q segment in the second and third leads of the electrocardiogram. In experimental injury of the atria, changes have been described in the P wave and in the P–Q level by Hahn and Langendorf (1939). Abramson, Fenichel, and Strookhoff (1938) reported elevation of the P–Q interval (lead I) in dogs, following necrosis of the left atrium experimentally produced, and depression of the interval after necrosis developed in the right atrium. They suggested that the deviation of the P–Q interval in man is due to necrosis of the auricle and is analogous to the deviation of the S–T interval which occurs in ventricular ischaemia. In experiments in which the atrial arteries of rabbits were clamped, Lambert (1937) found changes in the auricular complex of the electrocardiogram. The most interesting phenomena were the depression of the P–Q segment, which he termed " cupule," and occasionally a diphasic or inverted P wave. Conderelli (1929), on the other hand, was unable to produce electrocardiographic changes after temporary occlusion of the right atrial vessels. Sanders (1939) injected 95 per cent alcohol into the atria of dogs and found that nodal rhythm, wandering pacemaker, auricular extrasystoles, and paroxysmal auricular tachycardia developed when the necrosis involved the sinus node. Elevation of the auricular S–T segment in lead I with an upward bowing and an auricular Q wave frequently followed injection of the left auricle. Necrosis of the right auricle caused similar auricular S–T changes in leads II and III. Changes in the P wave consisted of broadening and inversion, diminution or increase in amplitude, and slurring and notching. Sometimes a Q or S wave was seen, or M or W complexes.

The present study was undertaken to determine: (1) the clinical and electrocardiographic criteria that are diagnostic of auricular (atrial) infarction; (2) the incidence of auricular involvement in autopsied cases of myocardial infarction; and (3) the electrocardiographic changes in experimental auricular (atrial) infarction.

Clinical Observations in Human Auricular Infarction

Thirty-one cases of auricular (atrial) infarction were found in 182 cases of myocardial infarction (17 per cent), culled from 2704 consecutive autopsies. Electrocardiograms were taken in 23 cases and the findings are given in Table I. Abnormal auricular mechanism was present in 17 of the 23 cases (74 per cent). On the other hand, in 91 verified cases of ventricular infarction without demonstrable auricular infarction, in which electrocardiograms had been taken,

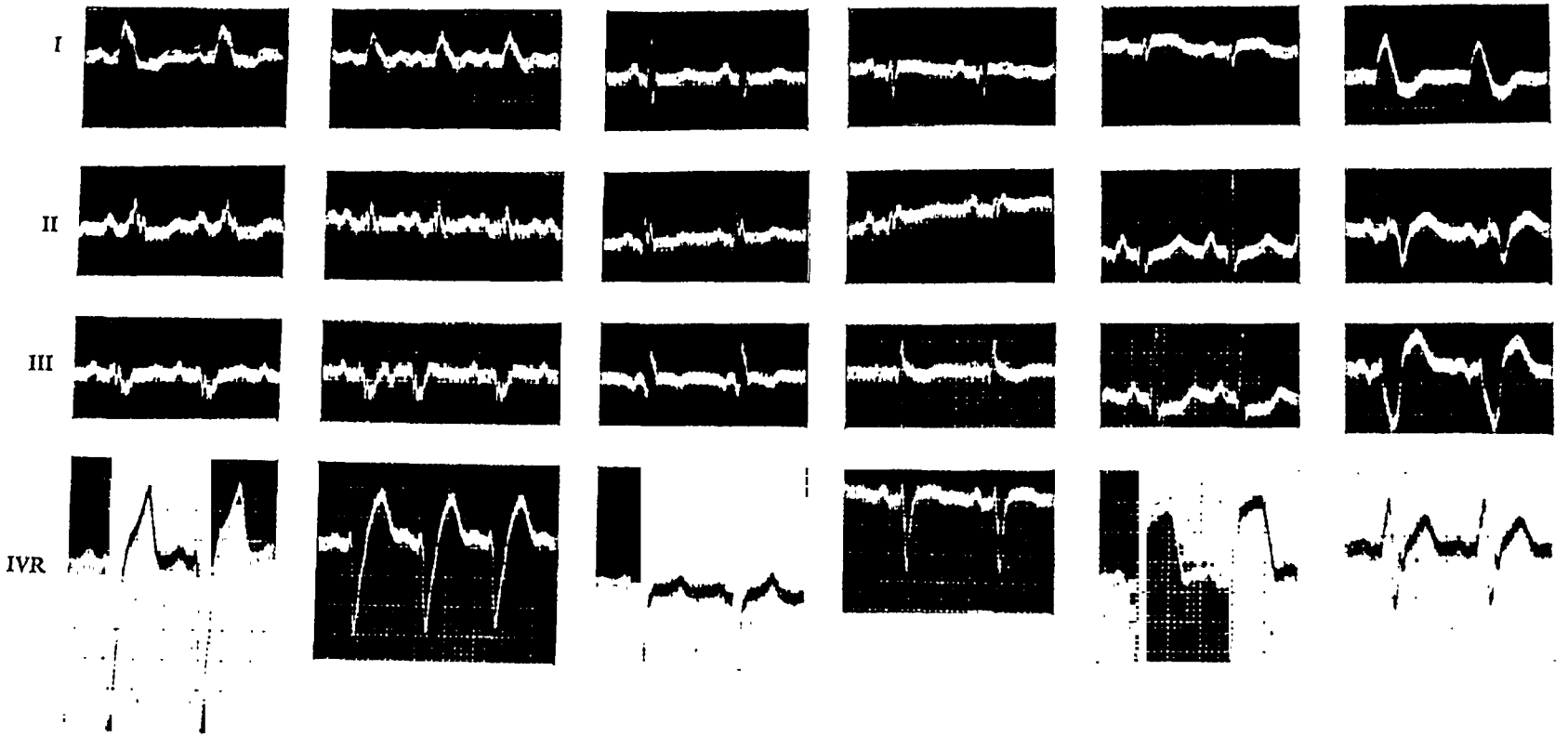

Case 12. Case 29. Case 25. Case 31.

FIG. 1.—(A) Case 12. 20–4–38. Before infarction: left bundle branch block. (B) Case 12. 25–7–39. After infarction: depression of P–Q in leads II and III and bundle branch block.
(C) Case 29. 11–8–37. Before infarction. (D) Case 29. 7–10–37. After infarction: depression of P–Q in leads I, II, and IVR, and RS–T changes in IVR, typical of anterior and apical infarction.
(E) Case 25. After infarction: depression of P–Q; QRS–T changes typical of anterior and apical infarction.
(F) Case 31. After infarction: depression of P–Q in leads II and III and left bundle branch block.

there was evidence of disturbed auricular rhythm in only 8 cases (8 per cent). In the patients with infarcts of the auricles, auricular fibrillation was observed in 9 cases, auricular premature beats in 4, auricular flutter in 2, and sinus arrest and wandering pacemaker in 1 case each. The depression of the P–Q level (Fig. 1) described by Lambert and Langendorf occurred in 5 instances (22 per cent), but the value of this sign is doubtful because of its occurrence in normal people (Shipley and Hallaran, 1936). In the two cases with infarction of the sinus node, sinus arrest was present in one and auricular fibrillation in the other.

Pathological Observations in Human Atrial Infarction

A summary of the pathological observations in the cases of atrial * infarction is given in Table I. Before discussing these findings, it should be emphasized that many cases will be overlooked at autopsy, unless the existence of the lesion is kept constantly in mind. The gross recognition of atrial infarcts may be difficult and in questionable cases many blocks must be taken for microscopic examination. In this study, routine blocks were taken from the region of the sinus node, from both auricles, and from the lateral wall. Whenever mural thrombi were found in the atria, a suspicion of infarction was at once entertained and appropriate blocks were taken through such areas.

Fig. 2 (on p. 25) shows the location of the infarcts in the atria. The great majority of them were in the right atrium (27 times) in contrast to the occasional involvement of the left atrium (5 times). Most of the infarcts occurred in the auricles while the region of the sinus node was affected in only two instances. Multiple infarcts were found in two hearts.

Although the atrial arteries were carefully inspected after fixation by means of closely placed transections, gross occlusion was demonstrated in only one case. No doubt obstruction would have been found more frequently, had the coronary arteries been injected.

On the other hand, the anterior descending and circumflex branches of the left coronary artery, as well as the main right coronary artery were often diseased and serious stenosis or occlusion was encountered in 23 of the 31 cases. Either recent or remote infarcts of the ventricular myocardium were present in 22 of the cases. These were all in the left ventricle and interventricular septum, and often were multiple. Two other cases showed acute diffuse myocarditis and one chronic myocarditis. This left 6 hearts (*Cases* 3, 16, 17, 21, 26, and 28) in which auricular infarcts were the only lesions other than hypertrophy. With the exception of *Case* 26 all the infarcts were recent. Electrocardiograms had been taken in 4 of the 6 patients (*Cases* 3, 16, 21, and 26) and 2 had auricular fibrillation, 1 auricular flutter, and 1 low voltage of QRS. *Case* 3 died of heart failure; *Case* 16 suffered from malignant hypertension and died of uræmia; *Case* 17 had hypertension with cardiac decompensation, as well as acute pyelonephritis, and died of broncho-pneumonia; *Cases* 26 and 28 had hypertension and died of cardiac failure. It is, of course, unlikely that the auricular infarcts

* See footnote on p. 17.

ABBREVIATIONS USED IN TABLE I

A.F.	=	Auricular fibrillation	L.C.	=	Circumflex ramus left coronary artery
A.Fl.	=	Auricular flutter	L.D.	=	Descending ramus left coronary artery
ant.	=	Anterior	N	=	Normal findings
A.P.B.	=	Auricular premature beat	post.	=	Posterior
Art.	=	Arteriosclerosis	R.A.	=	Right auricle (atrium)
dep.	=	Depressed	R.A.A.	=	Right auricular appendage (auricle)
I.V.S.	=	Interventricular septum	R.S.R.	=	Regular sinus rhythm
L.A.	=	Left auricle (atrium)	R.V.	=	Right ventricle
L.A.A.	=	Left auricular appendage (auricle)	Sten.	=	Stenosis
lat.	=	Lateral	Vent. Tachy.	=	Ventricular tachycardia
L.B.B.B.	=	Left bundle branch block			

TABLE I

SUMMARY OF CLINICAL AND PATHOLOGICAL FINDINGS IN HUMAN INFARCTION OF THE CARDIAC ATRIA

Case No.	Age in Years	Sex	Colour	Electrocardiogram	Heart Weight in Grams	Location and Age of Atrial Infarct	Mural Thrombi in Atria	Lesions in Main Coronary Arteries	Location and Age of Ventricular Infarcts
1	80	F	W	N	520	L.A., post; recent	N	L.D.; remote L.C.; remote R.C.; recent Art. +++Sten.	L.V., post basal; remote. Acute myocarditis
2	54	F	W	A.F.	400	R.A.A.; recent	R.A.A.; recent L.A.A.; recent	Art. ++	L.V. and I.V.S., ant. and apical; remote
3	63	F	W	A.F.; remote ant. infarct.	450	R.A.A.; recent	R.A.A.; recent	Art. +++Sten.	N
4	74	M	W	A.F.; remote ant. infarct.	640	R.A.A.; recent and remote	R.A.A.; recent L.A.A.; remote	L.D.; recent and remote L.C.; remote R.C.; remote in A. branch Art. +++	L.V. and I.V.S.: 1. recent and remote at apex 2. recent post. and basal

TABLE I—*continued*

Case No.	Age in Years	Sex	Colour	Electrocardiogram	Heart Weight in Grams	Location and Age of Atrial Infarct	Mural Thrombi in Atria	Lesions in Main Coronary Arteries	Location and Age of Ventricular Infarcts
5	70	M	W	A.F.; recent post. infarct.	700	R.A.A. and R.A., post.; recent	R.A.; recent	L.C.; recent R.C.; recent Art. +++Sten.	L.V., lat. and post. basal I.V.S., post. R.V., ant. at apex; all recent
6	52	M	W	N	570	R.A.A.; recent	R.A.A.; recent	Art. +	L.V.; acute myocarditis
7	45	M	B	A.F.	650	R.A.A.; recent and remote	R.A.A.; recent	Art. +	L.V., apex; recent
8	64	M	W	A.F.	560	R.A., lat.; recent	R.A., lat.; recent	Art. +++Sten.	L.V., ant. basal; recent L.V., ant. apical; remote
9	69	F	W	R.S.R., sinus arrest; recent ant. infarct.	480	R.A., post.; near sinus node	N	Art. +++Sten.	L.V. and I.V.S., apex; recent
10	86	M	B	N	550	R.A.A.; recent	R.A.A.; recent	Art. ++	Acute myocarditis
11	55	M	W	A.P.B. R.S.R.; recent post. infarct.	800	R.A.A.; remote	N	L.D.; remote R.C.; recent Art. +++Sten.	L.V., apex.; remote L.V., post.; recent R.V., post.; recent I.V.S., post.; recent
12	59	M	W	A.P.B. R.S.R. L.B.B.B; $P\text{-}Q_{2,3}$ dep	600	R.A.A.; recent and remote	R.A.A.; recent	Art. +	Chronic myocarditis Healed mural endocarditis

13	64	M	W	N	260	R A A.; recent	R.A.A.; recent	R.C.; recent Art. +++Sten.	L.V., apex; recent and remote L.V. and R.V., post. basal; remote
14	58	F	W	A.F.	580	L.A.A.; remote	R.A.A.; recent L.A.A.; recent	Art. +	L.V., lat. and basal; remote
15	57	M	W	A.P.B.; low voltage QRS; remote ant. infarct.	630	L.A.A.; remote	N	L.D.; remote Art. +++Sten.	L.V., R.V., and I.V.S., apex; remote
16	45	F	B	A. Fl.	690	R.A.A.; recent and remote	R.A.A.; recent	Art. +++	N
17	77	M	W	N	790	R.A.A.; recent	R.A.A.; recent	Art. +	N
18	49	M	W	A.F.; T_1 neg.	640	R.A., lat.; recent and remote	R.A.; recent	L.D.; remote Art. +++Sten.	L.V. and I.V.S., apex; remote
19	50	M	W	N	350	R.A.A.; remote	N	L.D.; remote Art. ++Sten.	L.V., apex; remote
20	38	M	B	R.S.R.; P–Q_4 dep.	650	R.A.A.; recent and remote	R.A.A.; remote	L.C.; recent Art. +++Sten.	L.V., post. basal; recent
21	35	F	B	R.S.R.; low voltage QRS	200	R.A.A.; remote	N	Art. ++Sten.	N
22	58	M	W	A.P.B. R.S.R.; remote ant. and post. infarct.	520	R.A.A.; recent	R.A.A.; recent	L.D.; recent Art. +++Sten.	L.V., lat.; recent L.V., post. basal; remote
23	76	M	W	R.S.R.	470	R.A., post.; remote	N	L.D.; recent and remote	L.V., post. basal; recent and remote

TABLE I—*continued*

Case No.	Age in Years	Sex	Colour	Electrocardiogram	Heart Weight in Grams	Location and Age of Atrial Infarct	Mural Thrombi in Atria	Lesions in Main Coronary Arteries	Location and Age of Ventricular Infarcts
24	74	M	W	N	650	R.A.A.; remote	R.A.A.; recent	R.C.; remote Art. +++Sten.	L.V., apex; remote
25	55	M	W	R.S.R.; P–Q_4 dep.	580	R.A.A.; recent	R.A.A.; recent	L.D.; recent Art. +++Sten.	L.V. and I.V.S., apex; recent
26	47	M	W	A.F.; remote ant. infarct.	600	R.A.A.; remote R.A. and L.A.; acute and chronic myocarditis and endocarditis.	R.A.A.andL.A.A.; recent	L.C.; remote Art. ++	N
27	56	M	W	A.F., vent. tachy.; recent post. infarct.	350	L.A.A.; remote Multiple small infarcts	L.A.A.; recent	L.C.; recent R.C.; recent and remote	L.V. and I.V.S., lat. and post.; recent
28	60	M	W	N	500	R.A.A.; recent	R.A.A.; recent	N	N
29	50	M	W	R.S.R., wandering pacemaker; P–Q_1 dep. recent ant. infarct.	650	R.A.A.; recent and remote	R.A.A.; recent	L.D.; recent L.C.; recent Art. +++	L.V. and I.V.S., apex, lat. and post.; recent
30	57	M	W	N	450	R.A., lat.; remote L.A., lat.; remote	R.A.A.; remote	R.C.; remote Art. +++Sten.	L.V. and I.V.S., apex; remote
31	67	F	W	R.S.R. L.B.B.B.; P–$Q_{2,3}$ dep.	520	R.A.A. and R.A., lat.	R.A.A.; recent	Art. +++Sten.	L.V., post. lat.; recent

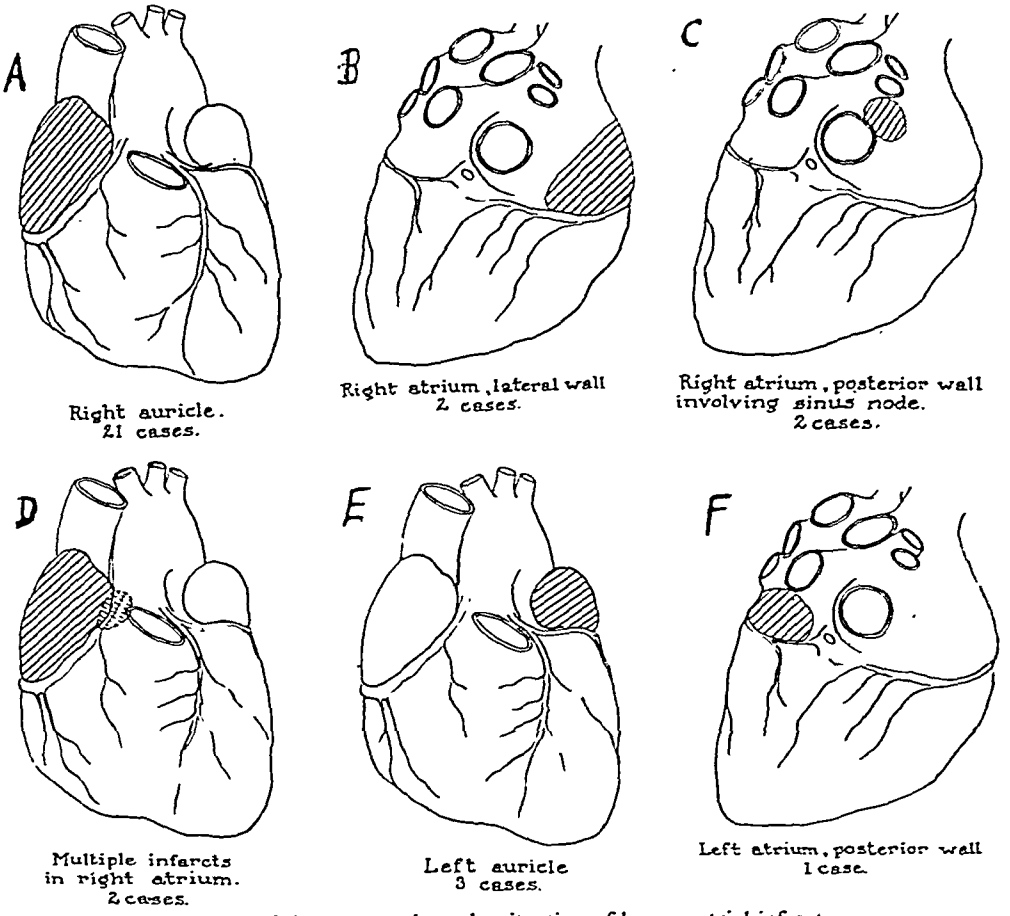

FIG. 2.—Diagrams to show the situation of human atrial infarcts.

(A) Right auricle, 21 cases. (B) Right atrium, lateral wall, 2 cases. (C) Right atrium, posterior wall involving sinus node, 2 cases. (D) Multiple infarcts in right atrium, 2 cases. (E) Left auricle, 3 cases. (F) Left atrium, posterior wall, 1 case.

caused the death of these patients, but it is conceivable that they were a contributory factor.

The gross appearance of atrial infarcts was similar to that commonly seen in the ventricles (Fig. 3). It is worthy of note that in 26 cases, mural thrombi were found tightly adherent to the endocardium over the infarcted area.

Microscopically all stages of infarction were observed. The earliest changes consisted of hyperæmia and hæmorrhage with swelling of the muscle fibres and necrosis and exudation of leucocytes, followed later by hæmosiderin pigmentation and scarring. Often the muscle bundles in adjacent areas were swollen with vacuolated cytoplasm and large pleomorphic and hyperchromatic nuclei. In most cases the infarcts were massive, but occasionally small multiple lesions, separated from each other by intact myocardium, were observed. Massive infarction was usually accompanied by mural thrombosis of the endocardium, and when organization had occurred it was difficult to distinguish

FIG. 3.—Atrial infarcts in dogs.

(A) Recent infarction in right auricle following experimental ligation of the main right coronary artery. A large infarct of the right ventricle was also present.

(B) Naturally occurring infarct in right auricle of a dog. No ventricular infarction. The localization of these lesions in the auricles, the dusky purple discoloration, and the presence of mural thrombi are also characteristic of the human lesions.

between necrotic myocardium and the thrombus. In such cases the Weigert stain was helpful, for by demonstrating the elastic lamina of the endocardium, the line of demarcation between muscle and thrombus could be clearly seen. When the infarct was not accompanied by mural thrombosis, there was nearly always a narrow border of surviving myocardium immediately beneath the endocardium. Microscopic study revealed small thrombotic arteries in several instances.

DISTRIBUTION OF THE CORONARY ARTERIES OF THE ATRIA IN DOGS AND IN MAN

In this study of human atrial infarction the electrocardiographic changes described by Lambert and by Langendorf were not seen frequently. In view of this discrepancy, infarction of the atria of the heart was produced experimentally in dogs. Before describing the findings, it is necessary to review the distribution of the coronary arteries of the atria in dogs since it is different from that in man.

The atrial vessels of the dog's heart (Fig. 4) have a fairly constant distribution (Meek, Keenan, and Theisen, 1928–29). One or two vessels arise from the right coronary artery, shortly after its origin, and supply the surface of the right auricle and the superior vena cava. The lateral branch supplies the posterior

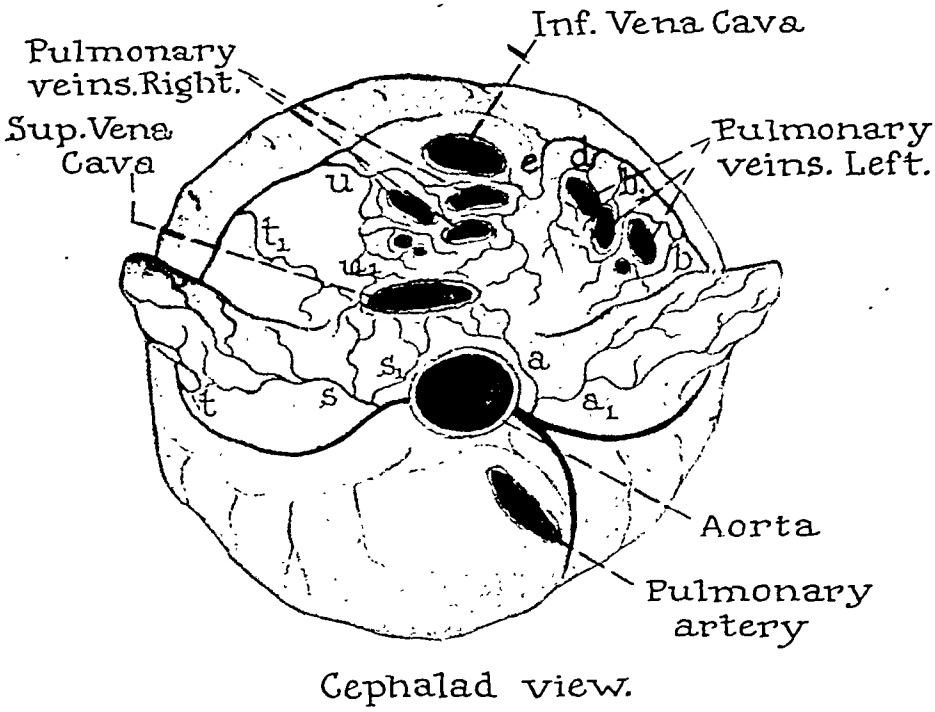

FIG. 4.—Distribution of the atrial branches of the coronary arteries in the dog.

a	Left anterior	s	Right anterior
a_1	Left anterior accessory	s_1	Right anterior accessory
b	Left intermediate	t	Right intermediate
b_1	Left intermediate accessory	t_1	Right intermediate accessory
d	Left anterior pulmonary branches	u	Right posterior
e	Left posterior	u_1	Sulcus artery

aspect of the right atrium, and there is a constant posterior branch that supplies the tissue about the pulmonary veins and anastomoses with the anterior branch about the superior vena cava. From the left coronary artery two branches arise close to the origin, one supplying the auricle and the other going upwards about the aorta to the vena cava. Posteriorly on the left side there is a lateral branch which ramifies about the pulmonary veins and goes upward toward the superior vena cava.

In man there are usually two branches from the right coronary artery (Gross, 1921). The first arises near its origin and comes behind the aorta, 5 mm. above the auriculo-aortic groove. It supplies the anterior wall of the right atrium and sends branches to the auricle. It then passes through the septum to reach the posterior wall, where it surrounds in ring fashion the superior vena cava. This branch may arise from the left coronary artery near its origin; it encircles the base of the left auricle, ascending the external surface of the left atrium to the region of the superior vena cava, where it terminates as an arborization about the superior vena cava or passes immediately after its origin along the anterior wall of the left atrium to within 5 mm. of the auriculo-aortic groove. On reaching the inter-atrial septum, it

turns up and crosses on the superior aspect of the right atrium between the superior vena cava and the right auricle. The left coronary artery shows, in addition to the above branches, one or two smaller atrial branches, which distribute themselves over the anterior and superior surfaces of the left atrium. Occasionally, a left lateral atrial branch extends around the posterior surface of the atrium to reach the opening of the superior vena cava. The second branch of the right coronary artery is less constant and supplies the aortic face of the right auricle and the superior surface of the right atrium. There are a few small and inconstant atrial vessels from both sides.

Experimental Infarction of the Atria

All experiments were performed under aseptic conditions upon medium-sized dogs, anæsthetized with ether which was administered by intermittent positive pressure insufflation. Pre-operative medication consisted of morphine sulphate, 0·01 g., given hypodermically one hour before the experiment.

The heart was exposed and supported in a cradle constructed by suturing the widely opened pericardium to the chest wall. Dissection of the right or the left circumflex coronary artery was begun at its origin and continued distally, each atrial branch being exposed, temporarily occluded several times, doubly ligated with fine silk, and finally cut.

Electrocardiograms were taken, employing the standard three leads and the chest lead IVR as follows: (1) a normal control before the start of the experiment; (2) one hour after the administration of morphine; (3) after ether anæsthesia; (4) after opening the chest; (5) after opening the pericardium; (6) after construction of the pericardial cradle; (7) before and after each temporary occlusion of the individual atrial arteries; (8) before and after permanent ligation and section of each atrial artery; (9) at the conclusion of the experiment; and (10) daily thereafter. Chest leads were not taken after opening the thorax.

One or more atrial arteries were ligated in 18 dogs. Multiple operations at 12 to 21 day intervals on the same dog were performed and all right atrial branches were ligated in 11, all left atrial branches in 7, and the arteries of both atria in 4 instances.

In four dogs the effect of chemically produced necrosis of the atrial myocardium was studied. In one animal various portions of the right atrium were painted with liquid phenol, and in three dogs the actual cautery was applied successively to the right and left atrium.

After sacrifice the hearts were injected through the right and left coronary arteries with barium sulphate gelatin after the method of Louis Gross (1921), chilled, X-rayed, and placed in 10 per cent formalin. Gross and microscopic examination of the hearts was made following the usual routine.

Ligation of Right Atrial Arteries

Dog 38-10. Artery s_1 ligated. Immediately afterwards P_2 and P_3 showed increased amplitude and returned to normal two hours later. There were no P-Q changes.

Daily electrocardiograms for twenty-two days showed no abnormality. Twenty-three days later, arteries t and t_1 were ligated. After operation P_2 was slightly increased without P–Q changes, and one day later the record was entirely normal. Twenty-one days later the animal was sacrificed and an organizing infarct of the right auricle and the atrium, as far as the acute margin of the heart, was found.

Dog 38–12. Arteries s_1 and s ligated. The electrocardiogram showed slight elevation of P_2 and P_3 which persisted for twenty-four hours. Nineteen days later, pathological studies showed a small organizing infarct of the right auricle.

Dog 38–13. Artery s_1 ligated. No electrocardiographic change. Twenty-one days later, artery t_1 was ligated. The electrocardiogram remained normal.

Dog 38–14. Artery s_1 ligated. No electrocardiographic change.

Dog 39–273. Artery t (small vessel) ligated. Wandering pacemaker developed and persisted about fifteen minutes. Following this, artery u was ligated and the electrocardiogram showed slight changes in contour of P_1. Artery t_1 was ligated with no further change in the electrocardiogram. Artery s was then ligated and auricular tachycardia developed. P_2 and P_3 were broad and notched with increased amplitude. Forty-eight hours later the electrocardiogram was normal. After sacrifice the injected specimen showed that all right branches had been successfully ligated. Injection of the left coronary artery showed the barium to pass from the left atrial branches and fill the right atrial arteries. There was a recent infarct of the right auricle.

Dog 39–278. All right atrial arteries were ligated; following this slight but definite depression of P–Q developed, and disappeared within twenty-four hours. Fifteen days later the dog was sacrificed, and injection showed that all arteries to the right atrium had been ligated. Excellent interatrial anastomoses with the left atrial artery were present. Microscopic studies showed infarction of the right auricle with beginning organization.

Dog 39–280. All right atrial arteries were ligated successively and nodal rhythm resulted. The dog died twelve hours after the experiment. Injection of the coronary arteries showed that all branches to the right atrium were successfully ligated. Microscopic sections were not obtained.

Dog 39–282. All right atrial arteries were ligated. The electrocardiogram remained normal throughout. Injection of the coronary arteries with barium showed all right atrial arteries to have been ligated. Microscopic studies showed a recent infarct of the right auricle.

Ligation of Left Atrial Arteries

Dog 39–258. Artery a ligated and cut. No electrocardiographic change. The dog died of ventricular fibrillation during the experiment. Death was attributed to insufficient lung inflation.

Dog 39–260. Artery a ligated. P_1 became isoelectric, P_2 and P_3 were inverted, and the P–Q interval remained normal. These changes persisted throughout the experiment. Artery b_1 was then ligated without further change. On the first day after operation, nodal rhythm appeared and persisted four days. From the fifth to the ninth days, wandering pacemaker was present. On the tenth day the rhythm became normal and remained so. At autopsy, recent infarction of the lateral wall of the left atrium was present.

Dog 39–259. Arteries b_1 and b ligated. There were no electrocardiographic changes. Death occurred during the experiment as the result of pressure on the heart.

Ligation of Right and Left Atrial Arteries

The arteries of both atria were successfully ligated in four dogs. In one dog this was done in a one-stage operation and in three dogs by multiple stages.

Dog 39–280. Ligation of arteries *u* and *t* produced no electrocardiographic changes. Following ligation of arteries *s* and s_1 nodal rhythm resulted. Ligation of all left atrial arteries produced no further changes.

Dog 39–264. The first operation was performed on September 21, 1939, when artery *a* was ligated, after which P_1, P_2, and P_3 became isoelectric and triphasic with wandering pacemaker. Artery *b* was then tied without significant change. After operation, wandering pacemaker and slight variation in size and shape of P_1, P_2, and P_3 were present.

On October 2, artery *u* was ligated without change in the electrocardiogram. A small artery proximal to *u* was ligated and slight variation in contour of the P wave appeared. Ligation of artery *t* produced no further change. After artery *s* was ligated, P_3 became diphasic with slight terminal depression. Ligation of artery s_1 produced no further change. After closure, 1:1 flutter developed (rate 279). On the first day after operation the rate was 220 with premature auricular beats. On the second and third days the rate was 226 and 284 respectively. On the fourth and fifth days A-V block, nodal extrasystoles, slight P–Q depression, and prolonged P–R interval (0·17) were present. On the following three days auricular flutter was present (auricular rate, 374; ventricular rate, 192). On the tenth day the rhythm was normal and remained so. At autopsy there were organizing infarcts in the lateral walls and auricles of both atria.

Dog 39–276. At the first operation on September 27, 1939, artery *s* was ligated and the electrocardiogram remained normal. All remaining atrial arteries were then successively ligated without electrocardiographic change.

At the second operation on October 3, arteries *a*, *b*, and b_1 were ligated. No electrocardiographic change occurred either during the experiment or after the operation. Twenty days later the animal was sacrificed and all the left and right atrial arteries were found to have been ligated. There were organizing infarcts in the right and left auricles.

Dog 39–267. The first operation was performed on September 25, 1939, and arteries *t* and *u* were ligated. The $P–Q_2$ showed a depression of 1 mm., which continued for one day.

The second operation was performed on October 9 at which time arteries *a*, *b*, and b_1 were ligated. Only slight transient changes occurred in the contour of the P wave, and these did not persist after the operation.

The third operation was performed on October 17 when arteries *s* and s_1 were ligated. This was followed immediately by a low amplitude P wave which, however, returned to normal immediately after operation. On October 19 wandering pacemaker developed and disappeared within 24 hours, only to reappear on October 25.

Post-mortem organizing infarcts involving the lateral walls and auricles of both atria were found.

All the hearts were carefully examined for other evidence of disease, but none was found. No enlargement occurred. The main coronary arteries were widely patent and followed a normal distribution. No infarcts were found in either right or left ventricles or the interventricular septum and there was no myocarditis, endocarditis, or valvulitis. Numerous dense adhesions often containing foci of heterotopic bone were present in the atrio-ventricular sulcus at the operative site.

In all the experiments described so far, the main right and left coronary arteries were normal, which, of course, was very different from the human cases where the main coronary arteries were usually seriously diseased and showed marked stenosis. The human lesions were usually massive, were accompanied by mural thrombosis, and involved the endocardium. In the dogs, on

the other hand, no mural thrombi were formed, the infarcts consisted of small multiple scars or foci of fresh necrosis separated by bands of healthy muscle, and there was always a narrow zone of healthy myocardium immediately beneath the endocardium. Because of these differences between the experiments in the dog and the spontaneous human lesions, ligation of the main right coronary artery close to its origin was carried out in three dogs.

Dog 41–290. Shortly after ligation, S–T_1 became depressed and this was followed by ventricular tachycardia. The rate was 422 per minute. This terminated in ventricular fibrillation and death, within a few minutes. The heart was not examined.

Dog 41–291. Three hours after operation, P_3 became higher and notched, and upper nodal rhythm developed. There was, in addition, slight depression of R–T_2 and R–T_3. Six days later upper nodal rhythm was noted. Thirteen days after operation regular sinus rhythm was present, and was noted again on the twenty-seventh day. On this later date the P–R interval was shortened (0·07 sec.).

The animal was sacrificed on the thirtieth day and organizing infarcts were found in the right auricle and almost the entire right ventricle. The epicardium over these areas was thick, opaque, and pale grey, and there were numerous dense fibrous adhesions to the pericardium. The auricle was filled with a dark-red mural thrombus which on section showed well-developed organization.

Dog 41–305. Twenty-four hours after operation, upper nodal rhythm was observed with transient left bundle branch block. On the tenth day after operation sino-auricular block was present and four days later the cardiac mechanism was normal.

The animal was sacrificed on the fifteenth day. There was recent infarction of the right auricle, which was dark reddish-purple and covered with friable, yellowish-grey granular exudate. A moderately firm dark-red thrombus filled the auricle and was tightly adherent to the endocardium. Microscopic examination showed a recent hæmorrhagic infarct with mural thrombosis. A large recent infarct of the right ventricle was also present.

The infarcts produced in the two dogs which survived were identical with the human lesion. The auricle was involved in both cases. There was massive necrosis of myocardium and endocardium and there were organizing mural thrombi (Fig. 3).

Heat and Chemical Necrosis of the Atria

Heat cauterization of right and left atria. The inferior surface of the left auricle was cauterized and P_1 became diphasic and inverted. The superior surface of the left auricle was next cauterized and P_1 became isoelectric. After cauterizing the area below the left auricle and anterior to the pulmonary veins, P_1 remained isoelectric. The entire left atrium was then cauterized and ventricular tachycardia resulted. The right atrium was cauterized with no further changes and the experiment was terminated by ventricular fibrillation.

The lateral aspect of the right auricle was cauterized without causing any electrocardiographic changes. After cauterizing the medial aspect of the right auricle, no cardiographic change was noted. Following cauterization of the entire right auricle, auricular extrasystoles occurred. The body of the right atrium was burned and slight P–Q depression resulted. At this point bleeding occurred from the necrotic wall, so that a clamp was placed across it, following which the electrocardiogram showed A-V nodal rhythm. After cauterization

of the right atrium just above the vena cava the nodal rhythm persisted. The experiment was terminated by ventricular fibrillation and hæmorrhage from the atrium.

Phenol cauterization of right atrium. Liquified phenol was applied to the entire surface of the right atrium. The heart rate was decreased from 178 to 130 per minute. The mechanism changed from normal to upper nodal rhythm. P_2 and P_3 became diphasic, and the P–R interval shortened from 0·09 to 0·06 sec. The dog died about one hour after conclusion of the experiment.

Discussion

A summary of the electrocardiographic changes following ligation of the atrial arteries and necrosis of the atria is found in Table II. No constant electrocardiographic patterns were noted, but the most frequent abnormalities were depression of P–Q, variations in the contour of P, wandering pacemaker and A-V nodal rhythm. As a control the electrocardiograms of 38 normal

TABLE II

Summary of Electrocardiographic Findings in Experimental Atrial Infarcts in Dogs

Electrocardiographic Alteration	Frequency of Occurrence	Arteries Ligated
Transient increase in amplitude and contour of P wave	11	*s**—9 animals *a**—3 animals
Slight depression of P–Q interval ..	4	*s*—1 animal All right—1 animal Heat cautery of R.A.—1 animal
Wandering pacemaker..	4	*a*—4 animals
Transient nodal rhythm	3	*s*—1 animal *a*—1 animal Heat cautery R.A.—1 animal
Transient nodal rhythm and auricular extrasystoles	3	All right and all left—1 animal All right—1 animal Chemical necrosis of R.A.—1 animal
Transient auricular tachycardia ..	1	*s*—1 animal
Auricular flutter	1	All right—1 animal
A-V block	1	All right—1 animal
A-V nodal rhythm and transient left bundle branch block sino-auricular block	1	Right coronary artery ligated near origin
P_3 notched Wandering pacemaker $R-T_2$, $R-T_3$ slightly depressed 6 days; after the operation upper nodal rhythm	1	Right coronary artery ligated near origin

* *s*, right anterior and *a*, left anterior, coronary arteries.

dogs were studied. In nine dogs there was conspicious depression of P–Q, and there were a few instances of A-V nodal rhythm and wandering pacemaker.

The electrocardiographic findings in experimental injury of the atria were somewhat comparable to the changes in clinical infarction. It is interesting to note the absence of auricular fibrillation in experimental injury, although flutter and auricular tachycardia were each present once.

During the course of these experiments a case of naturally occurring infarction of the right auricle was observed in one of the animals in the dog colony of the Institute of Pathology (Fig. 3). This colony has been in existence for twelve years and has included one thousand animals. Eight hundred and fifty autopsies have been performed, and Dr. Harry Goldblatt, who has carefully examined the hearts, says he has never seen another case of spontaneous infarction of the atrium. This dog was being used in the course of other experiments in which blood had been injected into the media of the femoral arteries and thrombophlebitis had developed. Although the right coronary artery was carefully examined no obstruction was found. The infarct resembled the human lesions because of the presence of a large mural thrombus over the area of necrosis, because of its situation, and because there were no zones of intact myocardium.

The preponderance of infarction in the right auricle of man, which has been noted in this series as well as in reported cases, may be explained by the fact that when thrombosis occurs in the right coronary artery it is usually in the first two or three centimeters, thereby occluding the atrial branches that usually supply the auricle and A-V node, although the left anterior atrial artery may also supply the latter area.

Curiously, while thrombosis of the left coronary artery and its branches occurred in 65 per cent of the cases in this series, the greatest incidence of atrial infarction was on the right side. This suggests that there may be other factors beside arterial thrombosis that will cause atrial infarction. Thus the nutrition of the atrial musculature, which may come in part through the Thebesian vessels or through the thin syncitium of the myocardium itself, may be interfered with by a large mural thrombus in the auricle. The high oxygen content of the arterial blood of the left atrium may prevent frequent infarction on this side.

We have been especially impressed with the fact that most of the cases of human atrial infarction reported in this paper have shown abnormalities of the auricular mechanism in the electrocardiograms. There have been auricular extrasystoles, auricular fibrillation, wandering pacemaker, nodal rhythm, and in five cases depression of the P–Q interval.

Summary

Infarction of the cardiac auricles (atria) was found in 17 per cent of 182 cases of myocardial infarction that were proven at autopsy. Abnormalities in the auricular complex of the electrocardiogram were present in 74 per cent of the cases of atrial infarction, but in only 9 per cent of all cases of

infarction of the ventricles. Ligation of the atrial arteries in dogs produced abnormal auricular mechanism in only 6 out of 20 experiments. In 4 additional experiments there was a transient change in the contour of the P wave. Depression of the P–Q segment of the electrocardiogram was seen in 4 instances in which the atrial arteries were ligated. Abnormality in auricular mechanism is the most reliable clue to the clinical diagnosis of infarction of the atria.

References

Abramson, D. I., Fenichel, N. M., and Shookhoff, C. (1938). *Amer. Heart J.*, **15**, 471.
Bean, W. B. (1938). *Ann. intern. Med.*, **12**, 71.
Clerc, A., and Levy, R. (1925). *Bull. Mém. Soc. méd. Hôp. Paris*, **49**, 1603.
Clowe, G. M., Kellert, E., and Gorham, L. W. (1934). *Amer. Heart J.*, **9**, 324.
Condorelli, L. (1929). *Z. ges. exper. Med.*, **68**, 493.
Davenport, A. B. (1928). *Amer. J. med. Sci.*, **176**, 62.
Feil, H., Cushing, E. H., and Hardesty, J. T. (1938). *Amer. Heart J.*, **15**, 721.
von Glahn, W. C. (1936). *Diseases of the Coronary Arteries and Cardiac Pain.* The MacMillan Company, New York, p. 143.
Gross, L. (1921). *The Blood Supply to the Heart.* Paul B. Hoeber, New York.
Hahn, L., and Langendorf, R. (1939). *Acta med. Scand.*, **100**, 279.
Krumbhaar, E. B., and Crowell, C. (1925). *Amer. J. med. Sci.*, **170**, 828.
Laignel-Lavastine, Liber, A. F., and Bidou, S. (1934). *Arch. Mal. Cœur*, **27**, 580.
Lambert, J. (1937). *Ibid.*, **30**, 3.
Langendorf, R. (1939). *Acta med. Scand.*, **100**, 136.
Lisa, J. R., and Ring, A. (1931). *J. Lab. clin. Med.*, **16**, 1083.
Meek, W. J., Keenan, M., and Theisen, H. J. (1928–29). *Amer. Heart J.*, **4**, 591.
Sanders, A. (1939). *Amer. J. med. Sci.*, **198**, 690.
Shipley, R. A., and Hallaran, W. R. (1936). *Amer. Heart J.*, **11**, 325.

PROGNOSIS OF RIGHT BUNDLE BRANCH BLOCK: A STUDY OF 104 CASES*

BY

GEORGE A. PERERA, SAMUEL A. LEVINE, AND HERMAN ERLANGER

* *From the Medical Clinic of the Peter Bent Brigham Hospital, U.S.A.*

Received December 29, 1941

Prompted by the clinical impression that patients with right bundle branch block have a better prognosis than do those with cardiographic evidence of a left bundle lesion, a study of a group of cases with the former disorder has been prepared with particular reference to the survival time following diagnosis.

The first description of the electrocardiographic manifestations of bundle branch interruption in 1910 by Eppinger and Rothberger and later by Lewis in 1916 was followed by a period of classification. The criteria of Carter (1914) were rightfully questioned by numerous observers (Oppenheimer and Rothschild, 1917; Oppenheimer and Pardee, 1920; Fahr, 1920; & Mann, 1920), until Barker, Macleod, and Alexander (1930) presented substantial proof (supported later with Wilson, 1932) that the common type of bundle branch block was left, and not right as was formerly thought; and that the unusual type of block was in reality due to a defect in the right bundle branch. In 1934 Bayley divided the curves of right bundle branch block into four clearly differentiated groups.

In recent years it has been suggested that a deviation of the electrical axis plays a role in the formation of the characteristic curves of bundle branch block (Prinzmetal, Oppenheimer, and Dack, 1937), and that the type of block may depend on which ventricle is predominantly enlarged (Master, Kalter, Dack, and Jaffe, 1940). Even the careful review and histopathological analysis of Yater (1938) leaves doubt as to exact clinical correlations. One is forced to admit that the diagnosis of right or left bundle branch block is purely electrocardiographic, cannot be foretold by examination of the patient, and cannot always be determined by microscopic section. Furthermore, the exact mechanism whereby these curves are produced is not completely understood.

Our Material and Results

One hundred and four cases of right bundle branch block were selected from private records and from the house and out-patient departments of the Peter Bent Brigham Hospital (60 and 44 cases respectively) on the basis of their

* An abstract of this paper was presented before the New England Heart Association at Boston, January, 1941.

fulfilment of electrocardiographic criteria of diagnosis. Cases of bundle branch block with short P–R interval (Wolfe-Parkinson-White syndrome), which have a good prognosis, were excluded. Serological data were available in about one half the group, and on the charts of three-quarters specific answers were given to questions concerning a previous history of rheumatic fever or its manifestations. Follow-up information was secured in some instances by letters from either the patient or his family physician, and in the remainder by our own examination.

All cases with a QRS interval of 0·12 sec. or over and a conspicuous S wave in lead I (Wilson, Johnston, Hill, and Macleod, 1934; & Wilson, Johnston, and Barker, 1934) were selected; all others were discarded. Although the T waves were upright in lead I and inverted in lead III in all but 4 instances, and increased amplitude of the QRS deflections was present in all but 6 cases, these were not used as diagnostic criteria.

Sex and Age.—The average age of the 104 patients was 56 years. Of these, 75 were male and 29 were female. The men averaged 55 and the women 58 years of age. The age and sex distribution are illustrated in Fig. 1. It is

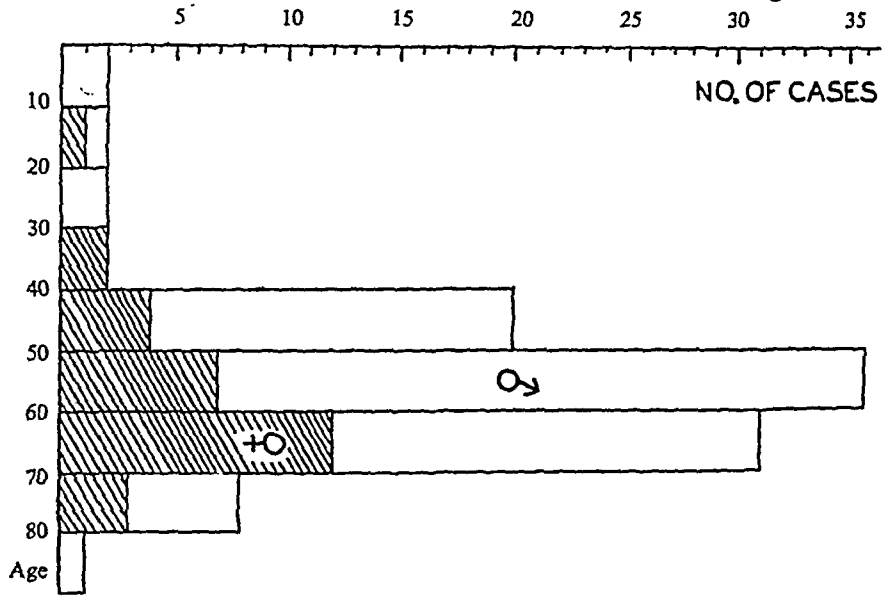

FIG. 1.—Age distribution of 104 cases of right bundle branch block when the diagnosis was first made, males and females.

of some interest that the youngest was 5 years old, and that there were four under 20 years of age.

Antecedent Cardiac Symptoms.—Before the diagnosis of right bundle branch block by electrocardiogram, 9 patients denied any symptoms or signs referable to the heart; in fact the condition in these cases was entirely symptomless. The average duration of antecedent symptoms in the entire group was two years and nine months. Of those with cardiac manifestations (95 of the 104 cases) major complaints were as follows: 53 had dyspnœa; 39, angina

pectoris; 15, præcordial (but not anginal) pain; 12, palpitation; 10, syncopal attacks; and 8, a history of dizziness. As the presenting complaint, angina pectoris was the chief difficulty in 30, dyspnœa in 27 cases.

Congestive Failure.—On examination at the time of diagnosis, 77 patients showed no signs of right- or left-sided cardiac insufficiency, 14 showed slight evidence of failure, 12 moderate evidence, and only 1 severe congestive failure. The comparative benignity of right bundle branch block becomes evident from these figures.

Cardiac Enlargement.—32 had a slight increase and 18 showed enlargement well beyond the left mid-clavicular line. In 9 the cardiac borders could not be determined. There was no enlargement of the cardiac area by percussion in 40. In 11 of the 24 patients, who had teleo-radiograms taken, an increase in the size of the heart was apparent.

Blood Pressure.—The following figures exclude the determinations obtained in the 3 patients who were *in extremis* when first seen. The average blood pressure of 101 patients was 155 mm. systolic, and 88 mm. diastolic. 59 patients had systolic pressures over 140; these ranged up to 240 mm., the average being 178 mm. ; the diastolic readings were nearly all greater than 90 mm., and ranged from "0" to 165 mm., the average being 96 mm. Of these hypertensive cases, 38 (64 per cent) were males, the remaining 21 (36 per cent) being females. 42 patients had systolic readings of from 100 to 140 mm., the corresponding diastolic pressures being from 60 to 90 mm. Of these cases, 36 (86 per cent) were males, while the remaining 6 (14 per cent) were females. It is apparent that the blood pressure in these cases may vary from low to extremely high levels, though on the average it is slightly elevated.

Auscultation of the Heart.—Reduplicated heart sounds, gallop rhythm, and pulsus alternans are often regarded as bearing some relationship to bundle branch block. It is of interest that gallop rhythm was noted in but 10 instances, reduplicated sounds heard in 6, and pulsus alternans present in but 5. Except in one instance, all patients having a protodiastolic gallop or alternating pulse showed signs of advanced cardiac disease and death occurred within two years. A specific notation as to the presence or absence of these signs was made in 80 per cent of the series. The most common auscultatory abnormalities were an apical systolic murmur (24 patients) and distant heart sounds (20 patients).

QRS Interval.—68 cases had a QRS interval of 0·12 sec., 18 of 0·13 sec., 14 of 0·14 sec., 3 of 0·15 sec., and 1 case an interval of 0·16 sec.

All of the patients with right bundle branch block in this series fitted into one of the four groups described by Bayley in 1934 (Fig. 2). This investigator classified 70 cases with right-sided bundle branch lesions, and found that 20 per cent were in group I, 33 per cent in group II, 40 per cent in group III, and 7 per cent in group IV. Our findings were very similar with 23 per cent in the first group, 28 per cent in the second, 45 per cent in the third, and 4 per cent in the fourth category.

Associated Electrocardiographic Abnormalities.—As regards disorders of rhythm, premature ventricular beats were demonstrated in 8 cases, premature

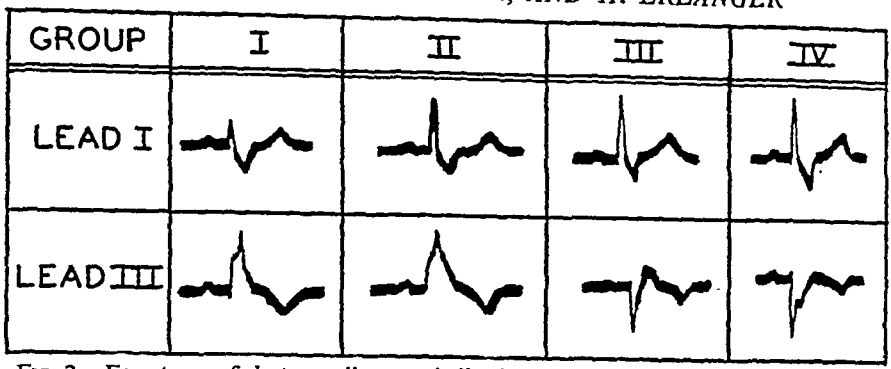

FIG. 2.—Four types of electrocardiograms indicating right bundle branch block, according to Bayley classification.

auricular contractions in 4, auricular fibrillation in 4, and sinus pauses in 2. Conduction disorders were found in 9 patients: delayed auriculo-ventricular conduction in 4, incomplete A-V block with dropped beats in 3, and intermittent complete block in 2. Low voltage was recorded in 6 cases.

Other changes appeared only in subsequent electrocardiograms. Two patients developed auricular fibrillation some time after the original diagnosis of bundle branch block, one partial block became complete, one with regular rhythm showed a complete block, and in one instance there was lengthening of the P–R interval.

Ætiology.—Hypertensive cardiovascular disease was the underlying cause in 48 patients. Degenerative heart disease was the cause in 40: it was diagnosed by the presence of cardiac signs or symptoms in the absence of hypertension, valvular disease, or other obvious cause. Rheumatic heart disease with damaged valves were the cause in 9, congenital defect in 2, and syphilitic aortitis with aortic insufficiency in 1 patient. In 4 patients no definite diagnosis was established: one was a young man without apparent illness, the second had gout, the third pneumonia, and the fourth had myxœdema.

A clinical diagnosis of myocardial infarction was made, either before or after the appearance of the bundle branch lesion in 10 patients. Other associated diagnoses included diabetes in 6, asthma in 3, and carotid sinus sensitivity in 2 patients. One of the hypertensive group had a toxic nodular goitre during the course of his illness.

Follow-Up.—Of the 104 in this series, 41 were capable—during the period of observation—of carrying out their normal activities without limitation because of cardiac symptoms. 13 patients were seen at the time of diagnosis only, and no subsequent data could be obtained. Of the 91 patients followed, 62 were living an average of four years and one month later, while 29 died within an average of three years. 29 patients were known to have died, 4 of cardiac failure, 3 of coronary occlusion, and 2 of cerebral hæmorrhage. 9 died of unrelated causes, and in 11 cases information as to cause of death was inadequate. A more detailed analysis is shown in Table I.*

* In the period during which this manuscript was being prepared for publication, Willius, Dry, and Reeser (1941, *Arch. intern. Med.*, 67, 1008, *ibid.*, 67, 1027, *ibid.*, 67, 1034) have in general confirmed these results.

TABLE I

THE PROGNOSIS OF PATIENTS WITH RIGHT BUNDLE BRANCH BLOCK

	PATIENTS ALIVE AT END OF					
	1 year.	2 years.	3 years.	4 years.	5 years.	10 years.
62 patients alive when last followed ..	52 (84%)	44 (71%)	33 (53%)	25 (40%)	19 (31%)	5 (8%)
29 patients known to have died ..	18 (62%)	15 (52%)	11 (38%)	9 (31%)	7 (24%)	1 (3%)
23 patients known to have died * ..	18 (77%)	15 (65%)	11 (48%)	9 (39%)	7 (30%)	1 (4%)
91 total followed patients	70 (77%)	59 (65%)	44 (48%)	34 (37%)	26 (29%)	6 (7%)

* This group omits 6 cases that died within a few days of first examination.

Six patients (21 per cent of the group followed until death) died within a few days of the original diagnosis. One patient, with angina pectoris, died of metastatic neoplasm sixteen years and seven months after the discovery of right bundle branch block, and another was known to be alive after seventeen years. Patients under 50 years of age lived an average of five years, while those aged 50 or over averaged just under three years.

PROGNOSIS

When one speaks of the prognosis of patients with bundle branch block, it must be realized that the lesion may have ante-dated its electrocardiographic demonstration by an indefinite period. Furthermore, it might be thought that the average survival time amongst the group still living, if followed to death, would be decidedly greater than that of the known fatal cases. This does not prove to be so in studies of prognosis when the number of cases analysed is sufficient; the main reason, of course, being that amongst the living cases there are some, who have only recently been observed for the first time and may yet die within a short period, to compensate for those already known to be alive for a great many years. In fact, Table I shows very little difference between the survival time of the fatal and non-fatal cases.

Attempts at comparison with other follow-up studies of bundle branch block show that diagnostic criteria were not always identical, presentation of analyses were not always similar, and in some series, electrocardiograms were taken routinely, while in others, only in suspected heart disease. In addition, as this disorder of conduction has only been known for a short period of time, early investigations included a smaller number of cases, shorter survival observations, and fewer cases followed until the fatal termination.

Early studies (Carter, 1914; Willius, 1919 ; Herrick and Smith, 1922;

Hart, 1925; Cowan and Bramwell, 1925; Talley and Reed, 1926; Bach, 1930; Campbell and Turkington, 1931; Graybiel and Sprague, 1933; & King, 1934) included cases with QRS intervals of 0·11 sec., often failed to separate right and left types or added indeterminate forms of bundle branch block. In almost all such series, consisting chiefly of cases of left-sided disorders, the majority of patients were dead six to fourteen months after diagnosis. Von Deesten and Dolganos (1934) were among the first to comment on the favourable prognosis of right bundle branch block (5 cases), and the 64 cases presented by Wood, Jeffers, and Wolferth (1935) did unusually well.

On the other hand, Sampson and Nagle (1936) reported that only 27 per cent of 109 cases of left bundle branch conduction defect that terminated fatally were dead in the first year and 42 per cent by the second year, although they included those with a QRS interval of 0·11 sec. Freund and Sokolov (1939), using adequate diagnostic criteria, claimed that the average length of life after discovery of the lesion was about the same (one year) in 58 fatal cases of left block as in 32 cases of right bundle branch block. Bishop and Carden (1939) found the average survival time of 29 cases that died was three years, but intermediate and a few right-sided lesions were included. Kaplan and Katz (1939), again without subdivision as to types, stated that 80 per cent of 75 known fatal cases died during the first year.

It is evident from the preceding that a great deal of variation exists in prognostic methods and results, but that only the left bundle branch block series of Sampson and Nagle (1936) and Bishop and Carden (1939) show longer survival periods than do the cases of right bundle branch block presented in this study. It is also true that other reports of right bundle branch block are not consistent, Wood and his associates (1935) differing widely from Freund and Sokolov (1939) in their respective studies. Yet it is unfair to place the majority of these follow-up series side by side because of difference in diagnostic criteria, admixtures of indeterminate types of block, and dissimilar methods of statistical analysis.

For this reason a group of 60 patients with left bundle branch block (with QRS interval of 0·12 sec. or over, and an upward deflection lead I without Q or S waves), followed until death, were selected for comparison. This series was prepared so that the ratio of private and hospital cases and the dates of the original diagnosis were similar to the 29 fatal cases reported above. The average age of this group was 59 years. The results (Fig. 3) show decidedly more favourable survival figures in patients with a right bundle branch conduction defect. The average time of death after diagnosis of the left bundle group was one year and two months, with 60 per cent of the cases dead by the end of the first year. The longest survival time in this fatal group was five years and eight months. One patient not included in this study, because he is still alive, is in fairly good health fifteen years after left bundle branch block was first discovered.

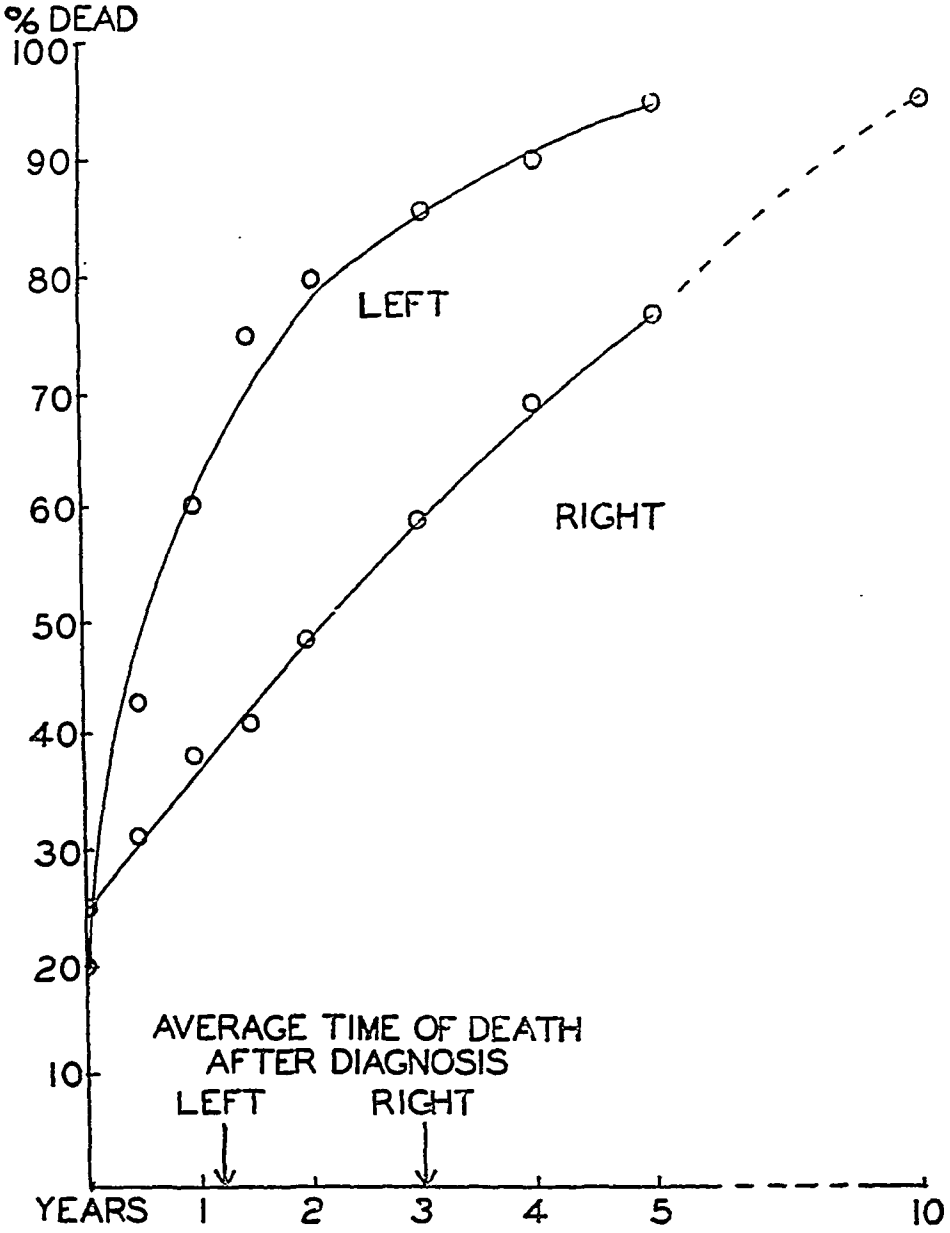

Fig. 3.—Comparison between the survival period of cases of left and right bundle branch block.

Conclusions

An analysis of 104 cases of right bundle branch block has been prepared.

It was observed that reduplicated heart sounds, gallop rhythm, and pulsus alternans were uncommon in this series. The two latter disorders were noted in a small group that had advanced heart disease.

Forty per cent of the patients had no appreciable subjective discomfort from the heart. In fact, some have no subjective or objective evidence of heart disease apart from the right bundle branch block.

The average survival time after the diagnosis of right bundle branch block of 29 fatal cases was three years. If the 6 cases that came into the hospital more or less moribund and died within a few days are excluded, the average survival period of the fatal group was four years and five months. Of the 62 patients alive when last seen or heard from, the average survival period was four years and one month. The longest survival period amongst the living cases was seventeen years, and amongst the fatal cases, sixteen years and seven months.

The clinical impression that patients with right bundle branch block have a distinctly more favourable prognosis than do those with a left bundle branch lesion has been sustained.

References

Bach, F. (1930). *Quart. J. Med.*, **23**, 261.
Barker, P. S., Macleod, A. G., and Alexander, J. (1930). *Amer. Heart J.*, **5**, 720.
Bayley, R. H. (1935). *Amer. J. med. Sci.* **188**, 236.
Bishop, L. G., Jr., and Carden, G. A., Jr. (1939). *Amer. Heart J.*, **17**, 275.
Campbell, S. B. B., and Turkington, S. I. (1930). *Quart. J. Med.*, **24**, 481.
Carter, E. P. (1914). *Arch. intern. Med.*, **13**, 803.
Cowan, J., and Bramwell, J. C. (1925). *Quart. J. Med.*, **19**, 95.
Eppinger, H., and Rothberger, C. J. (1910). *Z. klin. Med.*, **70**, 1.
Fahr, G. (1920). *Arch. intern. Med.*, **25**, 146.
Freund, H. A., and Sokolov, R. (1939). *Ibid.*, **63**, 318.
Graybiel, A., and Sprague, H. B. (1933). *Amer. J. med. Sci.*, **185**, 395.
Hart, T. S. (1925). *Arch. intern. Med.*, **35**, 115.
Herrick, J. B., and Smith, F. M. (1922). *Amer. J. med. Sci.*, **164**, 469.
Kaplan, L. G., and Katz, L. N. (1939). *Amer. Heart J.*, **18**, 145.
King, J. T. (1934). *Amer. J. med. Sci.*, **187**, 149.
Lewis, T. (1916). *Phil. Trans. Roy. Soc.*, *B*,**207**, 221.
Mann, H. (1920). *Arch. intern. Med.*, **25**, 283.
Master, A. M., Kalter, H., Dack, S., and Jaffe, H. L. (1940). *Amer. Heart J.*, **20**, 186.
Oppenheimer, B. S., and Rothschild, M. A. (1917). *J. Amer. med. Ass.*, **69**, 429.
——, and Pardee, H. E. B. (1920). *Proc. Soc. exper. Biol. and Med.*, **17**, 177.
Prinzmetal, M., Oppenheimer, B. S., and Dack, S. (1937). *J. Amer. med. Ass.*, **108**, 620.
Sampson, J. J., and Nagle, O. E. (1936). *Amer. J. med. Sci.*, **191**, 88.
Talley, J. E., and Reed, O. K. (1926). *Amer. Heart J.*, **1**, 262.
von Deesten, H. F., and Dolganos, M. (1934). *Amer. J. med. Sci.*, **188**, 231.
Willius, F. A. (1919). *Arch. intern. Med.*, **23**, 431.
Wilson, F. N., Macleod, A. G., and Barker, P. S. (1932). *Amer. Heart J.*, **7**, 305.
——, Johnston, F. D., Hill, I. G. W., Macleod, A. G., and Barker, P. S. (1934). *Ibid.*, **9**, 459.
——, ——, and Barker, P. S. (1934). *Ibid.*, **9**, 472.
Wood, F. C., Jeffers, W. A., and Wolferth, C. C. (1935). *Ibid.*, **10**, 1056.
Yater, W. M. (1938). *Arch. intern. Med.*, **62**, 1.

DR. SAMUEL JOHNSON:

HIS MEDICAL HISTORY AS RECORDED BY JAMES BOSWELL

BY

TERENCE EAST

Received February 14, 1942

The medical man who reads Boswell's *The Life of Samuel Johnson, LL.D.* with a professional eye will find therein the history of a case of high blood pressure, the course of which can be traced through many familiar phases.

Johnson died at the age of seventy-five, on December 13, 1784. "His person was large and robust, I may say approaching the gigantic." To us nowadays, by a stroke of irony which he might have appreciated, for he was a water-drinker much of his life, "his countenance of the cast of an ancient statue" has been made familiar by an advertisement for beer! His face was scarred with scrofula, for which, at the age of thirty months, he had been taken to Queen Anne to be touched for the King's Evil; he remembered her dimly in later years as a "lady in diamonds and a long black hood." At the age of sixty-four, in spite of his unwieldy frame—for "when he walked it was like the struggling gait of one in fetters; when he rode, he had no command or direction of his horse, but was carried as if in a balloon"—he undertook the "Tour of the Hebrides": no small journey in those days for a man of his age, even for one in good health. But as by many, whose tissues are good, the high blood pressure was well tolerated, at first. His parents had lived long, his father dying at seventy-eight and his mother at ninety.

Gout, high blood pressure, and arteriosclerosis are closely associated, and it is with an attack of gout at the age of sixty-five that we see the first indications of the illness that troubled Johnson's last years. It is not surprising to find the ". . . pangs arthritic that infest the toe of libertine excess" as Cowper* called them, so prevalent in the gluttonous eighteenth century, in one whose appetite can only be described as voracious.

Two years later, at sixty-seven, he writes to Boswell of another attack: "I was seized with gout, and am not quite well. The pain has not been violent, but the weakness and tenderness were very troublesome, and what is said to be very uncommon, it has not alleviated my other disorders." The idea of gout relieving other disorders was widely held; and one can recall several true examples of intercurrent infection curing another disease. The other disorders to which Johnson refers are, no doubt, "a difficult and laborious respiration,"

* *The Task.*

which Boswell had already noted with alarm and foreboding; for which he "lost six and thirty ounces of blood in a few days," apparently with some benefit.

Next year Johnson writes: "The hand of time or disease is heavy upon me. I pass restless and uneasy nights, harassed with convulsions of my breast, and flatulencies of my stomach." Perhaps the gallstone that was found at autopsy was responsible for some of this gastric derangement. At the age of seventy-one he was "hindered by a vexatious and incessant cough," the treatment for which he describes thus to his friend and physician, Dr. Lawrence: "bled once, fasted four or five times, taken physick five times" (purges, no doubt) "and opiates, I think, six"—sound treatment for such a man, and perhaps fasting, in these days, might be recommended for plethoric patients more often.

On his birthday, however, Johnson felt that he was beginning the seventy-second year of his life with more strength of body and greater vigour of mind than, he thought, was common at that age. This is about the last reference to good health that we find. In the early part of next year he complains again of his bronchitis: "a troublesome time with my breath; and a violent cold," for which he was "let blood three times." A "catarrhous cough" still harassed him in June. Twelve months later, when he was seventy-four, Boswell comments: "My anxious apprehensions proved to be too well founded," for Johnson had a stroke. His vivid description of this attack is given in a letter to his old friend, Mrs. Thrale, two days later.

"I went to bed, and in a short time waked and sat up, as has long been my custom, when I felt a confusion and indistinctness in my head, which lasted, I suppose, about half a minute. I was alarmed, and prayed God that however He might affect my body, He would spare my understanding. This prayer, that I might try the integrity of my faculties, I made in Latin verse. The lines were not very good, but I knew them not to be very good: I made them easily, and concluded myself to be unimpaired in my faculties. Soon after I perceived that I had suffered a paralytic stroke, and that my speech was taken from me." For such a one as Johnson, this was perhaps the most severe deprivation that he could have suffered. But he was so little upset, "that I wondered at my own apathy."

He at once sent for his neighbour, Dr. Brocklesby, a Quaker, practising near the Strand, and for his "dear Dr. Heberden," of whom the poet Cowper * wrote,

> "Virtuous and faithful Heberden, whose skill
> Attempts no task it cannot well fulfill."

By July, he was able to write: "The physicians consider me cured, and I had leave four days ago to wash the cantharides from my head." He was sufficiently recovered to pay several visits in the country.

It seems likely that this attack was a transient paresis due to cerebral arteriospasm, of the type commonly met with in hypertensive encephalopathy.

In September he was again attacked by gout, which, he writes, "has within

* *Retirement, Satirical and Didactic Poems.*

these four days come upon me with a violence which I had never experienced before." At the end of the year Boswell records: "He was seized with a spasmodic asthma of great violence, being obliged to sit up all night in his chair, a recumbent posture being so hurtful to his respiration that he could not endure lying in bed." Such asthma was surely what we call cardiac: bronchial asthma would hardly appear for the first time at his age. This development of nocturnal dyspnœa was ominous; and the gravity of the outlook was increased by "that oppressive and fatal disease, a dropsy." In those days, one may remark, dropsy was regarded as a disease *sui generis*; it was not recognized as a result of failure of the heart.

Johnson had entered upon the last year of his life. The first attack of dyspnœa seems to have come on very suddenly on exertion. Early in December he was going to the opening meeting of a new club that he had founded, the "Essex Head," in Essex Street when, he writes: "I was seized with a spasmodic asthma, so violent that with difficulty I got to my own house, in which I have been confined eight or nine weeks, and from which I know not when I shall be able to go even to Church. A dropsy gains upon me; my legs and thighs are very much swollen with water." Anxious over these symptons, and "extremely afraid of dying," he wrote to Boswell to ask him to obtain the opinions of the physicians in Edinburgh on his case. Before the advice came he seems to have already gained some "unexpected relief by the discharge of twenty pints of water." Perhaps this was due to the vinegar of squills which he had begun to take. Boswell wrote an excellent summary of his case, which he communicated to the great Edinburgh physicians, Cullen, Hope, and Monro. He noted the sense of præcordial constriction on exposure to cold (this winter was a very severe one), and mentioned the tincture of laudanum Johnson took for his nocturnal dyspnœa. But what the doctors advised is unfortunately not recorded.

Johnson was interested in his symptoms, and had read Sir John Floyer's book on asthma. One may recall that Floyer was for many years, until his death in 1734, physician at Lichfield, the birthplace of Johnson, and possibly may have attended him as a child and advised his being touched by Queen Anne. Writing to his friend Langton in March, 1784, he remarks: "My asthma is, I am afraid, constitutional and incurable; but it is only occasional, and unless it be excited by labour, or by cold, gives me no molestation, nor does it lay any close siege to life, for Sir John Floyer, whom the physical race consider as author of one of the best books upon it, panted on to ninety as was supposed." From this one gathers that Johnson thought his case might have a similar prognosis. But he was quoting without the book. During the spring and summer he was free from dropsy, and was able to take a jaunt to Oxford in June, and thence on to Lichfield for five days. Here, on July 19, he apparently borrowed Floyer's text book from the Cathedral library* for further information about his asthma, which seems to have returned. The conclusion was unsatisfactory. Writing to Dr. Brocklesby the next day he reported that "The asthma has no abatement. Opiates stop the fit so that I can sit and sometimes lie easy . . ; I am looking into Floyer, who lived with his asthma till almost

* *Floyer*, by J. A. Gunn, in *British Masters of Medicine*.

his ninetieth year. His book by want of order is obscure; and his asthma, I think, not of the same kind with mine." In which deduction he was correct, for Floyer had bronchial asthma all his life, and Johnson's was certainly cardiac.

This holiday and its travelling in coaches was too much for his heart. The increasing dyspnœa was followed by a return of dropsy in the middle of August. It is interesting to note that in one letter he says: "My respiration gets more and more ease and liberty. I went to Church yesterday after a very liberal dinner, without any inconvenience," while a few lines further on he remarks: "the water rises, though it does not rise very fast." Evidently the relief of the dyspnœa occurred when the failure of the right ventricle began to ease the state of his pulmonary circulation, embarrassed by a failing left ventricle. "The squills I have not neglected; for I have taken more than a hundred drops a day, and one day took two hundred and fifty, which, according to the popular equivalent of a drop to a grain, is more than half an ounce." Thanking his physician for his attention, he pays him the neat compliment: "If the virtue of the medicines could be enforced by the benevolence of the prescriber, how soon should I be well." But he could be critical enough of what was prescribed if he thought it of no value. Perhaps something other than squills had been suggested. "I never," he writes to Brocklesby, "thought well of Dr. James's compounded medicines." One may recall that Dr. James patented a famous febrifuge powder of phosphate of lime and oxide of antimony. Johnson esteemed him, for he wrote a dedication to Dr. Meade in his book, and said of him, "no man brings more mind to his profession"—"This prescription exhibits a composition of about three hundred and thirty grains, in which there are four grains of emetic tartar, and six drops of thebaick tincture." (This was tincture of opium, for opium was prepared at Thebes). "He that writes thus surely writes for show. The basis of his medicine is the gum ammoniacum" (an expectorant from dorema ammoniacum), "which dear Dr. Lawrence used to give, but of which I never saw any effect. We will, if you please, leave this medicine alone. The squills have every suffrage, and in the squills we will rest for the present." His critical mind detected the shams of the mediæval polypharmacy still much in vogue, and recognized a potent drug when he tried it. As a result, by October the failure seems to have abated, for he could write that he was relieved from the dropsy. After visiting Birmingham, and Oxford again, he was back in London by the middle of November. The journeys seem to have brought on heart failure again, for he writes: "I am as I was, and having seen Dr. Brocklesby, am to ply the squills." Up to this date he had kept a Latin diary of his case, "*Aegri Ephemeris*," but it has not survived.

The end was near. The dropsy rapidly accumulated once more. In order to relieve it incisions were made in his legs by Cruikshank, the surgeon; "a sweet blooded man," as Johnson called him, but a timid operator, who did not cut deep enough to satisfy his patient, who himself "with his usual resolute defiance of pain cut deep, when he thought that his surgeon had done it too tenderly." A few days before his death he appropriately quoted to Brocklesby the lines from *Macbeth*:

> " Cans't thou not minister to a mind diseased;
> Pluck from the memory a rooted sorrow;
> Raze out the written troubles of the brain;
> And, with some sweet oblivious antidote,
> Cleanse the stuff'd bosom of that perilous stuff
> Which weighs upon the heart ? "

His physician at once capped the quotation by answering

> " . . . therein the patient
> must minister to himself."

a neat rejoinder, which pleased Johnson much, if it gave but little physical help. On hearing that he could not recover, he refused all further drugs; he wished to have his mind unclouded at the end. So he died quietly, somewhat troubled with breathlessness and pain in the legs, his mind clear, on December 13. He complained less of his dyspnœa in this, his third and last, attack of failure than at first, presumably because once again failure of the right ventricle came on fast.

The report of the post-mortem examination can be seen in the library of the Royal College of Physicians. It was done two days after death by Dr. J. Wilson; Mr. Cruikshank and Dr. Heberden being present. I quote the account. " Dr. Johnson being very importunate to have the water entirely gone, the morning of the day on which he died, repeated the operation himself, and cutting very deep. For several years he had been troubled with asthma, for which he commonly used to take opium. The lungs did not collapse as they usually do when air is admitted, but remained distended as if they had lost the power of contraction. The air cells on the surface of the lung were also much enlarged, the right lobe adhered very strongly to the diaphragm. No water was found in the cavity of the thorax. The heart was exceedingly large and strong; the valves of the aorta were beginning to ossify. No more fluid than common was contained in the pericardium. In the peritoneum there seemed to be incipient peritoneal inflammation and ascites. The liver and spleen were large and firm. The spleen had almost the feel of cartilage. A gallstone the size of a pigeon's egg was taken out of the gall bladder." He had not been much troubled by this stone apparently; very likely it was a cholesterol solitaire, which often causes little or no symptoms. The account describes also " hydatids " in the right kidney, and how the left was almost entirely destroyed, with two very large hydatids formed in its place. " Mr. White pricked his finger. The next morning he had red lines running up his arm, and a slight attack of fever."

The autopsy revealed much that we would expect. The severe degree of hypertrophic emphysema was likely to be found in a man who had suffered much from bronchitis, and it contributed a great deal to the acuteness of his dyspnœa. The great hypertrophy of the heart was no doubt the result of high blood pressure, for the early calcification of the aortic valves can hardly have amounted to actual stenosis. The liver and spleen showed the effects of chronic venous engorgement. The kidneys were of the small

gouty type, with retention cysts, but there is no hint that they were deficient enough to cause uræmia.

Summary

The medical history of Samuel Johnson is that of a man, with good family history, who had gout and developed high blood pressure, probably rather late, and then had a transient stroke. Failure of the left ventricle came on, and emphysema aggravated his symptoms. He was, for a time, successfully treated by rest, squills, and opium. But on his recovery, he undertook too much travelling and brought on failure again. He finally died in his third bout of heart failure, about a year after the onset of the first attack.

It seems natural and almost inevitable that Dr. Johnson, so loved by Englishmen for his ordinary qualities, should have died from such a common and straightforward combination of diseases.

The fact that Boswell's description enables one to deduce so much, and that it might indeed serve as a model lesson for a medical student, goes some way to explain the immense popularity of his book.

INVERSION OF T WAVES AFTER LONG PAROXYSMS OF TACHYCARDIA

BY

MAURICE CAMPBELL

From the Cardiographic Department, Guy's Hospital

Received February 4, 1942

For several years I have been struck by odd cases where changes in the T waves and even sharp inversion of these waves after long paroxysms of tachycardia—in appearance suggestive of coronary occlusion or at least of coronary disease—seemed from the subsequent course of the patient to be no more than the effect of the long paroxysm. Sometimes when these changes were observed it was difficult to exclude active though undiagnosed myocardial disease, such as might follow a silent cardiac infarct; and sometimes the patient had taken digitalis or quinidine in an effort to arrest the attack in such amounts that these might possibly have caused the T wave inversion, though considering the dosage and the short time for which the drug was taken this seemed most unlikely.

In a recent paper (Campbell, 1939) two illustrations of such changes were given with the legend " changes produced by a paroxysm, but simulating the changes after cardiac infarction."

In the first there was a fairly deep inversion of T of the " coronary " type in lead I with a correspondingly high T in lead III, two days after a paroxysm. After another two days these had both diminished, and three weeks later had returned to normal, the T wave being small but upright in lead I and flat in lead III (Fig. 21, A, B, and C, *loc. cit.*). This was from a patient who started having paroxysms after diphtheria, and appeared in good health in the intervals.

In the second there was inversion of the whole S–T interval (perhaps of a less obvious coronary type) in leads II and III, one day after a long paroxysm; eleven days later these effects had greatly diminished and eighteen days later they had completely disappeared (Fig. 22, A–D, *loc. cit.*). This was from a man, aged 40, whose attacks had been present for at least fifteen years, leaving him without any disability between times in the earlier period, but with some gradually increasing dyspnœa in the later period.

In neither case was it thought likely that the change was due to a cardiac infarct or to coronary disease—partly on clinical grounds, and partly because of the speed with which the change was reversed after the attack. But both these patients died, one suddenly and one with congestive failure, so that it was difficult to exclude with certainty coronary disease or organic myocardial

changes as the cause, though in the case in which there was an autopsy, no coronary disease was found.

The question is of real importance, because after a long paroxysm of tachycardia, a patient is likely to seek advice about the condition of his heart and this is increasingly likely to lead to an electrocardiogram being taken. When there are changes in the T waves or in the S–T interval suggestive of myocardial disease, it is most important that these signs should not be taken as definitive evidence of such disease, if in fact they are no more than the after-effects of the long paroxysm.

Special efforts were therefore made to obtain serial cardiograms shortly after long paroxysms from patients in whom the length of history of the paroxysms and the absence of any physical signs or symptoms suggesting heart disease made it almost certain that the heart was normal, except for the paroxysms.

First Case. The first patient, where we were fortunate enough to get the chance of taking such records, had started having typical paroxysms when she was 17, at first only lasting for an hour or two, every three months or so. When she came under my observation, aged 34, she was a healthy looking woman, with four children, and young for her years. Her attacks had become more frequent and lasted longer, up to 8 or even 16 hours. Since then she has been under my regular observation for another twelve years, and still, after this length of time shows no evidence of heart disease. During all this time she has averaged about ten attacks a year, lasting generally from 8 to 16 hours. Further details need not be given as a full account of her attacks was given in Table IX in the article already referred to (Campbell, 1939), and Fig. 12, 13, and 18 were taken from her. At no time has any abnormal physical sign been found, nor any evidence of heart disease except the paroxysms, though when they lasted for more than six or seven hours, she generally got anginal pain of increasing severity as they continued. Considering the rate of her attacks (about 220) she was not excessively incapacitated and had travelled some miles to see me in attacks, because in the earlier stage they could be stopped by pressure on the neck. In more recent years they have caused greater incapacity but one could hardly expect a woman at 45 to stand them as easily as at 30, and I do not think this need be taken as evidence of any heart disease. Incidentally she is a patient in whom treatment has been quite ineffective in controlling the incidence of her paroxysms—treatment with bromides, carminatives, digitalis, and quinidine having been tried. She has written to me within the last few weeks: even a period in the East End of London during the worst of the air raids had not upset her unduly, and on the whole her attacks had been less during the war than during the preceding years.

In October, 1938, we were able to get her admitted to hospital in an attack that had lasted three days. Pressure in the neck, 10 grains of quinidine sulphate, and 20 mg. of mecholyl, given intramuscularly, did not arrest the attack, which stopped after about six hours in bed.

Serial electrocardiograms after this paroxysm provided a good illustration,

with transient T_3 inversion, not unlike that seen after a cardiac infarct. The day after the paroxysm ended there was sharp T_3 inversion of the cove-shaped type (Fig. 1B) with a flattened T_2. The next day this was much less, but T_3

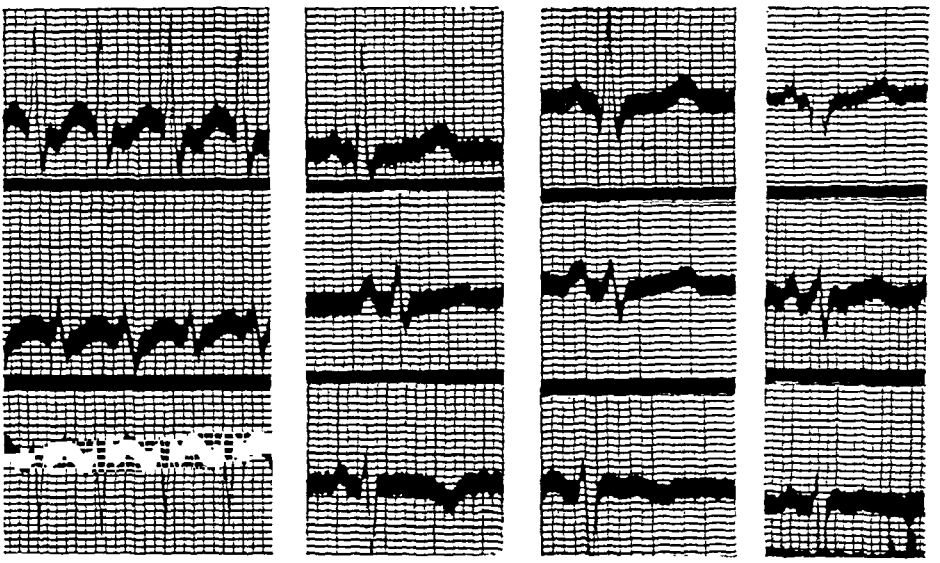

A B C D

FIG. 1.—"Coronary" T wave changes in lead III, one day after a long paroxysm, in a woman with a normal heart and a history of paroxysms for many years.
(A) Paroxysm of tachycardia (6/10/38).
(B) Inversion of T in lead III, one day later (7/10/38).
(C) Diminishing inversion of T in lead III, three days later (10/10/38).
(D) Disappearance of all inversion of T in lead III, six days later (13/10/38).

was still just inverted (Fig. 1C), and three days later the inversion had completely disappeared (Fig. 1D).

It seems improbable that after some hundreds of attacks spread over 30 years one should have recorded an exceptional one that was really due to some serious coronary episode; on the contrary, as the attack to her and to other observers seemed the same as all the others it is almost certain that such changes in the T waves occurred frequently whenever an attack was of sufficient length.

Second Case. During the same month, we obtained inconclusive records from another patient (Fig. 3) in whom we suspected similar changes (Fig. 2), but within two months after a longer attack we got most satisfactory evidence in her case also (Fig. 4). This second patient, who was first seen in 1932 when she was 44, had suffered from paroxysmal tachycardia since 17 years of age. She had diphtheria at 13, but no rheumatic fever, chorea, or rheumatism. The paroxysms were characteristic, and have since been confirmed graphically (Fig. 3A). From the age of 17 to 44, she was never six months without an attack and often had two a week. In 1932 she had fourteen attacks mostly lasting between 12 to 24 hours. In general they had lasted from 12–48 hours, though

some were shorter, and one, when she was 21, was said to have lasted for two weeks, and another, when she was 35, for three weeks. Bending or stretching were liable to start attacks and she was afraid of hurrying or sudden exertion because of them. She was able to carry on her work for the first three or four hours of an attack, but then generally felt she had to lie down, and if the attack was long, felt tired for a few days. Between the attacks she was able to lead a normal life.

On examination, nothing abnormal could be found. She was thin, but not more than usual. Her heart was not enlarged (12·0 cm. maximum transverse diameter) and the shape was normal. No murmurs were heard and the blood pressure was 130/80. At frequent examinations during the years 1932–1939 no change was observed. Her electrocardiogram was a little unusual with sharply pointed P_2, a notched upstroke of R in leads II and III, and some tendency to right axis deviation; part of the S–T interval was below the isoelectric line, but there was no inversion of the T waves. All these features were constant in many cardiograms taken between 1932–1938 (Fig. 2, A and B).

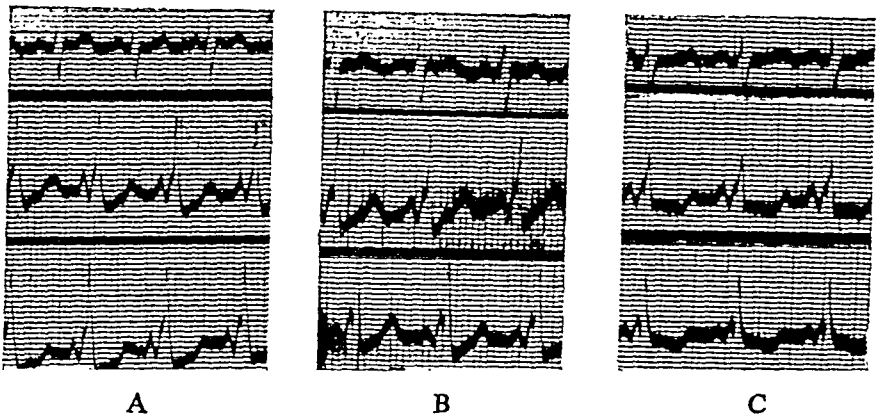

FIG. 2.—Increased inversion of the S–T period in leads II and III after a paroxysm of tachycardia.

(A) Normal for this patient (7/12/32).
(B) Normal, later (16/11/34).
(C) Some partial inversion of S–T in leads II and III, 5 days after a paroxysm (29/9/38).

In 1935, after an attack lasting six days, she started taking quinidine, 3 grains b.i.d., and had no attack for four months, and then one during each of the next three months, lasting 36, 48, and 17 hours.

She was seen again in September, 1938, having kept an exact record of her four attacks in seven months as follows: March, one of 5 days, 14 hours; June, one of 4 days, 1 hour; August, one of 5 days, 23 hours; and September, one of 5 days, 22 hours. The year had been unusual in the number of long attacks and the absence of shorter ones. Quinidine, as taken in small doses at home, did not appear of value in stopping the attacks, and the absence of short attacks was not due to her taking it regularly, though this seemed to have helped at first.

There was no increase in the size of the heart since 1932, no change of murmurs, and no rise of blood pressure, but the lower T waves in leads II and III (see Fig. 2C) in a cardiogram taken five days after this attack had stopped, made me decide to try to get records just after an attack in which she had taken no digitalis or quinidine, to see if myocardial change was developing or if this was another example of T wave changes after a paroxysm.

On October 11 she came to hospital after an attack which had lasted 8 hours; it was recorded (Fig. 3A) and stopped 17 minutes after she had been given

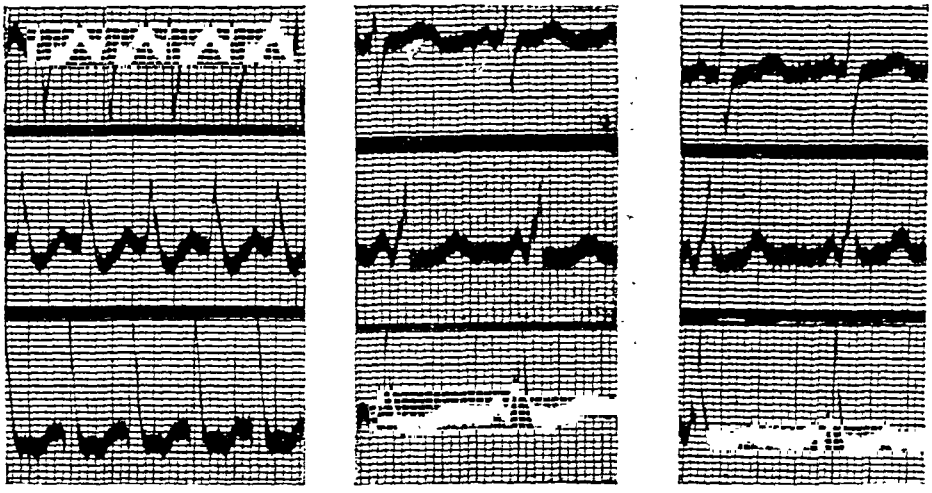

A B C

FIG. 3.—Showing the absence of anything more than minor changes after a shorter paroxysm in the same patient.

(A) Paroxysm of ten hours (11/10/38).
(B) Slight diminution of the voltage of S–T in leads II and III, two days later (13/10/38).
(C) Practical return to normal four days later (17/10/38).

1·5 mg. of prostigmin intramuscularly. A cardiogram taken two days later showed no change in the T waves except that more of S–T_3 was below the isoelectric level (Fig. 3B); after another four days this was back nearer to her normal (Fig. 3C).

On December 19, the day after an attack which had lasted six days and stopped 45 minutes after her second dose of 5 grains of quinidine (the first being two hours before), there was inversion of T in all leads, especially T_1 and T_2 and T_1 was almost cove-shaped (Fig. 4A). Three days later, T_1 was becoming upright, but T_2 was still inverted and T_3 was more inverted (Fig. 4B). A week later, and still more two weeks later (Fig. 4, C and D), the T waves had returned practically to her normal.

This attack seemed to her just the same as those that she had had for many years and her condition was unchanged after it.

These two patients seem specially good examples of the condition described, in that they have been under observation so many years with their paroxysms without any evidence of other heart disease, and it seems most unlikely that

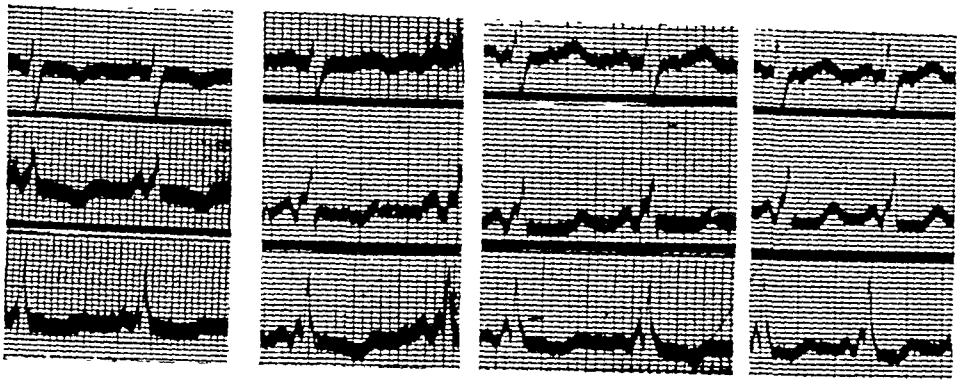

A B C D

FIG. 4.—Inversion of the T waves in all leads in the same patient after a long paroxysm.

(A) Deep inversion of T in leads I and II, one day after a paroxysm that had lasted six days (19/12/38).

(B) Disappearance of the inversion of T in lead I, but increase in the inversion of T in lead III, T in lead II remaining mainly inverted as before (22/12/38).

(C) Complete recovery of T wave in lead I and disappearance of most of the inversion of S–T in leads II and III (29/12/38).

(D) Further return towards normal (5/1/39).

anything recorded after these paroxysms was exceptional for these patients, and that therefore the T wave changes were the result of the length and severity of the paroxysms, and were not due to any acute organic disease of the heart muscle.

Third Case. I am indebted to Dr. John Parkinson for the notes and electrocardiograms of the following case. Although the details are not complete and it was not possible to follow him for long, it seemed worth including, because the changes were so striking and also because they were noted after three separate attacks.

D.S., aged 21, was in three hospitals for at least six weeks with a diagnosis of chronic myocarditis; no details are available as to why this diagnosis was made.

On January 12, 1940, after a month's sick leave, he returned to an R.A.F. station and at once reported sick. His pulse was almost imperceptible at the wrist, and the heart rate at the apex was 174. He said that the condition had started when he was on leave; that he felt breathless and was himself conscious of the rapid beating of the heart; that since the previous October he had suffered from five similar attacks; that all had started suddenly; and that the longest had lasted seven days.

He did not look ill in spite of the attack. Nothing abnormal was found on examination except that the blood pressure was 100/70. A cardiogram confirmed the diagnosis of paroxysmal tachycardia, and as the usual methods failed to stop it, he was given 3 grains of quinidine, after which the heart rate soon dropped to 80. Fig. 5A, taken the next day, showed deeply inverted T waves in leads II and III, such as one might expect after a large cardiac infarct or some other serious myocardial infection. But his age, the absence of symptoms, the quick recovery, and the recurrence of similar changes after two other attacks, all make this extremely unlikely. Within ten days this deep

inversion of T had completely disappeared in lead II, and almost completely in lead III (Fig. 5B).

Another attack started the next day and lasted two days. He was given 33 grains of quinidine and the attack stopped; a cardiogram taken two days later again showed inversion of the T waves in leads II and III.

Nine days later there was a third observed attack (Fig. 5C), which stopped during his sleep. Although this attack had not lasted long, Fig. 5D, taken on the third day, again showed inversion of T in leads II and III: though this was

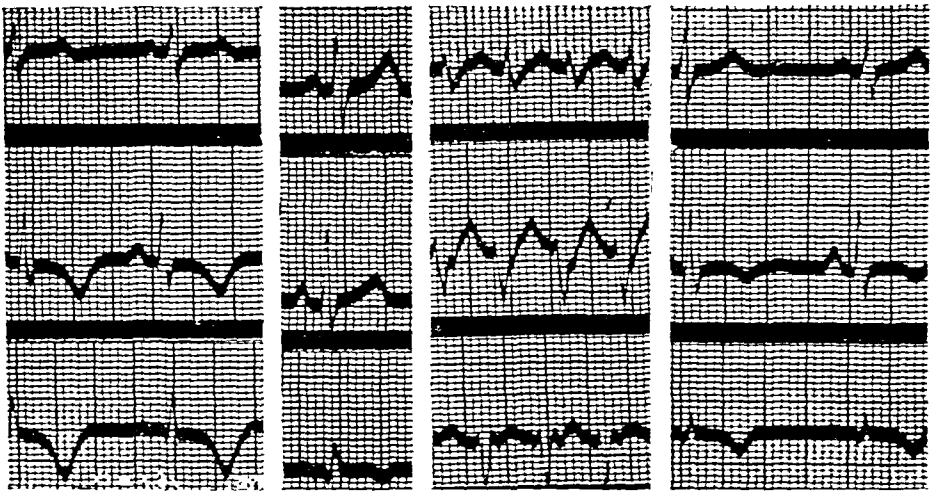

A B C D

FIG. 5.—" Coronary " T wave changes in leads II and III after paroxysms of tachycardia in a healthy young man.

(A) Cardiogram with deeply inverted T in leads II and III, taken one day after a long paroxysm of tachycardia had stopped. Only one dose of 3 grains of quinidine had been taken (16/1/40).
(B) Return to normal, ten days later (26/1/40).
(C) Cardiogram ten days later (5/2/40) of another paroxysm which had stopped spontaneously during the first night.
(D) Recurrent inversion of T in leads II and III, in cardiogram taken on the third day after another attack (8/2/40).

not nearly as deep as after the longer attack (Fig. 5A), possibly because it was after a shorter attack, possibly because it was taken three days instead of one day after, or more probably for both these reasons.

A fourth attack was observed a few days later, after which he remained quite fit and free from any attack for a month.

DISCUSSION

Five cases, two reported previously and three given in more detail here, have been recorded ; in all striking changes in the T waves after paroxysms of tachycardia were suggestive of progressive coronary disease such as cardiac infarction. The first two ultimately died and though all the evidence seemed against it, it may be that they really had organic changes underlying these electrocardiographic changes. It was, therefore, decided to get records in all

possible patients during the period after their paroxysms of tachycardia, and the first two cases, here reported, were two of the first instances found with such T wave changes; in one they had been suspected previously from earlier records, and in the other there was no previous evidence. It was intended to continue the collection of an additional number of cases to obtain some even more satisfactory records, but the onset of the war has prevented me keeping in touch with the necessary number of patients with paroxysms, and as anyone who is working at the subject will realize with such an erratic condition it always takes a long time to get any particular type of observation that one requires. I was, therefore, most grateful to Dr. Parkinson for the last case, for although alone it might not be very convincing owing to the incompleteness of the history and the relatively short time that has passed since the cardiograms were taken, he was an apparently fit young man without other symptoms and the T wave changes after more than one attack were so striking.

It is probable that cardiologists have been generally familiar with the occurrence of such T wave changes after paroxysms, but that they have not obtained enough of such records for publication. Paul White (1941) in a recent article on inversion of the T wave in lead II in various conditions without organic heart disease did not refer to such cases, and it seems, therefore, worth putting on record, partly because of its scientific interest, and partly because of the practical importance that such patients should not be wrongly diagnosed as having organic heart disease because of the temporary T wave changes.

I have no evidence to bring forward as to how these changes are produced. It may be that chemical or other changes in the myocardium as a result of a prolonged attack, are responsible, and in this sense the changes would, to some extent, be a measure as to the severity and seriousness of the attack, and might indicate the need for adequate rest. Another possible explanation is that it depends on changes in the position of the heart, and that as the diaphragm sinks, or as the stomachs empties, the heart returns to its more normal position with the return to its normal electrocardiographic pattern. Although this would bring the cases into line with some of the other T wave changes that have been reported, and admittedly the third of these cases had a mobile heart where changes did influence the electrocardiogram, this explanation seems most unlikely, for one reason because the time taken for recovering from these changes is measured in days rather than hours.

Summary

After long paroxysms of tachycardia the T waves may become inverted in one or more leads for some days. This does not indicate any organic disease, but is a completely reversible process indicating some degree of exhaustion or strain of the heart muscle.

References

Campbell, M. (1939). *Brit. Heart J.*, 1, 123.
White, P. D., Chamberlain, F. L., and Graybiel, A. (1941). *Ibid.*, 3, 233.

A CURIOUS SYNDROME, WITH SIGNS SUGGESTING CERVICAL ARTERIO-VENOUS FISTULA, AND THE PULSES OF NECK AND ARMS LOST

BY

THOMAS LEWIS AND JOAN STOKES

From the Department of Clinical Research, University College Hospital Medical School

Received March 24, 1942

A married woman of 33 years was admitted to hospital on November 25, 1941, complaining of attacks of faintness. She is said to have been rickety as a child and was not allowed to swim at school. After growing up she attended hospital for deafness of her left ear. A doctor examining her in her twenty-sixth year found no pulse at the wrist.

She states that her fainting attacks have been present for about six years and that recently they have become more frequent and now occur almost daily. In the attack her vision becomes dim, she feels weak and would fall without support, but she does not believe she loses consciousness. Her tongue has never been bitten nor her water passed in the attacks. They occur while she is up and about, and also when she is in bed, but especially when she sits up in bed. They are usually followed by headache. She has dropped things from her hand while carrying them, and has collapsed and fallen in the street, but has never hurt herself.

Headaches have been frequent recently; they are severe and felt over the top of the head. She lost the sight of her right eye two years ago in one of her attacks. When scrubbing or doing other hard work she has to stop from time to time owing to aching pain in her arm. Her fingers sometimes become numb and cold without apparent reason.

She has had no children; a pregnancy nine months ago was terminated.

Condition.—She is a small, thin woman (weight, 6 st. 5 oz.). No abnormalities are found in her nervous system, except nerve deafness in the right ear, and a primary optic atrophy in the fundus of the right eye; the vessels of the fundus are normal and there is no exudate. The face is warm and pale and the hands are usually warm and of good colour. Her temperature is usually subnormal; the heart rate varies between 75 and 100 a minute while she lies in bed. Her respirations are 20–24 a minute. The Wassermann and Kahn reactions are repeatedly negative. The blood count is normal. X-rays show no defect in the optic foramina, but the clinoid processes (anterior and posterior) on the right side are eroded.

Heart.—The venous pressure and the venous pulse are normal. The

heart is not enlarged to percussion; the impulse is in the fifth space, 10 cm. from the midline. The sounds are clearly struck and the action regular. The X-ray silhouette, including the arch of the aorta, is normal in outline, but the aortic shadow and that of the basal vessels is rather dense. There is no tracheal tug. The electrocardiogram is normal in its initial phases in all leads.

Arteries and blood pressure.—No pulse can be felt in any artery of either arm, head, or neck. In the neck the pulseless carotid arteries can be felt as unusually firm smooth round cords throughout their length. The innominate vessel can be felt crossing the trachea in the episternal notch; it pulsates palpably though not strongly and is continued into the pulseless carotid vessel. The Pachon oscillometer gives no movement from the upper arms, but the brachial arteries are easily felt as unusually firm round cords throughout their length. The abdominal aorta pulsates freely, the femoral pulses are powerful, and the pulses of the feet are easily palpable, but not waterhammer in quality.

The blood pressure in the popliteal artery, read on a number of occasions, is 210–230 systolic (readings of two years ago were similar) and 130 diastolic. In the arm, blood pressure is obtained by holding the arm aloft for a moment and occluding all circulation by means of the pressure cuff; and then, after an interval of three minutes, allowing the pressure to fall in steps until the hand flushes. Sharp readings can be obtained in this way, showing the mean pressure to be 45 to 55 mm. It can also be shown that the brachial arteries are carrying blood; for if, when the circulation to the limb has been occluded, the brachial artery is firmly gripped and the pressure in the cuff then deflated, reactive hyperæmia is delayed until the brachial artery is released, say fifteen or twenty seconds later, while the hyperæmia occurs in two or three seconds if the brachial artery has not been held. Similarly it can be shown that the subclavian artery is carrying blood; for if the artery is held below the clavicle the colour begins to return only slowly to the hand in five seconds and is full at ten seconds; whereas it returns almost at once if the subclavian artery is free. Compression of the left carotid artery, but not the right, is usually followed by an attack of faintness and pallor, with flushing of the face on release.

Just above the right sternoclavicular joint a systolic thrill and a continuous murmur, louder in systole, are conspicuous. The murmur is heard maximally at the black circle of the diagram, but extends over the whole sternal, supraclavicular, and supracapular regions (cross-hatched area). The systolic thrill is synchronous with the innominate impulse. No unusual pulsation is to be felt in this region. The veins of the neck are inconspicuous and undistended while the patient lies recumbent.

Anastomotic arteries.—A systolic murmur is heard over large areas of the chest and abdominal wall (the hatched areas of the chart). The areas of the systolic murmur are similar to those heard over the anastomotic vessels in coarctation of the aorta, as previously reported (Lewis, 1933). In the present case arterial pulsations are also to be felt in several places on the abdominal wall; one conspicuous pulsation is present to the right of the navel and the systolic murmur is loud here. A faint pulse has been felt at one or two points

on the back of the chest too, and a systolic murmur is audible at the angle of the right scapula. It seems clear that the chief anastomoses unite arteries of the neck and sternal regions, and with especial freedom on the right side, through the epigastric and internal mammary arteries. An indication of the direction of flow in the main anastomotic arteries is obtained by timing the

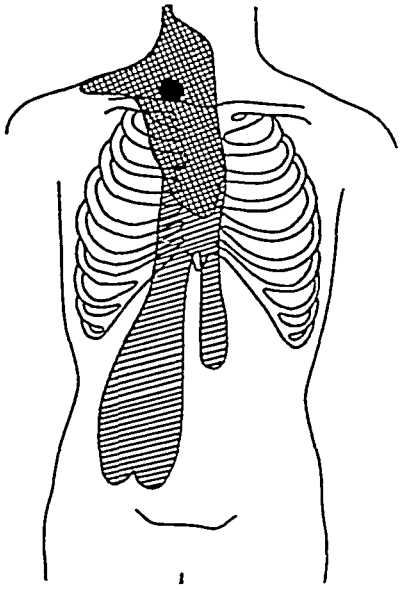

FIG. 1.—Case 1. The area where the systolic murmur could be heard is hatched and the area of the continuous murmur is cross-hatched. The maximal point of thrill is marked by the black circle above the clavicle.

pulsations graphically. The innominate pulse precedes the femoral at Poupart's ligament by about 0·1 sec.; the pulsations of an anastomotic artery near the navel precedes that of the femoral by a little less than this value. Thus the order is innominate, abdominal wall, femoral; closure of the common femoral artery is without effect on pulsations in the abdominal wall. The third and fourth ribs present a few small but unusual crenations of their lower borders.

Renal functions.—The urine is of normal quantity and specific gravity and contains no abnormal constituent. The urea concentration test gives a value as high as 3·09; the urea clearance is 70 per cent of normal, and the blood urea 30 mg. per 100 c.c.

The attacks.—A number of the attacks have been witnessed by her husband, by nursing staff, and by patients in adjoining beds. These attacks are brief, lasting usually ten to twenty seconds, and once about two minutes. Pallor with subsequent cyanosis and noisy breathing are usually noticed. Rigidity, with head retraction, is usual, and unconsciousness not infrequent. Sometimes in the attacks movements of rotation occur in the forearms. In one attack the heart accelerated to 144 a minute, and the patient complained subsequently that her whole right arm had become paralysed for a few moments. Attacks have been provoked by sitting up or kneeling up in bed and leaning over her locker; but the patient always has time to resume the supine position.

Discussion

The patient described presented signs of a very unusual vascular anomaly. No pulsation could be found in either of the carotid or subclavian arteries; the mean blood pressure in the arms was only 50 mm.; and the arms readily developed the ache of muscular ischæmia when used. The patient suffered from frequent attacks of faintness or transient loss of consciousness, and from a unilateral optic atrophy of a few years standing. These evidences all point to a grossly deficient circulation to the head and neck and to the two upper limbs.

The establishment of a great difference between the pressures in upper and lower parts of the body in such a case as this has a clear physiological basis; the low pressure in the upper parts, and presumably in the carotid regions especially, will call forth persistent vasoconstriction, and this will raise the pressure in the lower parts. It is here to be noted that no direct explanation other than the physiological could be found in our patient to explain the raised blood pressure. High pressure in the legs has been recorded in cases of aneurysm with pulseless upper parts by Maurer (1939), Kampmeier and Neumann (1930), and Cohen and Davie (1933). Thus our case in following physiological expectation appears to conform to a rule.*

The aorta itself was unchanged in form and size, its ascending and transverse parts being clearly visible in the X-ray, and the pulse being transmitted without undue delay to the femoral arteries. A pulsation, promptly delivered from the heart, was readily felt in an artery that was regarded from its size and position as the innominate, at the root of the neck; this vessel could be traced upwards into the firm non-pulsating cord of the right carotid. The deficient circulation to the upper parts of the body was manifestly due to an impervious condition, relative or absolute, of subclavian and carotid arteries on both sides.

In most of the instances of lack of pulsation in both carotids and subclavians previously recorded, the patients have been proved to be syphilitic, and those coming to post-mortem examination have been cases of aneurysm of the aorta, the obstruction being due to clot extending into and plugging the mouths of the arteries arising from the arch of the aorta, or to closure of these mouths by sclerosis. Such an explanation is not open to us in the case of a young woman, giving repeatedly negative Wassermann and Kahn reactions,

* Such conformity re-emphasizes the curious blood pressure picture in cases of coarctation of the aorta. The condition as a whole might be likened to one of inverted coarctation of the aorta in its effects on the general pressures. Giffin and Dill have already drawn this analogy in the description of a not dissimilar case.

In 1933 the blood pressure readings from previously recorded cases of coarctation of the aorta were collected for the first time, and to these were added those from eight newly recorded cases (Lewis, 1933). From this material it was possible to conclude that high blood pressure in the upper parts of the body is the rule in these cases, while low pressure prevails in the lower parts. It could not be overlooked that the high pressure in the upper half of the body might be due to a mechanism set in motion by the need of the lower part of the body, but, when examined, the nature of this mechanism remained, and still remains, obscure. Goldblatt, Kahn, and Hanzal (1939) have since shown that clamping the abdominal aorta just above the renal arteries causes a delayed hypertension to develop, as a result of renal ischæmia. Possibly a similar mechanism applies to coarctation, though the freedom of anastomoses and the infrequency of renal insufficiency in these cases is to be noted.

and presenting under X-ray no trace of aortic dilatation or distortion. Giffin (1939) in describing a case very similar to the present one, a woman of 19 years, was for similar reasons precluded from assigning it to syphilis; and consequently in the discussion of his case, a congenital anomaly of arteries was suggested as the possible basis of the lesion. It is but a suggestion, for no such anomaly is known in which all of the three usual vessels, innominate, subclavian, and carotid, fail; or which would account for loss of pulses in head, neck, and arms. We may place the argument on more general lines. When a usual artery, such as those named, fails to arise from its accustomed parent stem, it arises from some other source. *The congenital anomalies of arteries are not suppressions of arterial supply, they are merely unusual arrangements of supply.* In thinking of a developmental failure of arterial supply, it is to be remembered that the first arrangement of main arterial paths is determined at an early stage of uterine life, at a time when the limbs have still to make the great bulk of their growth. That adequate arterial development should fail while the tissues and structures of the corresponding territory continue to develop normally from this early stage is inconceivable. The evidence from our patient is of a gross defect of circulation to the head and limbs. To account for this state an anomaly of development would be, by itself, an inadequate explanation.*

It would seem necessary to adopt an explanation embracing an acquired lesion. The nature of the acquired lesion remains obscure; a chief clue to it being the remarkable cord-like condition of the main arteries in the neck and arms, already described. Extensive thrombosis might be expected to have produced at the time sudden and emphatic cerebral symptoms; it might also be expected to have rendered the vessels concerned quite impervious; yet as we have seen the brachial arteries and probably the left carotid, though greatly thickened, were not impervious. A dissecting aneurysm spreading to the basal vessels is a possible explanation, but there is no definite support for the suggestion.

In searching for an interpretation of this curious case there is another feature which stands out and calls for explanation, namely, the continuous murmur and thrill at the base of the neck. It is such a murmur and thrill as is known to occur only where a main artery is in communication with another vessel under much lower tension. Simple anastomoses are not known to give continuous murmurs. Although an arteriovenous fistula is the most probable explanation, yet it may be objected that increased pressure in the veins of the neck, and a steep-rising pulse in the legs, would be expected in association; neither of these phenomena occurred. Such a fistula can by no means be excluded, however, since it may have been deeply seated, as in the bones of the vertebræ or skull; no evidence in support could be found in X-ray pictures of the neck, though the sella turcica was seen to be malformed, the clinoid

* Coarctation of the aorta cannot legitimately be cited in the contrary sense, for this defect is not supposed to occur by failure of development, but by some form of interference, at or about the time of birth, causing the already open aorta to close down in the region of insertion of the ductus arteriosus.

processes being small and obscure. No murmur could be heard over the head. The anastomosing vessels in the case are more consistent with the idea of an arterio-venous fistula than with that of a purely obstructive lesion necessitating collateral supply of the head and arms from the lower parts of the body. As has been seen, the collateral channels did not lead upwards through epigastric and internal mammary from femoral to supraclavicular region.

A point upon which considerable emphasis is to be laid is that Giffin's case, so like ours in other respects, also presented a continuous thrill in a similar situation. So did a patient whom we saw many years ago. This was a young woman, the pulse in whose neck was absent or almost imperceptible. The Wassermann reaction was negative, but the aorta was definitely dilated. This case is of special interest in that the blindness was known to have resulted from a recent obstruction of the central artery of the retina. The notes of this case, imperfect though they are, and an abstract of Giffin's case are appended. Here then are three cases of very similar type, and all presenting a similar murmur. The fact suggests that we are dealing with a pathological entity hitherto unrecognized and still awaiting post-mortem dissection before its precise form can be understood.

Appended Notes of Another Case

Case 2. A housewife of 45 years was admitted to hospital in the autumn of 1932, complaining of attacks of faintness, and blindness of the right eye. She also suffered at this time from bronchitis. There was a history of rheumatic fever at 8 years and of white leg and varicose ulcers following pregnancy. She was the mother of seven children, five alive and well. One child came prematurely and died, and one died at fourteen months from rickets and pneumonia.

In March 1931, when in hospital for pregnancy, it was found that pulsation in her radial and carotid arteries was much diminished; this was the first record of any abnormality of her vascular system. The fainting attacks began during pregnancy in 1930 and occurred about once in five weeks; they were usually provoked by sitting up in bed in the morning and were also brought on by stooping. They comprised mistiness of vision, dizziness, and weakness in the left arm, followed by numbness and tingling and often by severe headache. Consciousness was not lost. The blindness came suddenly during an attack of " influenza."

Condition.—She was a healthy-looking and well-nourished woman (weight, 11 st. 5 lb.). Her colour was good and her hands and face warm. Her temperature was usually subnormal and her heart rate varied while she was in bed from 68–84 a minute. There were no abnormal signs in her central nervous system and the loss of vision in the right eye was stated by Mr. H. Neame to arise out of recent obstruction of the retinal artery. The retina was pale and œdematous, especially at the macula, which presented a bright red spot; the arteries were very thin and of irregular lumen, the veins smaller than normal;

the œdema subsided subsequently. Her Wasserman reaction was found negative on two occasions.

Heart.—Venous pulsation and pressure in the neck were normal, and the heart was not enlarged. Some retrosternal dulness and pulsation could be seen in the third right space during full expiration. There was no pulsation of the sternum and no tracheal tug. X-ray of the chest confirmed that the

FIG. 2.—Case 2. Antero-posterior radiogram of the chest, taken on October 12, 1932.

heart was normal in size and showed a diffuse dilatation of the aortic arch and a shadow running from the arch of the aorta, parallel to the right border of the sternum to the region of the sterno-clavicular joint, presumably a dilated innominate vessel (see Fig. 2). There was no notching of the ribs such as is seen in cases of coarctation of the aorta. The electrocardiogram was normal.

Arteries and blood pressure.—In the right radial artery only a flicker of pulsation could be felt. The right brachial and carotid, and the left radial, brachial, and carotid arteries were not felt to pulsate.

Both femoral arteries presented a strong but rather slow-rising pulse, and pulsation in the dorsalis pedis arteries was easily felt. A murmur was heard maximally at the base of the neck in the angle between the right sterno-mastoid muscle and the clavicle. It was loudest in systole and prolonged almost or quite into diastole, resembling to several observers the murmur of a patent ductus arteriosus. It was conducted up the neck as far as the angle of the jaw on the right, and a little way up on the left, down the right border of the sternum as far as the fourth space, and over the manubrium. A thrill, localized at the base of the neck, accompanied it, but there was no pulsation in this region. An unexplained systolic murmur was also heard below the angle of the left scapula; it is not clear that any other signs of anastomoses were sought. The Pachon oscillometer reading showed small pulsations from both arms. The maximal pulsation occurred at 60 mm. in the arm and at 100 mm. in the leg. The systolic blood pressure in the legs varied between 130–150 mm.

When the patient was previously admitted in March 1931, her signs were a little different. At that time very slight pulsation was felt in both radial and carotid arteries and the blood pressure in the arms was recorded at 70 to 80 mm. Dilatation of the aorta, as revealed to X-ray, was then not quite so great. Vision at this time was good and the fundus oculi was normal on both sides.

The urine contained neither blood nor albumin; renal function tests were not done.

Abstract of Dr. Giffin's Case

Case 3. A woman, aged 19, came to hospital in December 1938 because of headaches and failing vision.

In the spring of 1938 she began to have attacks of blurred vision lasting for one or two minutes. These episodes increased in frequency until August 1938, when she was confined to bed. Since then she had returned to limited activities and could read except during daily transitory attacks. Her sight was poorest on rising and improved during the day. She also complained of bilateral frontal headaches for several years and occipital headaches intermittently for nine months. Vomiting had occurred occasionally. The family history was not significant. She was normal at birth but was weak and under-developed in childhood. Later, owing to weakness, she was never able to do housework. Her hands and jaws fatigued easily and she had always been pale.

Condition.—The patient was mentally retarded and physically under-developed. Her central nervous system was normal. Her face and mucous membranes were pale.

Pulsation could not be felt in the left radial, brachial, subclavian, or carotid arteries. It was also absent in the right radial, brachial, and subclavian arteries, but in the right carotid artery diminished pulsation with a slight thrill was felt at the level of the cricoid cartilage, and a loud continuous bruit was heard

at this point. Photographic record of the murmur showed that it was continuous throughout the cardiac cycle, and it was thought to indicate the presence of arterio-venous fistula. Pressure medial to the right carotid artery, however, stopped the murmur without significant alteration in the heart rate. The pulsation of the abdominal aorta and its branches was somewhat increased. In the legs oscillometer excursions were normal and the blood pressures varied from 175–190 systolic and 90–110 diastolic. Skin temperatures of the fingers of both hands were consistently lower than those of the toes.

The heart was normal in size. A systolic murmur maximum in the second left interspace was heard and the pulmonary second sound was accentuated. X-ray revealed a relatively small heart, the absence of an aortic knob, and a prominent pulmonary conus. There were no cervical ribs, no rib notches, and no bony erosion in the cervical region. Radiograms of the skull were normal. The electrocardiogram revealed nothing diagnostic and the Wassermann reaction was negative.

Examination of the ocular fields showed an " upper altitudinal " scotoma on the left. Vision was 6/30 in the left eye and 6/10 in the right eye. There was no papillœdema. Fragmentary flow of blood was seen in the retinal veins and also several ischæmic areas were found. Retinal pressures, measured by an indirect method were found to be less than 20 mm. of mercury on the right and were unobtainable on the left.

Summary

A patient is described in whom the pulses of the neck and arms had been lost, and who presented signs suggesting an arterio-venous fistula at the root of the neck. The defective blood supply to the upper parts of the body was responsible directly or indirectly for a gross defect of vision, for frequent fainting attacks and headaches, and for pain in the right arm during work. The blood pressure in the patient's legs was raised.

Another case of a very similar kind is described, and a third recorded by Giffin is compared with them.

The three cases show so much in common as to suggest a pathological entity hitherto unrecognized and still awaiting dissection before its precise form can be understood.

References

Cohen, H., and Davie, T. B. (1933). *Lancet*, **1**, 352.
Giffin, H. M. (1939). *Proc. Staff Meet. Mayo Clinic*, **14**, 561.
Goldblatt, H., Kahn, J. R., and Hanzal, R. F. (1939). *J. exper. Med.*, **69**, 649.
Kampmeier, R. H., and Neumann, J. F. (1930). *Arch. intern. Med.*, **45**, 513.
Lewis, T. (1933). *Heart*, **16**, 205.
Maurer, E. (1939). *Amer. Heart J.*, **17**, 716.

THE CONDUCTING SYSTEM OF THE VERTEBRATE HEART*

BY

FRANCIS DAVIES

From the Department of Anatomy, University of Sheffield

Received April 24, 1942

A study of the comparative anatomy of the conducting system of the vertebrate heart reveals that the phylogenetic evolution of this system affords a further illustration of the dictum on the close correlation between form and function enunciated by John Hunter. My present thesis is this. A cardiac conducting system, consisting of specialized muscle (i.e. nodal tissue and Purkinje fibres), is limited to mammals and birds. The general topography of this system is closely similar in these two classes of warm-blooded vertebrates; the main differences can be correlated with different functional requirements. This system is a neomorphic development; it is not a "remnant" of more extensive tissues of similar structure in lower vertebrate hearts. The system has undergone parallel evolution in mammals and birds in response to functional requirements. The evidence in support of this thesis may be briefly summarized as follows.

MAMMALS

The sinu-atrial (S-A) node, the site of initiation of the impulse for cardiac contraction (pace-maker), was originally described by Keith and Flack as lying superficially beneath the epicardium in the upper part of the sulcus terminalis, adjacent to the end of the superior vena cava. Subsequent studies have shown that the node is a much more extensive structure, being horse-shoe shaped, and embracing the ventral aspect of the end of the superior caval vein, the anterior limb of the horse-shoe extending caudally over more than the upper half of the sulcus terminalis (Fig. 1). Moreover, the node extends through the entire thickness of the atrial wall, from epicardium to endocardium. Some investigators have claimed that, after removal of the entire node, normal cardiac rhythm is maintained; they have therefore postulated the existence of other (ectopic) centres in the atria with the same rhythmic properties as the node. Owing to the difficulty of complete removal of this extensive node, and since even a small portion of nodal tissue left behind will be capable of initiating atrial contraction, the validity of such experimental work, not subejcted to strict histological control, is open to serious question.

* Abridged form of the Hunterian Lecture delivered at the Royal College of Surgeons of England, February 9, 1942.

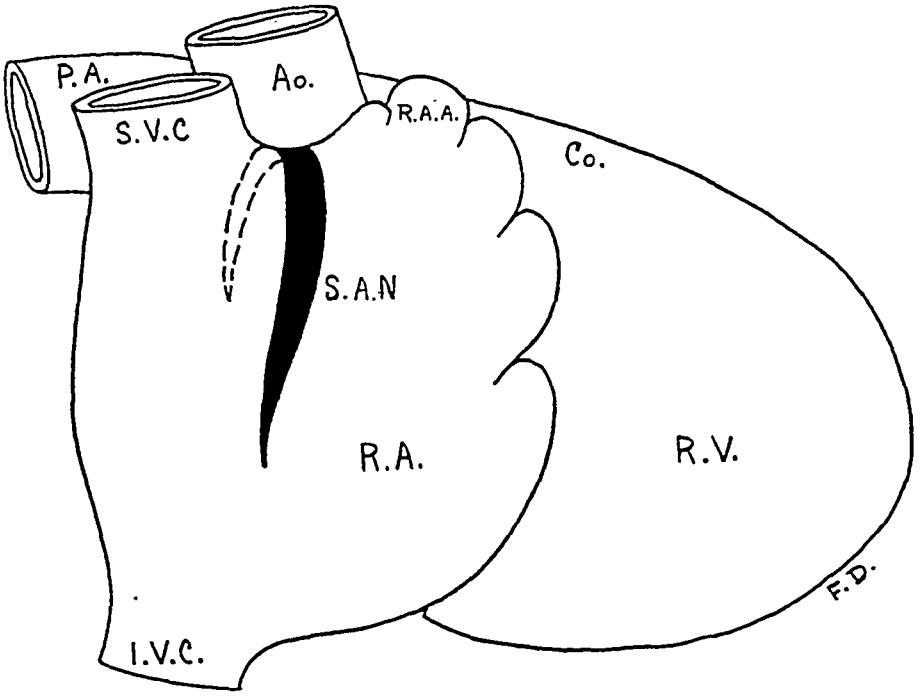

FIG. 1.—Extent of the S-A node in the mammal.

Ao., aorta; Co., conus arteriosus; I.V.C., inferior vena cava; P.A., pulmonary artery; R.A., right atrium; R.A.A., right atrial appendix; R.V., right ventricle; S.A.N., sinu-atrial node; S.V.C., superior vena cava.

The node was described by its discoverers as a plexiform mass of peculiar pale-staining fibres intermingled with connective tissue and nerves; they considered this tissue to be intermediate in structure between nerve and muscle, and therefore gave it the non-committal name of "nodal tissue." Silver impregnation methods clearly reveal, however, that the nodal fibres are specialized cardiac muscle fibres; they are completely cross-striated, fusiform, and branched, their chief distinguishing character being their small breadth in comparison with the ordinary atrial muscle. This is one of the features to be correlated with the special properties of the node, namely its greater rhythmicity and slower rate of conduction than ordinary heart muscle. These nodal fibres are directly continuous with the neighbouring myocardial fibres of the right atrium; the latter are continuous with those of the left atrium; the cardiac impulse is thus transmitted through the atria by the ordinary cardiac muscle and reaches the atrio-ventricular node, whose specialized fibres are continuous with the myocardial fibres of both atria in the atrial septum.

A few observers have described a direct connection, by means of nodal tissue or Purkinje fibres, between the S-A and A-V nodes; most workers have failed to find such. Many investigators have noted the presence of typical large Purkinje fibres beneath the endocardium in both atria. From their descriptions these appear to be isolated collections of Purkinje fibres, unconnected with either the S-A or A-V node; moreover, the sites at which they have been found

vary with the observers. We ourselves have seen a small collection of Purkinje fibres beneath the epicardium in the right atrium of the ox heart, which was continuous with the caudal end of the S-A node. It is probable that these conditions should be regarded as "variations," such as would be prone to occur in a newly evolved system.

The atrio-ventricular (A-V) node, smaller than the S-A node, is situated in the lower and dorsal part of the atrial septum, with whose musculature the special nodal fibres are continuous. The node is directly continued into the A-V bundle, which runs along the upper border of the ventricular septum to the lower edge of the pars membranacea septi, and there bifurcates into right and left limbs, the bifurcation straddling the upper border of the muscular part of the septum. The right limb runs down, in the form of a round bundle, on the right side of the septum, covered over by the endocardium and a thin layer of septal myocardium, making for the septal attachment of the "moderator band." The latter in most cases conveys the right limb across the ventricular cavity to the base of the anterior papillary muscle, where the limb divides into a plexus of Purkinje fibres which ramify beneath the endocardium throughout most of the right ventricle. Very rarely, the right limb passes from the septum to the opposite wall of the ventricle independently of the "moderator band," a feature that may be attributable to variation. The left limb, in the form of a broad flattened band, descends beneath the endocardium on the left side of the septum and, at a varying distance down the septum, divides into two or more branches, each of which, after a short course down the septum beneath the endocardium, subdivides into a number of branches. These latter are conveyed by the trabeculæ carneæ and the "false tendons" across the cavity to the papillary muscles on the opposite wall, there dividing into a plexus of Purkinje fibres which ramify beneath the endocardium throughout most of the left ventricle.

The A-V node, the A-V bundle and its limbs, together with the subendocardial Purkinje plexuses are surrounded by a fibrous sheath, which both mechanically protects the relatively (but not absolutely) stationary specialized elements from friction against the vigorously contracting ventricular myocardium, and also *insulates* them from the neighbouring cardiac muscle. Into the potential space between the sheath and the specialized muscle, fluids like indian ink can be injected, and the whole ventricular ramifications of this system can thus be readily and rapidly displayed. This method cannot be successfully employed in the human, because the sheath is extremely thin and ruptures with very slight increase in pressure, allowing the injection fluid to diffuse beneath the endocardium. Until recently, the subendocardial Purkinje fibres were thought to become continuous with the ventricular muscle immediately adjacent, which latter would thus convey the cardiac impulse through the thickness of the ventricular walls: but they themselves have now been shown (in a number of mammals) to penetrate throughout the entire thickness of the ventricular walls, including the septum, surrounded by their fibrous sheath, and to become continuous with the ordinary muscle at various depths from the surface; many of them penetrate the walls in relation to the branches of the coronary arteries.

It may be observed that this discovery was made subsequent to the demonstration of a similar, but more widespread, penetration of Purkinje fibres in both ventricles and atria in the bird's heart. In the human, the ventricular Purkinje fibres are limited to the subendocardial plane. The Purkinje fibres that penetrate into the ventricular septum from the subendocardial plexuses on either side, communicate in the substance of the septum. Thus after damage of the upper part of the right limb of the A-V bundle for instance, the impulse can pass down the intact left limb, through these communicating septal Purkinje fibres to the right ventricle, reaching the latter after a delay that is very slightly greater than normal.

The discoverers of the S-A node remarked on its close similarity in histological structure to that of the A-V node, and it appears to have been generally accepted that the two nodes are identical in structure. The specialized muscle fibres of the A-V node, however, while completely cross-striated and more slender than the ordinary heart muscle, differ from those of the S-A node in being more cylindrical, more branched, and broader. These are some of the differences, to which may be attributed a probable lower rhythmicity than the S-A node and the fact that the cardiac impulse normally originates in the S-A rather than the A-V node.

In most mammals the A-V bundle and its two limbs consist of typical large Purkinje fibres. In the human, however, the fibres of the A-V bundle and of the proximal parts of its two limbs closely resemble the ordinary ventricular muscle fibres, as revealed by ordinary laboratory stains; in fact, the bundle fibres are slightly narrower than the myocardial fibres, and it is not until some distance down the septum that the typical large Purkinje fibres make their first appearance in the limbs. The pathologist may have difficulty in identifying these structures in isolated sections of the human heart; tracing continuity in serial sections is the only certain means of identifying them. The nodes, bundle, limbs, and terminal Purkinje fibres are accompanied by nerves, and numerous nerve cells are closely related to the nodes and bundle; these neural elements are capable of altering the degree of activity of the specialized conducting muscle under varying conditions. Although Kent described "accessory muscular connections" between the atria and ventricles in some mammals (rat and young rabbit; to a lesser extent, guinea-pig and hedgehog; very few in monkeys), the general opinion is that the A-V bundle constitutes the sole muscular A-V connection in higher mammals.

Birds

The bird's heart resembles that of the mammal in being four-chambered, with complete atrial and ventricular septa. The heart rate, however, is considerably faster than that of a mammal of approximately the same size, and the necessity arises therefore for a more rapid spread of the cardiac impulse throughout the entire avian heart. Although Keith, Mackenzie, and others denied the existence of specialized nodes and bundle in the bird's heart, it has been shown (Davies) that not only are such structures present, but that the specialized conducting muscle is more widely distributed in the avian than in

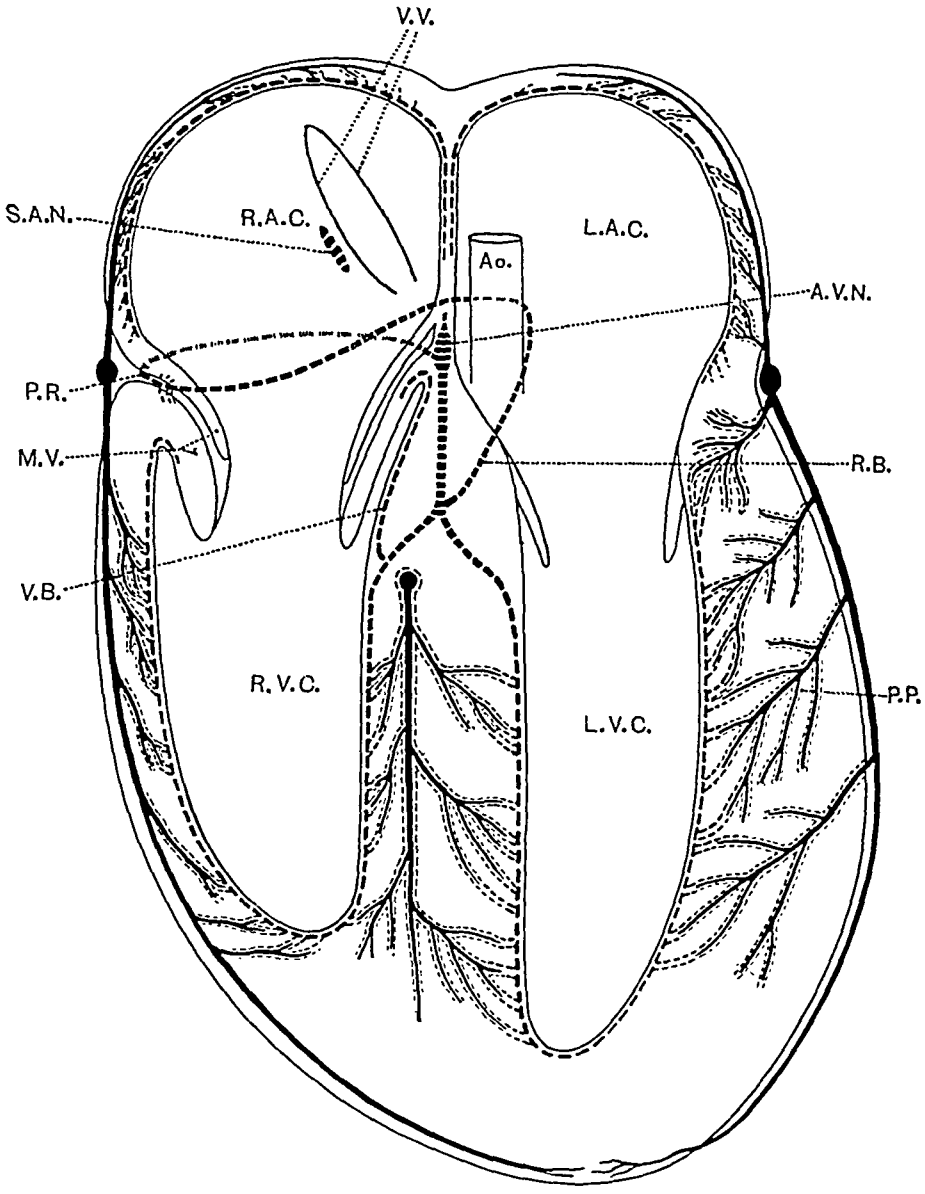

FIG. 2.—Diagram summarizing the main topographical disposition of the avian conducting system. For abbreviations see Fig. 3.*

the mammalian heart, and this latter is to be correlated with the need for more rapid diffusion of the impulse, as indicated above.

The S-A node, similar in structure to that of the mammal, lies on the right side of the entry of the right anterior vena cava into the right atrium, and extends throughout the entire thickness of the atrial wall. Unlike the mammal, however,

* I am indebted to the Editors of the *Journal of Anatomy* and to the Council of the Royal Society for permission to reproduce Fig. 2 and 3 respectively.

the nodal fibres are continuous with large Purkinje fibres, which ramify beneath the endocardium throughout most parts of the right and left atria, and penetrate the atrial walls to become continuous with the ordinary atrial muscle, but are absent from the lower part of the atrial septum, so that, as in the mammal, the specialized fibres of the A-V node establish continuity with the ordinary cardiac muscle of the atrial septum.

The A-V node is similar in structure and position to that of the mammal and is continued directly into the A-V bundle. The latter, unlike the mammalian bundle, runs caudally and ventrally into the depth of the ventricular septum, lying approximately midway between its right and left surfaces. About one quarter of the way down the septum, the bundle divides into right and left limbs; these approach the corresponding sides of the septum and there divide into a plexus of Purkinje fibres, which ramify beneath the endocardium throughout most of the ventricular chambers, also penetrating through the thickness of the ventricular walls, mostly in relation to the coronary vessels, and becoming continuous with the ordinary ventricular muscle at varying depths from the surface. In the septum, as in the mammal, communications are established between the Purkinje fibres derived from the subendocardial plexuses on either side.

The difference in position of the mammalian and avian bundle in relation to the ventricular septum can be explained by the difference in the morphology of the septum in these two classes of warm-blooded vertebrates. The A-V bundle and its two limbs in the avian heart consist of large typical Purkinje fibres. A striking example of the effect that functional requirement exerts on the topographical distribution of the conducting elements is seen in relation to the right A-V valve in the bird. In the mammal the tricuspid valve is a fibrous structure and closes passively by the pressure of the blood on its under surface during ventricular systole. In the bird this valve is a strong muscular structure, consisting mainly of an inflection of the base of the ventricle, covered on its inner surface by a thin prolongation of the atrial muscle, the epicardial connective tissue in the coronary sulcus being invaginated between the two. It is necessary that this muscular valve should contract actively at the outset of ventricular systole, and to this end early outgoing branches of the conducting system to the valve are present in the form of the right A-V ring of Purkinje fibres from the A-V node, which runs partly round the A-V orifice in the connective tissue of the valve, and an early branch from the right limb of the A-V bundle (see Fig. 2).

In the main then, the specialized conducting systems of mammalian and avian hearts are closely similar; differences can be correlated with different functional requirements.

Lower Vertebrates and the Phylogeny of the Conducting Systems of Mammalian and Avian Hearts

A number of workers, in particular Keith and Mackenzie, maintain that the nodes and A-V bundle of the mammal are remnants of more extensive tissues of similar structure in lower vertebrates. Thus, in the heart of the fish they

describe a ring of nodal tissue at the junction of sinus venosus and atrium, in the base of the venous valves, and a similar ring at the junction of atrium and ventricle. To these nodal rings are attributed a greater rhythmicity and a slower rate of conduction of the cardiac impulse than the ordinary cardiac muscle; the latter property being responsible for the delay in the passage of the impulse from one cardiac chamber to the next: this delay is necessary in order that the chamber receiving blood may become completely filled before it in turn begins to contract. Keith and Mackenzie maintain that as one ascends the scale of animals the concentration and reduction of this tissue becomes more marked. Such concentration is already present in amphibia and becomes more marked in reptiles, in which the S-A ring is reduced to a collection of nodal tissue on the left side of the sinu-atrial junction. In mammals, associated with the development of fibrous rings separating the atrial from the ventricular musculature, the A-V ring of nodal tissue is reduced to the A-V node and A-V bundle, while the S-A nodal ring is concentrated to the S-A node.

Recent detailed examination of the heart of the spotted salamander (Davies and Francis) has thrown doubt upon this interpretation of the phylogenetic origin of the specialized conducting tissue of the mammalian (and avian) heart. This animal, a caudate amphibian, has a very primitive form of heart (Fig. 3), suitable for comparison with those of fish on the one hand and those of reptiles, birds, and mammals on the other. In it the four primary chambers (sinus, atria, ventricle, and bulbus) are well defined separate structures. No specialized muscle (i.e. nodal tissue or Purkinje fibres) is present in any part of this heart, either in the walls of the chambers or at the sites of junction of the several chambers. The cardiac muscle has the same histological structure throughout, as revealed by staining with hæmalum and eosin, Van Gieson and iron hæmatoxylin, and with Bodian activated protargol techniques. The arrangement of the muscle fibres, however, is noteworthy. With the exception of the bulbus, in which the cardiac muscle is circular throughout, the musculature of the chambers is arranged in a basket-work fashion.

At the sinu-atrial, atrio-ventricular, and ventriculo-bulbar junctions, however, the muscle fibres become abruptly changed to a circular arrangement, the sudden change in direction being a striking feature at each of the junctional sites. In each of these rings (of ordinary cardiac muscle) the fibres branch, the branches connect with the adjacent fibres, and this has the effect of converting these morphological rings into physiological spirals. The time taken by the cardiac impulse to traverse these spirals will, we believe, account for the delay in the passage of the impulse from one chamber to the next, without postulating the existence of special nodal (or block) fibres at these junctional sites. The analysis of superimposed tracings of the outlines of the heart of the salamander, made from slow-motion cinephotographic records of the normally beating heart, enables the course of the wave of contraction and the phases of a complete cardiac cycle to be determined. Such records indicate that the phases of the cardiac cycle in the heart of the salamander are similar to those of the mammalian heart. While similar detailed study of the hearts of fish (eel, gurnard), amphibia (frog) and reptiles (tortoise, Mississippi alligator, Sphenodon) still

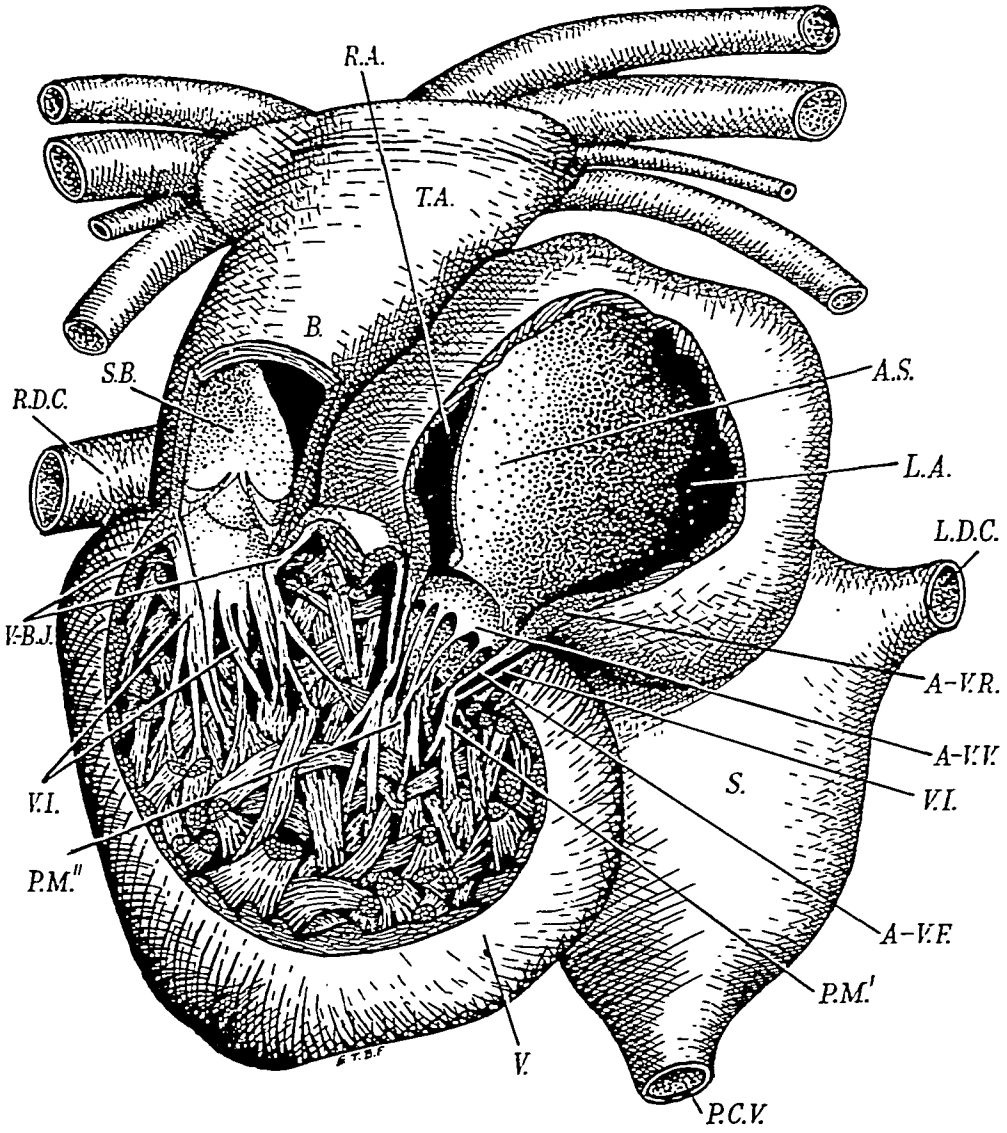

FIG. 3.—Dissection of the salamander's heart, showing atrio-ventricular and ventriculo-bulbar junctions.

A., atria; Ao., aorta; A.S., atrial septum; A-V.F., atrio-ventricular funnel; A-V.J., atrio-ventricular junction; A-V.N., atrio-ventricular node; A-V.R., atrio-ventricular ring; A-V.V., atrio-ventricular valve; B., bulbus; Co., conus arteriosus; I.V.C., inferior vena cava; L.A., left atrium; L.A.C., left atrial cavity; L.D.C., left duct of Cuvier; L.V.C., left ventricular cavity; M.V., muscular valve; P.A., pulmonary artery; P.C.V., post-caval vein; P.M.' and P.M.'', papillary muscles; P.P.F., penetrating Purkinje fibres; P.R., right A-V Purkinje ring; R.A., right atrium; R.A.A., right atrial appendix; R.A.C., right atrial cavity; R.B., recurrent branch of A-V bundle; R.D.C., right duct of Cuvier; R.V., right ventricle; R.V.C., right ventricular cavity; S, sinus; S-A.J., sinu-atrial junction; S-A.N., sinu-atrial node; S.B., septum bulbi; S.V.C., superior vena cava; T.A., truncus arteriosus; V., ventricle; V.B., branch of right limb of A-V bundle to muscular valve; V-B.J., ventriculo-bulbar junction; V.T., ventricular trabeculæ; V.V., venous valves. (Abbreviations for Fig. 2, 3 and 4).

await completion, preliminary inspection of sections of these has failed to reveal the presence of nodal tissue or Purkinje fibres in any part of these hearts.

The conclusion is thus reached that the nodes and A-V bundle (together with its two limbs and the terminal subendocardial and penetrating Purkinje fibres) in the hearts of mammals and birds are neomorphic developments, which have undergone parallel evolution in association with the more rapid rate of the heart in proportion to its size, in these homoiothermal vertebrates. The heart rates of the frog, mouse, and canary are roughly 30 (at 15° C.), 700, and 1000 beats a minute respectively. These hearts are approximately of the same size and the cardiac impulse has therefore to be propagated throughout the heart more rapidly in the mouse than the frog, and more rapidly still in the canary. It might be expected that, whereas the ordinary cardiac muscle may be capable of conducting the impulse rapidly enough in the frog, special tissue which can conduct the impulse much more rapidly might be developed in the mouse and canary, and that this tissue would probably have a more extensive distribution in the bird than in the mammal. Such has been shown above to be the case.

When the sinus, atria, ventricle, and bulbus of the frog's heart are separated from each other by cuts made accurately through the junctions of these chambers, it is found that rate of rhythmic contraction of these chambers diminishes progressively from sinus to bulbus. In the absence of histologically specialized muscle, no satisfactory explanation of this difference in the intrinsic rhythmic rates of the several cardiac chambers has been advanced. Recent estimations of the relative glycogen content of the muscle fibres of these chambers have been made by staining sections with carmine, tracing the outline of the (highly magnified) fibres on squared paper and plotting in the red-stained glycogen. The glycogen is found to increase progressively from sinus to bulbus (Davies and Francis, 1941) (Fig. 4). This order of increase is the same as that of the density and compactness of the cardiac musculature and of the work done by the several chambers, so that a positive correlation in this respect may be made, the glycogen possibly being a source of energy for the work of contraction. But the intrinsic rhythmicity diminishes in this order; whether this relation is merely coincidence or indicates a causal relationship remains to be determined. In the mammal, the nodes are particularly poor and the Purkinje fibres rich in glycogen in comparison with the ordinary cardiac muscle. The glycogen content of the muscle fibres at the S-A and A-V junctions of the frog's heart is intermediate between that of the muscle fibres of the adjacent chambers, and this may be taken as collateral supporting evidence that this junctional muscle is not the same as the nodal tissue or Purkinje fibres of the mammal.

Further collateral evidence that the nodes and bundle of the mammal are newly evolved structures is afforded by a study of their ontogeny in the calf heart. Shaner found that, in the 9 mm. calf embryo, the A-V node appears behind the dorsal endocardial cushion and from it the A-V bundle grows on the top of the ventricular septum. At this time the developing musculatures of the atria and ventricles are continuous round the coronary sulcus. The A-V node and bundle thus appear and grow like any other embryonic organ

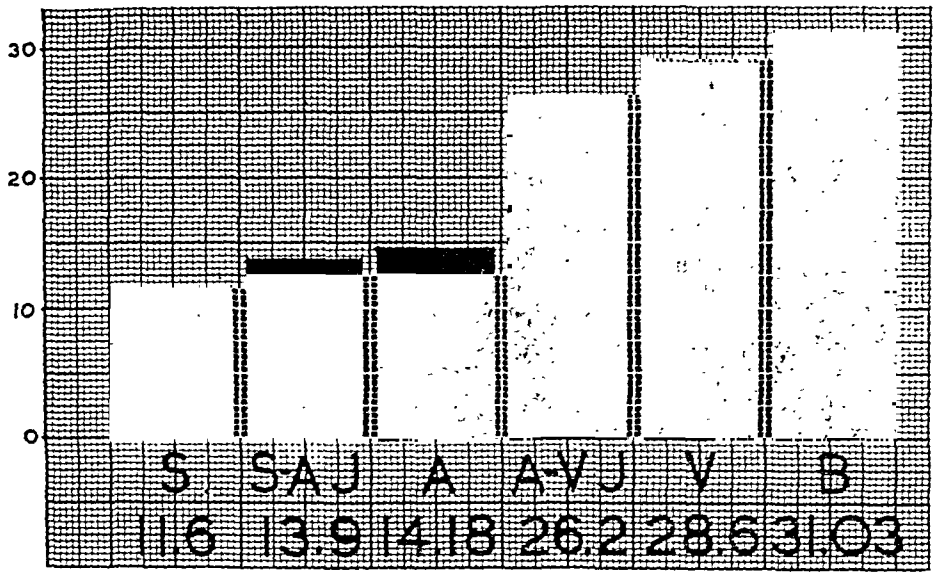

FIG. 4.—Glycogen content of the frog's heart. The relative amounts of glycogen in the muscle fibres of the cardiac chambers has been estimated graphically from sections stained by Best's alkaline carmine.

and are not remnants of more extensive tissues connecting the atria and ventricles at an earlier stage of embryonic life. Similar remarks apply to the appearance of the S-A node at a later date (100 mm.).

SUMMARY AND CONCLUSIONS

1. The specialized muscle fibres comprising the conducting system of the hearts of mammals and birds include S-A node, A-V node, A-V bundle and its two limbs, and terminal ventricular subendocardial and penetrating Purkinje fibres. Added to these in the bird's heart are the atrial subendocardial and penetrating Purkinje fibres, the right A-V ring, and the special branch of the right limb of the A-V bundle to the muscular A-V valve.

While the main topography of this system is similar in mammals and birds, differences are correlated with functional requirements.

2. The specialized cardiac conducting system of these homoiothermal vertebrates is not a remnant of more extensive tissues of similar structure in lower vertebrate hearts. It is a neomorphic development, associated with the more rapid rate of the heart (more rapid, in proportion to its size). Ontogenetic development of these structures in the mammal (calf) supports this view.

3. In a lowly generalized vertebrate heart (Salamander) no specialized tissue is present. The sequences of the cardiac cycle are similar to those of the higher vertebrates. Each chamber has its own intrinsic rhythmic rate, the reason for which is not clearly established. The glycogen content of the musculature of the heart of the frog, which is also devoid of specialized tissue, is inversely proportional to the intrinsic rhythmic rates of the several chambers.

4. In mammals and birds, parallel evolution of the specialized conducting system has taken place; small differences in the topography of the specialized conducting fibres in closely allied species, or in different animals of the same species, may be attributed to variation.

References

In this brief survey no attempt is made to incorporate all revelant bibliographic references, which will be found in the works cited below.

Blair, D. M., and Davies, F. (1935). *J. Anat., Lond.*, 69, 303.
Davies, F. (1930). *Ibid.*, 64, 129 and 319; and (1931), 65, 339.
—— and E. T. B. Francis (1941). *Phil. Trans. Roy. Soc.*, B., No. 578, 231, 99.
—— —— (1941). *J. Physiol.*, 100, 329.

THE SINO-AURICULAR NODE:
A HISTORICAL NOTE

CONTRIBUTED BY

ARTHUR KEITH

The Editors of the *British Heart Journal* have reason to pride themselves on the publication of this article in which Professor Francis Davies sums up the results of a long and careful examination of the conducting muscular system of the vertebrate heart. He has made discoveries of outstanding importance —especially the existence in the bird's heart of a system more highly evolved than even that of the mammalian heart (which Dr. Ivy McKenzie and I had searched for and missed); no less outstanding in importance is his success in following the ultimate branches of the A-V bundle to their termination in the ventricular musculature.

While reading the proof sheets of Professor Davies's article, there came back to me the memory of a letter I received from the late Sir James MacKenzie (then in Burnley) informing me of Tawara's discovery of the A-V conducting bundle in the mammalian heart. The letter came late in 1905 or early in 1906. I had then been at work on the anatomy of the heart for five or six years,* and thought I knew all that was to be found in that organ. Indeed, I was so sceptical of the existence of the bundle that I had drafted a letter to the *Lancet* denying its existence but, fortunately for me, made one more search before committing myself, and found in the human heart all as Tawara had described it, and then wondered how I had missed a structure that was so evident—when once seen. So the letter was amended and dispatched (*Lancet*, 1906, 1, 623). I took the lesson as a warning and yet repeated the mistake a few years later when searching for an A-V system in the bird's heart. Probably my microscopic technique was at fault; I have always envied men who were masters of microscopic technique—almost as much as I envied my friends who could hold free converse in foreign languages.

My partnership with MacKenzie of Burnley must have begun about 1904; he sent me hearts of his more famous cases to see if I could find a pathological basis for their irregularities. I dissected and drew them, cut sections of all parts, but after many months of close observation got no definite correlation between the type of arrhythmia and a pathological lesion, so great was the variation in microscopic appearance as I went from heart to heart. But one thing I did find that afterwards proved to be of significance. At the time

* Readers will find my work of that time buried in the *Proceedings of the Anatomical Society* (published in the *Journal of Anatomy*), from 1902 onwards.

we were all impressed by the fact that in lower vertebrates the contraction wave of the heart was initiated in the *sinus venosus*. Hence in cutting MacKenzie's hearts I made my sections so as to expose the remnants of the sinus which are included in the right auricle. In all my sections which traversed the sulcus terminalis where the superior vena cava entered the right auricle (the sulcus marking the infolding of the sinus) I noted a localized density of tissue in which nerve fibres seem to terminate. So variable was this structure in its density and form in hearts that had manifested irregularities of rhythm and in others that were reputed to have been normal in action, that I passed it by as having no functional significance. This was before Tawara had made his discovery.

At that time my wife and I rented a farmhouse in Kent, where we spent vacations. We lived near the village of Bredgar, famous for its cherry orchards; a neighbouring village was Borden where lived the Flack family. We heard that Martin Flack, just down from Oxford, was looking for a hospital at which to continue his medical studies and lost no time in putting before him the attractions of the London Hospital, where I taught anatomy and Leonard Hill physiology. Martin joined us; indeed he became more Hill's pupil than mine. His was a most attractive personality, fair haired, clean skinned, bright-eyed, short and sturdy—my ideal of a Saxon youth; merry, ever ready for work or play; as true and lovable a man as I have met.*

In the long vacation of 1906, Flack and I turned my study at Bredgar into a laboratory—microtome, oven, microscopes; we had a vast store of human hearts and were trapping moles, rats, mice, and hedgehogs with the intention of verifying and extending Tawara's discoveries on their hearts. I remember well one very hot day, late in the summer of 1906, my wife and I going out on our bicycles leaving Martin running serial sections of a mole's heart. On returning he bade me look through a microscope at a strange structure he had found at the junction of the superior cava with the right auricle. The structure was muscular but quite different from the musculature round about. I remembered the body I had seen in the MacKenzie hearts; we set to work and found it at the same site in all the mammalian hearts at our disposal. In structure it resembled the node of Tawara; hence we *inferred* it to be the site at which the cardiac rhythm was normally initiated (*J. Anat.* (1907) 41, 173).

That is the beginning of our knowledge of the S-A node in the rough. Professor Davies has produced the finished article. Yet there are one or two points in his account that leave me unsatisfied. There is the relation of nodes to nerves which is left untouched. There is the secretory side of nodal function to be considered—or rather the excretory or secretory hormone formed at neuro-nodal junctions. Therein lies the central nervous control of the cardiac rhythm. After all, nerve cell and muscular cell have a common ancestry and there is still room to believe there may be cells which retain the common ancestral qualities of irritability and contractibility and that nodal cells do retain these original characters. I wish someone would again examine the sino-auricular

* In the 1914-18 war, Dr. Flack became scientific advisor to the Medical Department of the embryonic R.A.F. He died August 16, 1931, just when his great ability was meeting with a wide and deserved recognition.

node of Ornithorychus; my sections are lost, but I believed I could trace in them a direct continuity of nerve fibre and nodal cellular element.

Professor Davies regards the muscular connecting system of the mammalian and avian heart as a new formation—one which appeared in the evolution of animals at the same time as a temperature regulating system. Such a sudden appearance would be an example of emergent evolution—a form of evolution I have the same antipathy to as I have for miraculous happenings of all kinds. They are made believable by blanks in our knowledge. We know enough to reject the idea that warm-blooded beasts appeared suddenly; there are still intermediates in this respect—the Monotremes. I agree that heart action and body temperature must have been coordinated in their evolution, but, although the detection of the coordinating mechanism in the evolving or developing animal body still eludes us, that in no wise shakes our confidence that it exists and will be discovered. And its foundation will be found not in something interpolated but in an emergence from something that has gone before. The A-V bundle may have developed as Professor Shaner has described and still be a modification of the auriculo-ventricular function of the cold-blooded heart.

CHEST LEADS IN CONGENITAL AND ACQUIRED DEXTROCARDIA

BY

J. S. RICHARDSON

Received February 20, 1942

Four cases with hearts situated in the right side of the thorax have been seen recently in a military hospital. Two of these had true dextrocardia (Cases 1 and 2), and were admitted for diseases that did not affect the heart. One was suffering from an apical lobar pneumonia and the other from a gastric ulcer, and in each the dextrocardia was an incidental finding. There was transposition of the viscera in both, and the heart was a mirror image of the normal, as shown by screening and by X-ray films in the antero-posterior and oblique positions.

The third (Case 3) had a traction dextrocardia with cardiac dullness to the right of the mid-line. X-ray examination showed that the heart was pulled over, with the apex under the right border of the sternum, and the chambers were in their normal relationship.

The fourth (Case 4) was one of eventration of the left lobe of the diaphragm of such degree that the heart was displaced to the right of the mid-line. It was not rotated from its normal relationship to the chest wall as shown by radiography and screening, and had a perfectly normal outline.

Electrocardiograms were taken and the standard leads I, II, and III were used with the chest leads C_2F and C_4F, as laid down by the American Heart Association and the Cardiac Society of Great Britain and Ireland (1938). Two further chest leads were taken to reproduce, for the cases of true dextrocardia, the same arrangements of leads as is used with C_2F and C_4F in the normal subject: an upward deflection indicated a positive electrical potential in the heart. The lead that was equivalent to C_2F was taken from the right sternal margin in the fourth interspace, with the indifferent electrode on the right ankle, C_2F (right): the lead equivalent to C_4F was taken from the right mid-clavicular line in the fifth right interspace with the indifferent electrode on the right ankle, C_4F (right).

In Cases 1 and 2, the three standard leads were similar to those usually found in dextrocardia: all the waves in lead I were inverted and the maximum deflections were found in lead III instead of in lead II. The chest leads, C_2F and C_4F, showed inverted P and T waves. The direction of the deflection of the P wave is so inconstant in chest leads if the indifferent electrode is not

on the right arm (Deeds and Barnes, 1940), that it must be neglected in the present instance. The inverted T wave, on the other hand, is a significant feature. When the leads C_2F (right) and C_4F (right), equivalent to the chest leads C_2F and C_4F in those with normally placed hearts, were taken, the tracing was normal in all respects, and the T waves were positive or diphasic (Case 1, C_2F (right); see Fig. 1). These findings resemble those of Kossman (1940) who

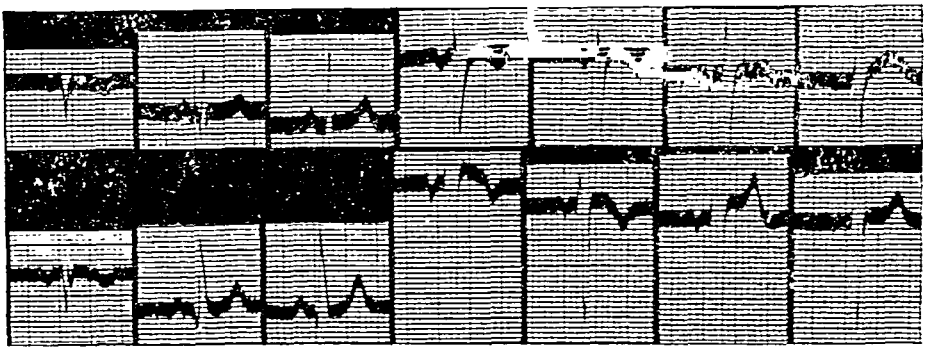

I II III C_2F C_4F C_2F (right) C_4F (right)

FIG. 1.—Standard and chest leads in two cases of congenital dextrocardia: Case 1 (above) and Case 2 (below). The leads are indicated below.

writes of five cases of true dextrocardia that " the T wave was isoelectric or negative in leads from the left side or middle of the chest and positive in leads from the right side."

The case with a traction dextrocardia (Case 3) had normal leads I, II, III, C_2F, and C_4F, but C_2F (right) and C_4F (right) had upright T waves. Case 4 had normal leads I, II, III, C_2F, and C_4F, and a negative T wave in C_4F (right), but a positive T was present in C_2F (right) (see Fig. 2).

It was decided to find out if normally placed hearts would give a downward deflection of T in leads C_2F (right) and C_4F (right). Cases were therefore

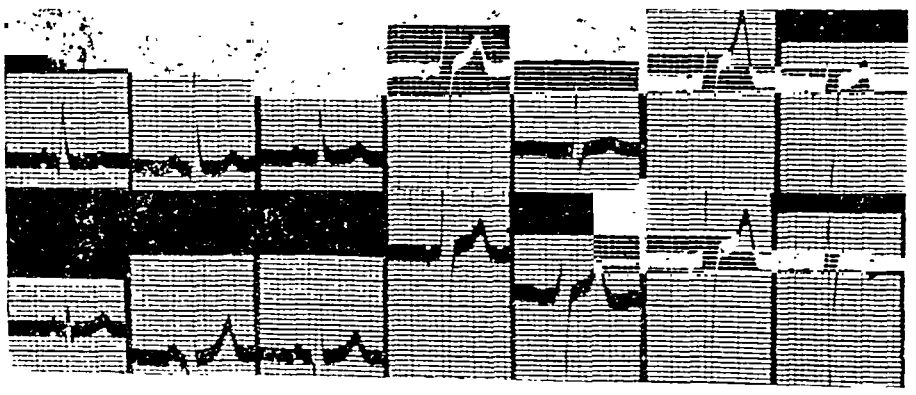

I II III C_2F C_4F C_2F (right) C_4F (right)

FIG. 2.—Standard and chest leads in two cases of acquired dextrocardia: Case 3 (above) and Case 4 (below). The leads are indicated below.

selected who gave no past history of rheumatism or of any other condition that might have damaged the heart, had no symptoms found in cardiac disease, had a good exercise tolerance, and hearts that were normal, clinically and radiologically. Eighteen cases were examined and gave normal tracings in the standard leads. The results in regard to the direction of the T waves were as follows:

	Positive	*Negative*	*Varying* *
C_4F	18	0	0
C_2F	15	1	2
C_2F (right)	1	14	3
C_4F (right)	0	18	0

* In these cases the T wave varied from tracing to tracing between positive diphasic and negative deflections.

Thus in the normal, C_4F always had a positive, and C_4F (right) a negative T wave, while the sternal leads were predominantly positive when taken on the left, and negative on the right. Deeds and Barnes (1940) found positive T waves in leads C_2F and C_4F in 99 and 100 tracings respectively from their 100 normal cases. They also found that T was negative or diphasic in 79 per cent of cases in lead C_1F, that is, with the chest electrode to the right of the sternum.

The two cases of dextrocardia had reversed deflections of the T wave in the chest leads as compared with the normal.

The case of traction dextrocardia showed a mixture: the direction of the T wave in leads C_2F and C_4F was positive, i.e. normal, but in the leads from the right side of the chest wall and the right ankle the direction of the T waves was also positive, thus resembling true dextrocardia.

Case 4 with a positive T in lead C_2F (right) but normal deflections in the other leads cannot be regarded as having an abnormal tracing, since the T wave in C_2F (right) was positive in one and variable in three of our eighteen normal cases and was positive in 21 per cent of Deeds and Barnes' cases.

Summary

1. Two cases of congenital dextrocardia with transposition of the viscera were found to have in chest leads T waves that had deflections in the opposite direction to the normal.

2. In two cases of acquired dextrocardia, one had T waves in leads, taken from the right side of the chest, that resembled those of congenital dextrocardia in direction, but the other conformed to the tracing found in about 20 per cent of subjects with normally placed hearts.

It is a pleasure to express my thanks to Professor W. T. Ritchie for his interest and advice, to Professor D. M. Dunlop, Director of the Clinical Laboratory, Edinburgh Royal Infirmary, for his kindness in permitting me to use the Electrocardiographic Department, and to Mr. R. P. Danskin for taking the tracings and for his generous help.

My thanks are also due to Lt.-Col. J. G. Ronaldson, R.A.M.C., for permission to forward this paper for publication.

References

Deeds, D., and Barnes, A. R. (1940). *Ibid.*, 20, 261.
Kossman, C. E. (1940). *Ibid.*, 20, 322.
Standardization of præcordial leads (1938). *Amer. Heart J.*, 15, 107, 235.

ELECTROCARDIOGRAPHIC CHANGES DUE TO TRAUMA

BY

HUGH BARBER

From the Derbyshire Royal Infirmary

Received April 25, 1942

Many electrocardiograms have been recorded in cases of trauma of the heart. Beck (1935 and 1940) has studied the problem in the surgical wards and in animal experiments. Kissane (1937 and 1940) has published clinical and experimental records, and in Warburg's analysis of cases (1938 and 1940) there are his own tracings and those of other workers. Anderson (1940) published a case, with full clinical details and convincing electrocardiographic proof of myocardial injury. Zuckerman (1942) and Kessler (1941) record experiments.

From this hospital (Barber, 1938 and 1940) there are clinical notes of case histories suggesting heart trauma dating back to 1910; and there is evidence from accident autopsies (Barber and Osborn, 1941).

Both animal experiments and clinical records suggest that the electrocardiogram should be taken quite soon after the injury, because abnormalities may be in evidence only for a short time.

This paper gives an account of a series of electrocardiograms from patients, irrespective of their symptoms, who came to hospital as the direct result of a severe blow over the front of the chest, or some crushing injury of the thorax. Most of the examinations were made within a few hours of the accident and all within 48 hours; the patients being seen in the casualty department, the radiological department, or a surgical ward. The total number examined was thirty-three, in whom there were eight abnormal tracings of definite but varying significance, and two that were inconclusive.

The accidents were all from traffic or industry; not one of them was the result of enemy action. They were selected, as opportunity arose, on the basis of having sustained a reasonably severe blow or injury. All those showing an abnormal tracing were with one exception below 45 years in age, and they were active people free from degenerative processes. The youngest, aged 17 years, who developed heart block from a crushing injury of the thorax, is a good illustration of the fact that in the young and elastic chest the heart may be injured without fractures of bone.

There was rather a high proportion of seriously injured in the series, but that is to be expected, if one seeks material coming to hospital soon after

accident. There is ample evidence, in the reported cases, of heart trauma after accidents that had seemed to be comparatively trivial. One need only look at the cardiographic pictures to see that an early tracing is required.

No two accidents are quite alike, but comparison with the experimental work in animals will show that many of the abnormal tracings recorded therein have been met with in this series of hospital accident cases. Analysis of the symptoms is not profitable with a series so small and variable. Moreover, early symptoms of a cardiac lesion may have been masked by the associated injuries, and in some cases later ones kept in check by the necessary rest in bed. Some of the most convincing clinical histories suggesting myocardial contusion recount a blow or crushing injury; then an interval, variable in time, before symptoms of dyspnœa and angina develop; and perhaps no heart investigation until two or three weeks later. It is in this way that proof may be unobtainable. And by way of contrast, one or two cases in this series, with significant temporary changes in the T waves, may have shown little or no evidence from symptoms, because the associated chest injuries necessitated a rest in bed until the heart had recovered.

From the publications referred to, it is possible to find complete clinical pictures of traumatic heart lesions with history, symptoms, and signs; but this paper is confined to an analysis of the electrocardiograms in a series of accidents. There was no example of auricular fibrillation, nor was there a picture resembling coronary thrombosis. There was one example of partial heart block. These three abnormalities are the most likely to be associated with clinical symptoms of long duration in a case of trauma.

The abnormal tracings in this series have been one example of partial heart block, one of sinus bradycardia, one of slurring of the R waves, and five with temporary changes in the T waves. Two more with changes in lead III alone are considered doubtful. In view of the recent publication of White, Chamberlain, and Graybiel (1941) that the T wave in lead II may sometimes vary with a change in position of the patient, it is necessary to say that all the tracings were taken with the patient lying down. Brief notes of the cases follow.

Case Notes

Case 1. *Partial Heart Block* (Fig. 1). C. M., male, aged 17 years. On November 11, 1941, at 8.30 a.m., he was crushed between the radiator of a large lorry and a wall. He was doubled up with pain for a few minutes and coughed up a little blood-stained material. He soon recovered and cycled up to hospital. Examined at 10 a.m. there was no distress, the X-ray evidence was negative, except for slight dimness in the left lung (which passed off in two days): the pulse rate was 45 to 50, not quite regular, with a tendency to have three beats and a pause; the first sound was prolonged; there was also an occasional premature ventricular contraction. The cardiogram showed partial heart block (see Fig. 1). The blood pressure was 115 systolic and 55 diastolic. He was detained in hospital three weeks with no change in his condition or his tracing. The heart rate increased to 68 to 72. A month after the accident, he was short of breath if he walked more than a mile. Three months after he had no discomfort unless he ran, and he had started light work. Numerous tracings had shown no change in the long P–R interval. After five months the heart rate was

72, the blood pressure was 120 systolic and 80 diastolic, and the tracing unchanged, except that the P–R interval was more uniform in length, 0·35 of a second. He was working successfully but not capable of running without discomfort. He had not

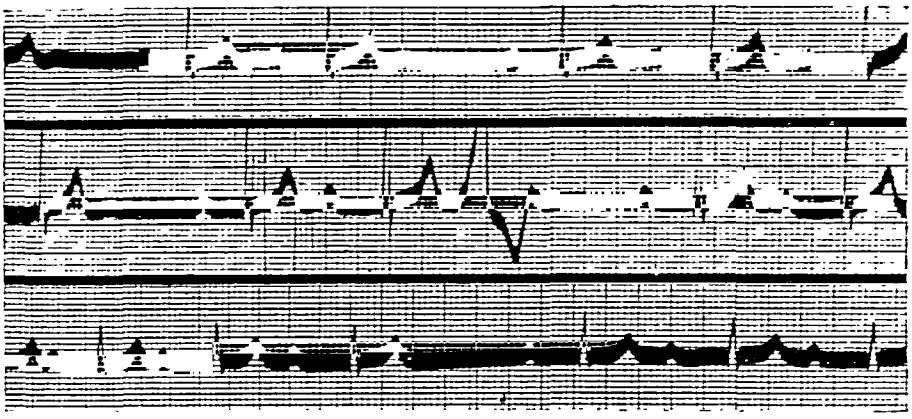

FIG. 1.—Partial heart block after trauma.

had rheumatic fever or scarlet fever, and the Wassermann was negative. There was no evidence from his doctor to suggest that he had heart disease from natural causes, and he was a vigorous cyclist and player of games before the accident.

Case 2. *Sinus Bradycardia* (Fig. 2). B. F., male, aged 33 years. On February 2, 1942, he was driving a trolley-bus, which skidded and ran into a wall. He bruised his chest on the steering-wheel and was " winded," but cleared up the accident; and an hour later drove off with another bus. After driving for a quarter of an hour

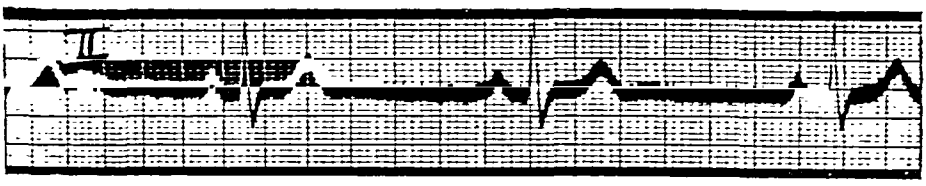

FIG. 2.—Sinus bradycardia after trauma.

he fainted, quite unexpectedly. He soon recovered and was brought to hospital. Nothing abnormal was found, except for a slow heart rate of 44. He was admitted for two days; when the heart rate taken every hour varied between 36 and 46. He reported on the fifth day, free from symptoms, with a heart rate of 45 and a normal tracing. On the twelfth day the rate was 72 and he was quite well. Sinus bradycardia has been recorded in animal experiments.

Case 3. *Slurring of the R waves* (Fig. 3). F. C., male, aged 26 years. On January 18, 1939, he was struck on the front of the chest by a fall of limestone, which crushed him against a lorry. The left clavicle and the third, fourth, and fifth ribs were fractured and the left scapula. He was admitted to a surgical ward, rather shocked, with a pulse rate between 90 and 100, but no other signs of heart lesion except slurring of the R waves in all three leads. On February 2 there was no change, but on February 7 it was only definite in lead I. He went home after six weeks and was at work, feeling quite well, three months after the accident. Asked to report three years after the accident, he gave a history of excellent health and his cardiogram was normal in all four leads. Slurring of the R waves has been recorded in animal experiments.

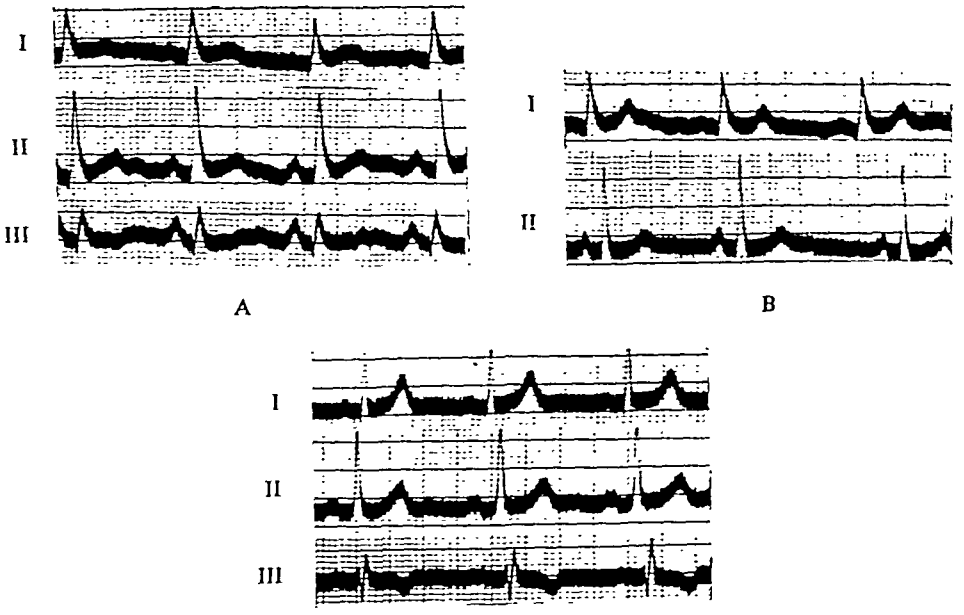

FIG. 3.—Slurring of the R waves. (A) 18/1/39. (B) 7/2/39. (C) 5/3/42.

Case 4. T waves of exaggerated amplitude (Fig. 4). G. W., male, aged 35 years. On January 20, 1942, he was kicked over the front of the chest by a horse, which knocked him across the stable. Seen in the Casualty Department an hour later, he

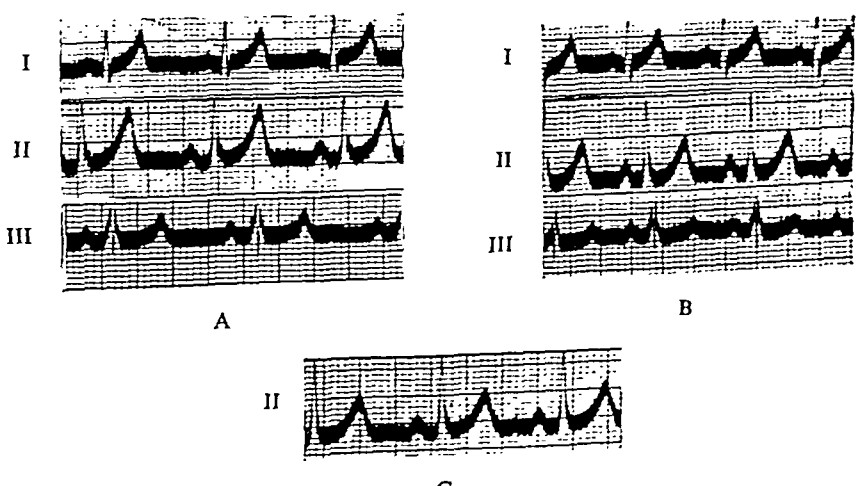

FIG. 4.—T waves of exaggerated amplitude after trauma. (A) 20/1/42. (B) 23/1/42. (C) 27/1/42.

was free from distress. The X-ray and other findings were normal, but the electrocardiogram showed T waves of an amplitude almost equal to that of the R waves. Three days later the proportions were normal; bruising was noticed around the costal

cartilages between the nipple and the sternum. Seven days after the accident the tracing was normal. There had been no symptoms of discomfort apart from the bruising. Beck (1935) has recorded this finding.

Case 5. *Temporary changes in T waves* (Fig. 5). E. D., female, aged 31 years. On December 3, 1941, she was thrown out of a motor car. There was bruising of the back and chest. Two ribs were fractured on the right side, also the right scapula and one rib on the left side. She was very distressed, with extensive lung contusion on

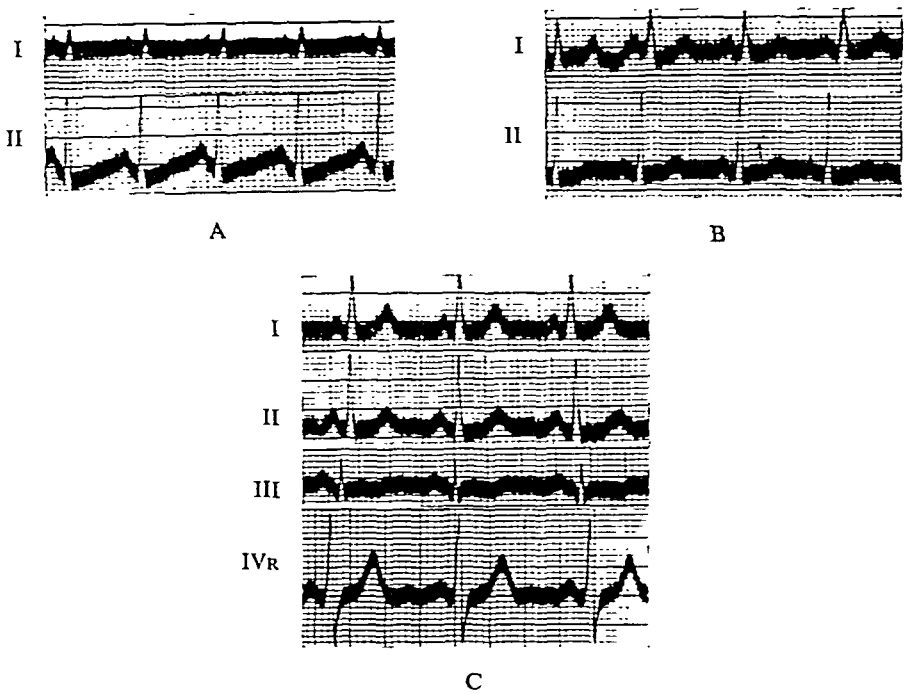

FIG. 5.—Temporary changes in T_1 and T_2 after trauma. (A) 4/12/41. (B) 15/12/41. (C) 6/1/42.

both sides and pleurisy over the left lung. The T waves in leads I and II were flat or absent. On the sixth and seventh days there was a pericardial friction sound, but this was only definite on these two days. Twelve days after the accident the T waves were upright, and after five weeks the tracing was normal in all four leads. In the fourth week, when she was well enough to screen properly, a small but definite pericardial effusion was recognizable. She travelled to her home by car thirty miles in the eighth week: and reported four months after the accident that she was getting about quite well but sometimes had a tightness in the chest if she hurried. The early return to normal of the T waves is an important observation, in view of the X-ray evidence later.

Case 6. *Temporary Changes in the T waves* (Fig. 6). J. M., male, aged 28 years. On December 4, 1941, he was felling a tree, when the trunk swung round and crushed him against the stump. He was admitted with five ribs fractured on the right side and his left scapula; also fracture of the seventh dorsal vertebra. He was admitted rather shocked with a quick heart rate. Next day the electrocardiogram showed a flat T wave in lead II, which was little improved four days later, but was quite normal on the seventeenth day after the accident. He was up in a spinal jacket in two months, and was quite well in himself three months after the accident, having exercises for the spine.

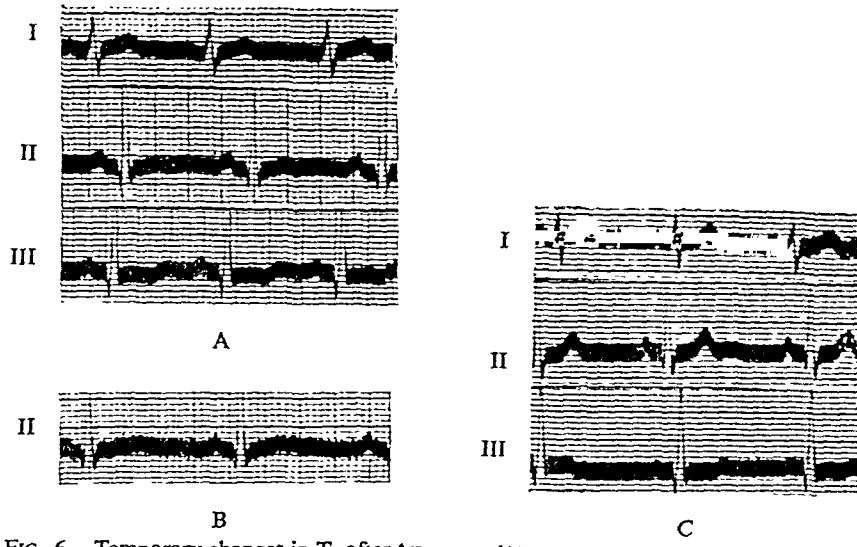

FIG. 6.—Temporary changes in T_2 after trauma. (A) 5/12/41. (B) 9/12/41. (C) 23/12/41.

Case 7. Temporary Changes in the T waves (Fig. 7). W. H., male, aged 62 years. On November 19, 1940, he was crushed by a fall of roof in a coal mine. He was admitted with extensive superficial bruising and some pain in the chest, but no dyspnœa. The electrocardiogram showed a flat or slightly inverted T wave in lead I. Three

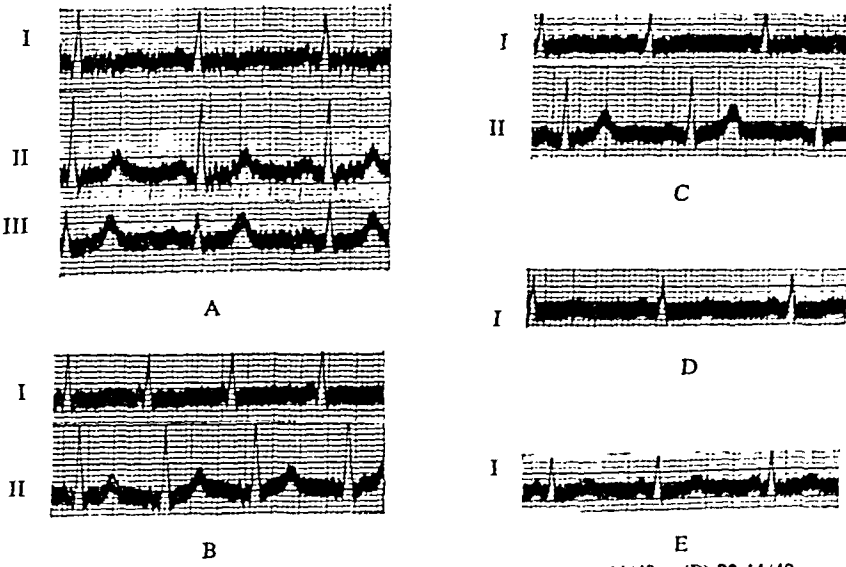

FIG. 7.—Temporary changes in T_1 after trauma. (A) 19/11/40. (B) 22/11/40. (C) 10/12/40. (D) 31/12/40. (E) 14/1/41.

days later this was unchanged. He had a large heart with the diastolic blood pressure 110 and the systolic 180. His arteries were thick and tortuous. He went home after two weeks, and subsequent tracings (Fig. 7) show the T wave improving until it was definitely upright eight weeks after the accident. In six months he was back at work again.

Case 8. *Temporary Changes in the T waves* (Fig. 8). F. M., male, aged 45 years. On March 3, 1942, he was crushed between two buffers. There was extensive bruising over the trunk, with subcutaneous emphysema over the left side. He was very shocked, with a heart rate of 100 and sometimes 140. The second, third, and fourth ribs were

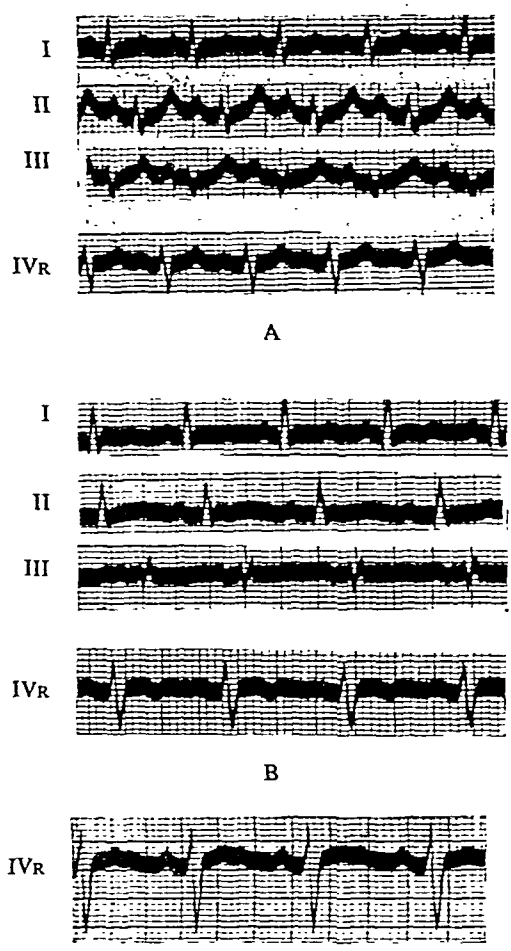

FIG. 8.—Temporary changes in T waves of all leads after trauma. (A) 10/3/42. (B) 13/3/42. (C) 16/3/42.

fractured on the left side and also the left scapula. The cardiogram a few hours after the accident was normal. Three days later his general condition was rather improved, but the tracing showed inversion of the T wave in lead IVR and the other T waves were flat (Fig. 8). In another three days the T waves were normal again. He progressed favourably and was getting about the ward by the end of five weeks.

Cases 9 *and* 10. *Temporary Changes in T wave of lead III only.* There were two examples of this, one in a man who had a large bruise over the sternum from a blow from a machine belt, and the other in a man who was crushed between two buffers. In neither case was there a fracture. Both were free from any serious symptoms.

As an explanation of this finding the possibility of a change in the height of the diaphragm must be considered. In one of them examinations could be made that appeared to exclude this, but the other was confined to bed.

Analysis of the Accidents

The accidents may be grouped rather loosely as follows:

1. Crushed by a fall of roof in a coal mine: four cases, illustrated by Fig. 7.
2. Crushed between two buffers, or similar accident: seven cases, illustrated by Fig. 1, 6, and 8.
3. Chest injuries against steering-wheel of car: one case, illustrated by Fig. 2.
4. A severe fall on to the chest: six cases, illustrated by Fig. 5.
5. Kicked on the chest by a horse: two cases, illustrated by Fig. 4.
6. A severe blow over the chest or left side: thirteen cases, illustrated by Fig. 3; *in this group were the two doubtful tracings, 9 and 10, not illustrated.*

It is of interest that there should be only one "steering-wheel" accident, because it is a fairly common one, of which there have been two more examples at this hospital recently. They are excluded from this series, because they did not come to hospital until the fourth week after the accident. Both had a crack in the sternum and were complaining of anginal symptoms, but the electrocardiogram was normal at this stage. One, aged 40 years, recovered completely after about six weeks, but the other, aged 51 years, complains of some limitations to his response to exertion six months after the accident. He has no claim to compensation.

Summary

A series of 33 hospital accident cases has been examined within two days of the injury. Patients with a severe blow over the chest or a crushing injury of the thorax were selected as opportunity arose.

Eight abnormal electrocardiograms were obtained. The changes observed are comparable with results obtained in animal experiments.

My thanks are due to my surgical colleagues and to Mr. G. Lovell Stiles for his help in the X-ray department and with the tracings.

References

Anderson, R. G. (1940). *Brit. med. J.*, 2, 307.
Barber, H. (1938). *Ibid.*, 1, 433.
—— (1940). *Ibid.*, 2, 520.
—— and Osborn, G. R. (1941). *Brit. Heart J.*, 3, 127.
Beck, C. S. (1935). *J. Amer. med. Ass.*, 104, 109.
—— (1940). *Diagnosis and Treatment of Cardiovascular Disease.* Edited by Stroud, Philadelphia, vol. 2, p. 1157.
Bright, E. F., and Beck, C. S. (1935). *Amer. Heart J.*, 10, 293.
Kessler, H. H. (1941). *Accidental Injuries.* New Jersey, p. 387.
Kissane, R. W. (1937). *Contusion of the Heart.* Ohio State University, Columbus.
——, Fidler, R. S., and Koons, R. A. (1937). *Ann. intern. Med.*, 11, 907.
—— —— —— (1940). *Advancement of Science*, 13, 170.
Warburg, E. (1938). *Subacute and Chronic Pericardial and Myocardial Lesions due to Non-Penetrating Traumatic Injuries.* Copenhagen.
—— (1940). *Brit. Heart J.*, 2, 271.
White, P. D., Chamberlain, F. L., and Graybiel, A. (1941). *Brit. Heart J.*, 3, 233.
Zuckerman, S., Krohn, P. L., Whitteridge, D. (1942). *Lancet*, 1, 252.

THE ELECTROCARDIOGRAM IN FRIEDREICH DISEASE

BY

WILLIAM EVANS AND GORDON WRIGHT

From the Cardiac Department of the London Hospital

Received May 5, 1942

It has been the custom to regard Friedreich disease as affecting only the central nervous system, but an examination of 38 cases has convinced us that the heart also is often affected.

When recording the clinical and pathological findings in a patient with Friedreich's ataxia who had been treated for heart failure at Guy's Hospital and the London Hospital, Newton Pitt (1887) said that not enough attention had been paid to the circulatory system in this disease: in his patient, heart failure had been an outstanding feature of the last phase of the fatal illness and was the cause of death. The case records of Friedreich disease published since deal chiefly with changes in the nervous system, and reference to symptoms connected with the heart has generally been either casual or missing. Yet a few cases that showed some abnormality of the heart have been recorded. Histological changes in the myocardium were described by Lannois and Porot (1905) and by Guizzetti (1933). Heart failure was reported by Omerod (1885) and Pitt (1887). Electrocardiographic irregularities have been described occasionally during the past ten years. Guillain and Mollaret (1932) found inversion of the T wave in leads II and III in one case, and a prolonged P–R interval with right axis deviation in another; so impressed were they by these changes that they spoke of the "cardiobulbar syndrome." Nodal arrhythmia, right electrical axis deviation, and a diphasic or inverted T wave in lead I were shown in an electrocardiogram published by Rathery, Mollaret, and Sterne (1934). Progressive cardiographic changes were watched for two years in a patient by Guillain and Mollaret (1934), and the last tracing showed inversion of T_2 and T_3. A similar curve was found in a child by Debré, Marie, Soulié, and de Font-Réaulx (1936). In eight patients examined by van Bogaert (1936) the cardiogram showed inversion of T_1 and T_2 in two cases and of T_2 and T_3 in another two; there were minor changes in two of the remaining four.

We became interested in the subject when a young woman (Case 1) suffering from this condition was found with Stokes-Adams attacks, and when we were told that her brother, similarly affected, had died at the age of 18 during an attack. We arranged to examine the heart specially in other cases of Friedreich disease, and in this paper we give the findings in 38 patients assembled for the

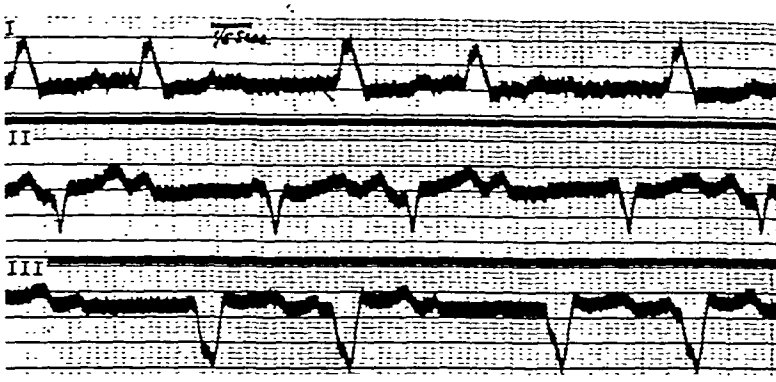

FIG. 1.—Female, aged 22 (Case 1). Complete and left bundle branch block with extrasystoles. Fig. 1, 2, and 3 have been reduced to 2/3.

investigation. In every case the diagnosis of the condition had been made by a neurologist, and a further routine examination was carried out before admitting the patient into the series. A limb lead electrocardiogram was recorded, and whenever an abnormality of the T wave showed in lead I, lead IVR was taken as well. Other chest leads were sometimes recorded. Cardioscopy was carried out in 34 patients, but not in 4 who were bedridden.

RESULTS

Clinical Examination of the Heart.—In only one patient (Case 1) was the pulse abnormal, and then it was slow from heart block and irregular from

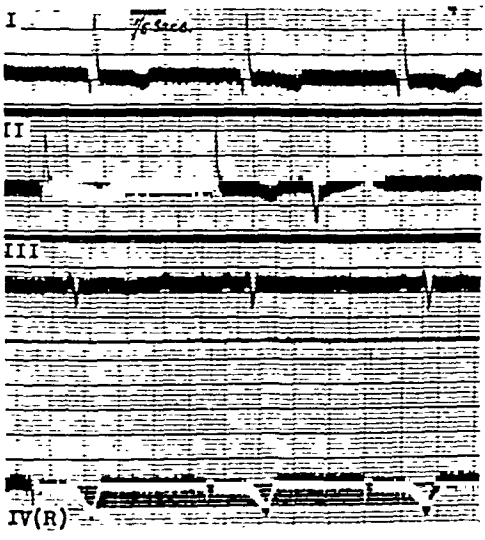

FIG. 2.—Male aged 50 (Case 2). T inverted in leads I, II, and IVR.

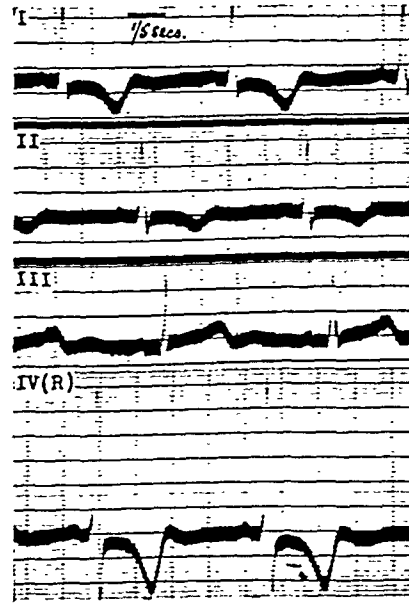

FIG. 3.—Male aged 22 (Case 3). T inverted in leads I, II, and IVR.

extrasystoles; the brother of this patient, who died in a Stokes-Adams attack at another hospital, is not included in this series because a cardiogram was not taken. None showed significant changes in blood pressure. The apex beat was often displaced outwards on account of scoliosis but not once from cardiac

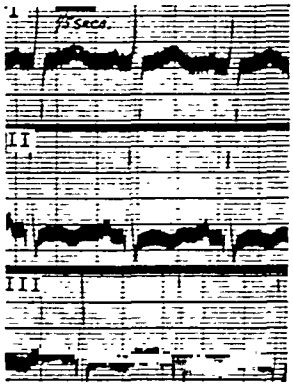

FIG. 4.—Female, aged 20 (Case 4). T inverted in leads II and III.

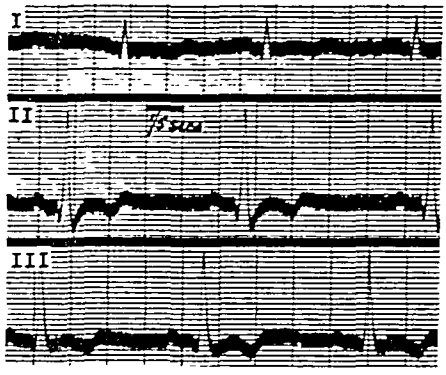

FIG. 5.—Male, aged 26 (Case 5). T low in lead I, and inverted in leads II and III.

hypertrophy. Noticeable murmurs were never found, and no valvular disease, either congenital or acquired. Except in four bedridden patients cardioscopy (i.e. radioscopy of the heart) was a routine method of examination, but it failed to demonstrate any gross changes; slight enlargement of the heart to the left,

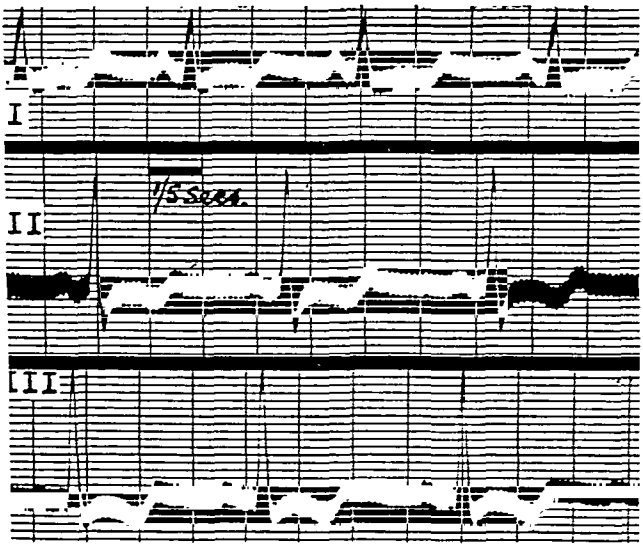

Fig. 6.—Female, aged 32 (Case 6). T wave inverted in leads I, II, and III.

sometimes confined to the toe of the left ventricle, was found in 8 patients, and 5 of these had prominent cardiographic changes.

Cardiographic Changes.—The electrocardiogram was abnormal in 12 of the 38 patients. In 10 others it was not strictly physiological, but these lesser

changes might have resulted from the deformity of the chest, which was a prominent feature of some of the cases.

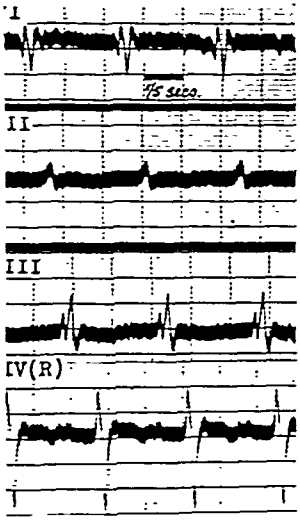

FIG. 7.—Male, aged 52 (Case 7). T flat in lead I, slightly inverted in leads II and III, and inverted in IVR.

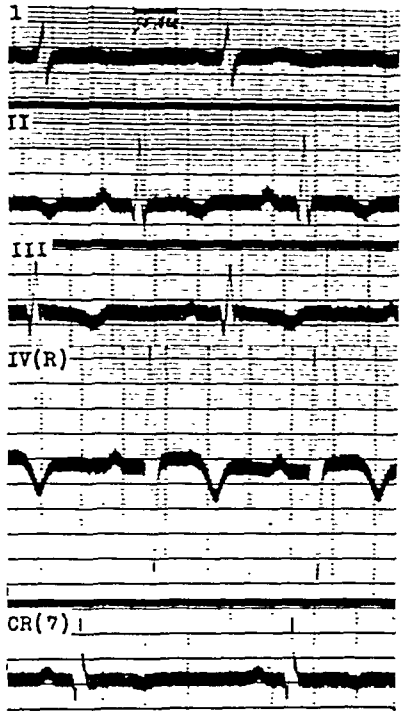

FIG. 8.—Male, aged 20 (Case 9). T just upright in lead I, inverted in leads II, III, IVR and CR_7.

Fig. 7–14 have been reduced to 7/8.

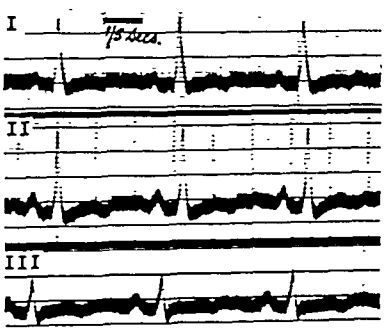

FIG. 9.—Female, aged 33 (Case 8). T inverted in leads I, II, and III.

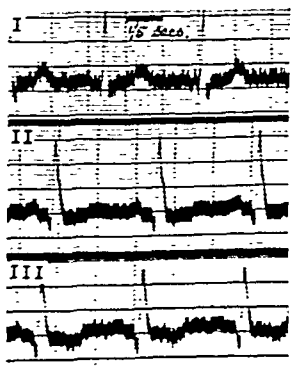

FIG. 10.—Female, aged 15 (Case 11). T just upright in lead II and diphasic in lead III.

Among the 12 abnormal cardiograms there was complete heart block and left bundle branch block in one (Fig. 1), inversion of the T wave conforming

to the T_1 type of cardiac infarction of Parkinson and Bedford (1927) in three (Fig. 2, 3, and 12), and to the T_3 type in three patients (Fig. 4, 10, and 11). In 5 cases (Fig. 5, 6, 7, 8, and 9) the T wave was low and usually inverted in all three limb leads.

In 5 of the 10 cases showing minor changes in the cardiogram the S wave

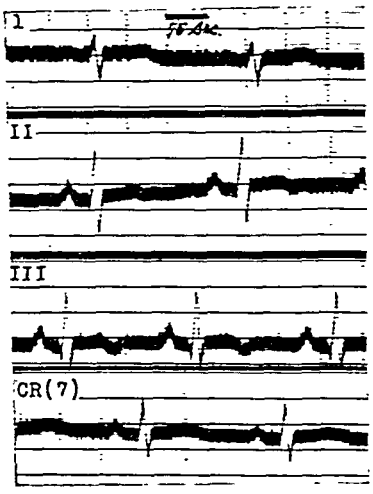

FIG. 11.—Male, aged 20 (Case 10). T inverted in lead III and just upright in leads I, II, and CR_7.

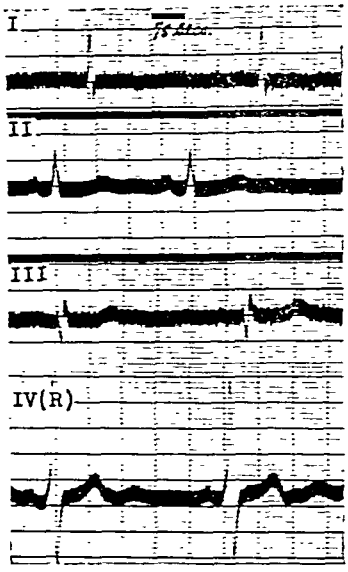

FIG. 12.—Male, aged 52 (Case 12). T inverted in lead I.

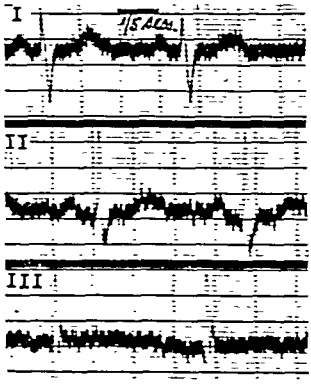

FIG. 13.—Female, aged 26 (Case 13). Deep and slurred S in leads I and II.

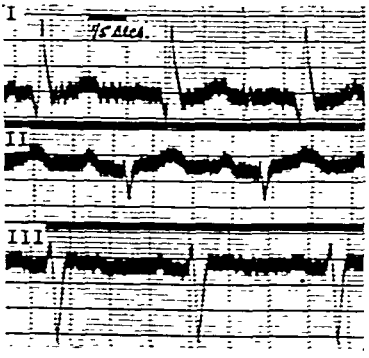

FIG. 14.—Male, aged 19 (Case 18). Deep S in leads II and III; deep Q in lead I.

was deep and often slurred in lead I and usually in lead II (Fig. 13), and in the remaining 5 there were corresponding changes in leads II and III (Fig. 14).

We did not expect to find any correlation between the incidence of cardiographic abnormalities and the distribution of lesions in the nervous system,

but it seemed worth while to inquire. The neurological findings were therefore tabulated in relation to the cardiographic changes in Table I, and more fully in Tables II, III, and IV at the end of the paper.

TABLE I

ABNORMAL SIGNS IN THE CENTRAL NERVOUS SYSTEM AND HEART IN 38 PATIENTS WITH FRIEDREICH DISEASE

Clinical Data	12 Patients with Prominent Cardiographic Changes	10 Patients with Lesser Cardiographic Changes	16 Patients with Normal Cardiograms
Family history	8 *	7	4 *
Ataxia and incoordination:			
Gross	5	8	8
Moderate	7	1	3
Slight	0	1	5
Speech affected	10 *	6	8 *
Nystagmus	7	8	12
Tremor	3	6	7
Absent Reflexes:			
Arm	7 *	5	3 *
Leg	11 *	8	9 *
Plantar Reflex:			
Extensor	11 *	4	8 *
Not determined	1	5	4
Flexor	0	1	4
Deformities:			
Pes cavus	10	9	11
Scoliosis	9	5	7

* Denotes a significant difference.

The incidence of cardiographic changes was in no way related to age or sex, or to the time of onset of the disease. Two neurological signs, absence of tendon reflexes, and extensor response of the plantar reflex, occurred in the patients with cardiographic irregularities so frequently as to be significant. Furthermore, reference to Table I shows that involvement of the nervous system as a whole was greatest in those with abnormal cardiograms.

The association of a family history of Friedreich disease with abnormal cardiographic changes was most striking. Thus 15 patients with abnormal cardiograms (gross changes in 8) had one or more relatives similarly affected, while only 4 with normal tracings had a family history. In this connection another feature came to light; that affected members of the one family tended to show the same cardiographic changes. The only patient in the series to show complete heart block and Stokes-Adams disease (Case 1), had a brother similarly affected. A sister and younger brother of Case 1 (Cases 17 and 18) showed comparable but lesser cardiographic changes. Another (Case 3), with inversion of T_1 and T_2, had a sister (Case 4) with inversion of T_2 and T_3. The cardiograms in a brother and sister (Cases 5 and 6) demonstrated inversion of T_2 and T_3. Twin brothers showed the same type of cardiographic changes although these were more severe in one (Case 9) than the other (Case 10). Two brothers and a sister (Cases 14, 15, and 16) exhibited similar tracings, but in two brothers (Cases 19 and 35) the curves were dissimilar. That identical physical

signs in relatives with Friedreich disease are not confined to the electrocardiogram was shown by two brothers (Cases 19 and 35) with primary optic atrophy, whose sister also was blind from birth and the subject of Friedreich disease.

The Meaning of the Cardiographic Findings

In the light of electrocardiographic changes in cardiac infarction it would be expected that the heart lesion in Friedreich disease usually lies in the muscle or in the conducting tissues. In those cases with a tracing similar to that found in cardiac infarction it is likely that the changes in the myocardium have a distribution in the anterior or posterior part of the heart, comparable with the areas involved when either the left or right coronary artery becomes occluded. In those patients with a " coronary type " of curve none so far have angina pectoris, and involvement of the coronary artery in Friedreich is unlikely. In a case with a cardiogram showing a Pardee type of curve, Laubry and de Balsac (1936) injected the coronary circulation with a mercurial preparation at necropsy, and in a subsequent radiogram they found no abnormality in the course of the coronary arteries. Our interpretation of the significance of the cardiographic changes also gains support from the histological findings in cases reported by Pitt (1887) and by Lannois and Porot (1905). Pitt described enlargement of the heart from hypertrophy of its walls and dilatation of its cavities. On microscopical examination he found that the muscle was healthy in many places; in some places it had undergone granular degeneration, and in others it had been replaced completely by loose and vascularized fibrous tissue, which in parts was crowded with small cells. D. S. Russell (1941) states that the heart in Friedreich disease may show a widespread change consisting of enlargement caused by thickening of the muscle and diffuse fibrosis; microscopical examination demonstrates fatty degeneration of the muscle fibres with slight chronic inflammatory infiltration and fibrosis.

It is not known yet whether the significant cardiographic changes predict the eventual onset of heart failure. Anyhow it is improbable that failure ever takes place in Friedreich disease when the electrocardiogram is normal, but the proximity of the event is likely to be judged best by the degree of cardiac enlargement determined by cardioscopy. The outlook is certainly ominous when the cardiogram signifies involvement of the bundle of His and especially when auriculo-ventricular dissociation has caused Stokes-Adams disease.

As a rule the diagnosis of Friedreich disease is straightforward after examination of the nervous system. When it is in doubt the electrocardiogram may help, for an abnormal tracing of the type described here supports the diagnosis although a normal curve does not exclude it.

Summary and Conclusions

The electrocardiogram in 38 patients with Friedreich disease was specially studied. This investigation has convinced us that the condition may sometimes be as much an affection of the heart as of the nervous system.

In only one patient, with Stokes-Adams disease, did clinical examination of the heart show any abnormality; in his case the pulse was slow from complete heart block and irregular from extrasystoles.

Cardiscopy, carried out in all except 4 bedridden patients, showed slight enlargement of the left ventricle in 8, and 5 of these had prominent cardiographic changes.

The cardiogram showed conspicuous or significant changes in 12 of the 38 patients. There were slight changes in another 10. In the remaining 16 the curve was physiological. In the first group 1 patient had complete heart block, 3 had a T_1 type of coronary curve, and 3 had a T_3 type of curve. In 5 the T wave was low and usually inverted in all three limb leads. In 5 of 10 patients showing lesser changes, the S wave was deep and slurred in lead I and usually in lead II, and similarly in leads II and III in the other 5 patients.

When the relation of abnormal signs in the nervous system to the cardiographic changes was examined, it was found that absence of tendon reflexes and extensor response of the plantar reflex were more common in patients with abnormal cardiograms. In respect of other nervous signs it may be said generally that they were more widespread in patients with the more conspicuous cardiographic changes. Of greater significance appeared to be the high incidence of a family history of Friedreich disease in those showing cardiographic changes. Thus 15 out of 22 patients with abnormal cardiograms (8 of them showing gross changes) had one or more relatives, usually a brother or sister, similarly affected, while only 4 out of 16 patients with normal curves provided this family history. The affected members of the same family tended to show identical cardiographic changes.

The electrocardiogram may help to establish the diagnosis of Friedreich disease when the neurological manifestations are not altogether typical of the condition; an abnormal tracing lends support to the diagnosis, but a normal curve does not exclude it. In prognosis too the cardiogram can be of assistance; when it proves involvement of the bundle of His it may foretell auriculo-ventricular dissociation and Stokes-Adams disease with its ominous outlook. The exact significance of a " coronary type " of curve is not known yet, but it is probable that only such cases are prone to develop heart failure, although the proximity of this event may be more closely related to the degree of cardiac enlargement, which is best determined by cardioscopy.

For these reasons we would say that the investigation of a patient with Friedreich disease is incomplete without electrocardiography and cardioscopy.

We are grateful to Dr. A. Hunter, First Assistant to the Department, who helped us in many ways, and to the following who assisted us in the collection of cases: Dr. W. R. Brain, Dr. A. E. Clark-Kennedy, Dr. C. Ellingworth, Dr. A. Feiling, Dr. A. R. Gilchrist, Dr. L. J. Grant, Dr. W. Harris, Dr. N. G. Hulbert, Dr. D. Hunter, Dr. R. Kempthorne, Mr. I. Lewis, Dr. R. Mackay, Dr. J. McM. Mennell, Mr. A. M. A. Moore, Dr. E. A. B. Pritchard, Dr. B. Russell, Dr. E. M. Sawdon, Dr. P. H. S. Shaw, Dr. B. Varling, and Dr. M. W. Warren.

We wish to thank Dr. John Parkinson, Physician to the Cardiac Department, for his helpful criticism of this paper.

REFERENCES

van Bogaert, A. and L. (1936). *Arch. Mal. Cœur*, **29**, 630.
Debré, R., Marie, J., Soulié, P., and de Font-Réaulx, P. (1936). *Bull. Mém. Soc. méd. Hôp., Paris*, **52**, 749.
Guillain, G., and Mollaret, P. (1932). *Presse Méd.*, **40**, 1621.
—— —— (1934). *Bull. Mém. Soc. méd. Hôp., Paris*, **50**, 1577.
Guizzetti, P. (1933). *Riv. Patol. Nerv.*, **41**, 545.
Lannois, M., and Porot, A. (1905). *Rev. méd., Paris*, **25**, 853.
Laubry, C., and de Balsac, R. H. (1936). *Bull. Mém. Soc. méd. Hôp., Paris*, **52**, 756.
Ormerod, J. A. (1885). *Brain*, **7**, 105.
Parkinson, J., and Bedford, D. E. (1927). *Heart*, **14**, 195.
Pitt, G. N. (1887). *Guy's Hosp. Rep.*, **44**, 369.
Rathery, F., Mollaret, P., and Sterne, J. (1934). *Bull. Mém. Soc. méd. Hôp., Paris*, **50**, 1382.
Russell, D. S. (1941). Personal communication.

Notes of the 38 cases are given in Tables II, III and IV on pages 100 to 102.

TABLE II

TWELVE PATIENTS SHOWING SIGNIFICANT OR PROMINENT CARDIOGRAPHIC CHANGES

Case No.	Sex	Age	Relatives with Friedreich Disease	Age at Onset of Symptoms	Ataxia and Incoordination	Speech Affected	Nystagmus	Tremor	Reflexes			Deformities		Cardioscopy	Cardiographic Changes
									Arm	Knee and Ankle	Plantar	Pes Cavus	Scoliosis		
1	F	22	2 brothers and sister (Cases 17 and 18)	11	++	+	+	−	−	−	Extensor	+	+	L.V. slightly+	Complete heart block with extrasystoles; left bundle branch block
2	M	50	None	16	++	+	−	−	+	−	Extensor	+	−	−	T_1 and T_2 inverted as well as T in IVR
3	M	22	Sister (Case 4)	14	++	+	−	−	+	−	Extensor	+	+	−	do.
4	F	20	Brother (Case 3)	18	+	+	−	−	−	−	Extensor	+	−	Normal	T_2 and T_3 inverted
5	M	26	Sister (Case 6)	13	+	+	+	+	−	−	Extensor	+	+	L.V. slightly+	do.
6	F	32	Brother (Case 5)	12	+	+	+	+	−	−	Extensor	+	+	Normal	T_1, T_2, and T_3 inverted
7	M	52	None	27	++	+	+	−	+	−	Extensor	+	+	L.V. slightly+	T_1 flat, T_2 and T_3 slightly inverted, and T inverted in IVR
8	F	33	Brother	13	+	+	−	−	+	−	Extensor	+	+	Normal	T_1, T_2, and T_3 inverted
9	M	20	Brother (Case 10)	16	+	−	+	−	−	−	Extensor	+	+	L.V. slightly+	T_2 and T_3 inverted: T_1 just upright. T inverted in IVR and CR_7
10	M	20	Brother (Case 9)	16	++	+	+	+	−	−	Extensor	−	+	Normal	T_3 inverted and T just upright in II and CR_7; deep S_1
11	F	15	None	10	+	−	−	−	−	−	Indefinite	+	−	Normal.	T diphasic in III and just up in II
12	M	52	None	11	+	+	+	−	+	+	Extensor	−	+	L.V. slightly+	T_1 inverted

TABLE III

TEN PATIENTS SHOWING LESSER CARDIOGRAPHIC CHANGES

Case No.	Sex	Age	Relatives with Friedreich Disease	Age at Onset of Symptoms	Ataxia and Incoordination	Speech Affected	Nystagmus	Tremor	Reflexes			Deformities		Cardioscopy	Cardiographic Changes
									Arm	Knee and Ankle	Plantar	Pes Cavus	Scoliosis		
13	F	26	None	11	+	−	+	−	+	+	Indefinite	+	−	Normal	Deep and slurred S_1 and S_2
14	F	44	2 brothers (Cases 15 and 16)	18	++	+	+	+	−	−	Indefinite	+	−	Normal	Deep and slurred S_1, S_2, and S_3
15	M	34	Sister and brother (Cases 14 and 16)	18	++	+	+	+	+	−	Indefinite	+	−	Normal	Deep and slurred S_1
16	M	42	Sister and brother (Cases 14 and 15)	19	++	+	+	+	−	−	Indefinite	+	+	Normal	do.
17	F	15	Sister and 2 brothers (Cases 1 and 18)	10	++	+	+	+	−	−	Extensor	+	+	Normal	do.
18	M	19	2 sisters (Cases 1 and 17) and brother	12	++	+	+	—	−	−	Flexor	+	+	L.V. slightly +	Deep S_2 and S_3; deep Q_1
19	M	43	Brother (Case 35) and sister	Infancy	++	−	−	+	+	+	Extensor	+	−	Normal	Deep and slurred S_1, S_2, and S_3
20	M	39	None	15	++	−	−	−	−	−	Indefinite	+	+	Normal	Deep S_2 and S_3
21	M	16	None	8	++	Dumb	+	−	+	−	Extensor	+	−	—	do.
22	M	45	4 brothers	34	+	+	+	+	+	−	Extensor	−	+	Normal	do.

TABLE IV

16 PATIENTS WITH NORMAL CARDIOGRAM

Case No.	Sex	Age	Relatives with Friedreich Disease	Age at Onset of Symptoms	Ataxia and Incoordination	Speech Affected	Nystagmus	Tremor	Reflexes			Deformities		Cardioscopy
									Arm	Knee and Ankle	Plantar	Pes Cavus	Scoliosis	
23	M	21	None	11	++	Dumb	+	−	+	−	Flexor	−	+	Normal
24	M	39	None	23	++	+	+	+	+	−	Flexor	−	+	Normal
25	F	36	None	11	++	+	+	+	+	−	Flexor	−	+	Normal
26	F	37	None	15	++	+	+	+	+	+	Extensor	+	+	Normal
27	M	13	None	12	+	−	+	−	+	+	Extensor	+	−	Normal
28	M	56	None	12	++	+	+	−	+	+	Extensor	+	−	—
29	F	32	None	11	++	+	+	+	+	−	Extensor	−	+	Normal
30	F	21	None	10	+	−	−	−	+	−	Flexor	+	−	L.V. slightly+
31	F	19	Sister (Case 36)	7	+	−	+	−	+	+	Extensor	+	−	Normal
32	M	45	None	23	+	−	−	+	−	−	Indefinite	+	−	Normal
33	F	30	None	17	+	−	+	−	+	−	Indefinite	+	−	L.V. slightly+
34	M	22	None	14	+	−	+	−	+	+	Extensor	+	−	Normal
35	M	48	Brother (Case 19) and sister	Infancy	++	−	−	+	+	+	Extensor	+	−	Normal
36	F	34	Sister (Case 31)	13	++	−	−	+	+	+	Indefinite	−	+	Normal
37	F	26	None	18	+	+	+	−	−	−	Extensor	+	+	Normal
38	M	31	Uncle	16	+	+	+	−	−	−	Indefinite	+	−	Normal

INTRACARDIAC TUMOURS

BY

J. L. HAMILTON-PATERSON AND L. I. M. CASTLEDEN

From the Redhill County Hospital, Edgware, Middlesex

Received June 1, 1942

Three cases of intracardiac tumour are reported in this paper and are of interest, apart from the comparative rarity of the condition, because in each case the clinical signs and symptoms suggested the presence of another lesion and the tumour was only discovered post-mortem.

The first case, with a round-cell and spindle-cell sarcoma of the right auricle, showed in life the signs and symptoms of Ayerza's syndrome. The second, with a pedunculated myxomatous tumour of the left auricle, which projected through the mitral valve, was diagnosed as mitral stenosis. The third, with a tumour only in the sense that it was an intracardiac swelling, had a mycotic aneurysm arising at the attachment of the anterior cusp of the aortic valve, extending downwards into the interventricular septum and bulging into the right ventricle; the aortic valve was the seat of a bacterial endocarditis: in life the bulging into the right ventricle had obstructed the pulmonary valve, and a diagnosis of pulmonary stenosis and rheumatic carditis had been made.

Sarcoma of Right Auricle

Case 1. A woman, aged 45 years, was admitted 30/7/41 complaining of increasing shortness of breath on exertion, of blueness of the lips for five months, and of a cough with scanty sputum for the past four weeks. Her doctor stated that auricular fibrillation had developed within the last week. She had always been strong and healthy except for a tendency to winter cough for the past five or six years. No history of rheumatic fever or chorea.

On examination she was an obese woman with intense plum-coloured cyanosis but without dyspnœa at rest. The heart appeared normal in size. Auricular fibrillation at 84 a minute was present. There were no murmurs. The blood pressure was 120/80. The lungs were emphysematous without any added sounds. The cervical veins were not overfilled, and there was no œdema of the subcutaneous tissues and no enlargement of the liver or spleen. The appearance of the patient suggested polycythæmia, but her blood count showed 4·7 million red blood corpuscules and 94 per cent hæmoglolin, with a colour index of 1·0. The urine was normal except for a trace of albumin. An electrocardiogram confirmed the presence of auricular fibrillation and showed low voltage of the QRS complexes and a flat T wave in lead III. There was no abnormal axis deviation.

On 6/8/41 the right leg suddenly became swollen up to the groin, painful,

œdematous, and more blue than the left. Physical examination showed no other change. The white blood corpuscles were 7000 per c.mm., with neutrophils 73 per cent, lymphocytes 15 per cent, monocytes 10 per cent, and eosinophils 2 per cent. On 11/8/41 there were a few râles at the right base, and thereafter signs of congestive failure increased until on 17/8/41 there were bilateral pleural effusions with œdema of both legs up to the groins. The right leg, which had remained swollen since the onset of the venous thrombosis, was still more œdematous. The heart appeared to be enlarged to the left and fibrillation was still present at 88 a minute. Mersalyl produced a severe reaction and was discontinued. Other efforts to relieve her congestion failed and sacral œdema appeared. On 25/8/41 the heart was still enlarged but the rhythm now became regular, the blood pressure remaining at 120/80. A cardiogram confirmed the presence of regular rhythm at 84 a minute, with a P–R interval of 0·28 sec. The QRS complexes still showed a low voltage with normal R–T intervals. The T waves in leads I and II were upright but flat in lead III.

The patient remained very ill with no change in her congestive failure, and on 30/8/41 venous thrombosis occurred in the right arm, which was œdematous up to the shoulder. Œdema of the right breast developed. Acupuncture of both feet was performed; the punctures drained about three pints a day and all the œdema, except that of the right arm, disappeared. The cyanosis, however, which had remained a marked feature throughout, became more intense, and for the first time she began to be dyspnœic at rest in bed. The Wassermann, Kahn, and Laughlen reactions were negative, and an X-ray of her chest showed an abnormal heart shadow with considerable bulging to the right, the appearance being consistent with pulmonary stenosis. The patient was too ill to be screened. Œdema now began to increase again, and on 12/10/41 venous thrombosis occurred in the left arm. From this point the patient's condition steadily deteriorated. Slow auricular fibrillation at 90 a minute recommenced, the cervical veins became overfilled and the œdema progressed to a generalized anasarca with intense cyanosis, which persisted until death on 22/11/41.

Post-mortem Examination. Heart weight 600 g. Parietal pericardium normal. There was a blood-stained pericardial effusion of about 4 oz. The heart was enlarged and grossly distorted by a lobulated tumour growing in the right auricle. When the right side of the heart was opened the whole auricle was filled with large nodules of growth all arising from the auricular wall which was itself thickened with growth (Fig. 1). The tumour was soft and white in colour, but in places there were large hæmorrhages into it. Auricular cavity, almost completely occluded by growth. Right and left ventricles and left auricle, normal except for some distortion caused by pressure of the enlarged right auricle. Pulmonary artery, normal. One nodule of tumour had grown through the inter-auricular wall and was presenting as a red mass in the left auricle about half an inch in diameter. The right coronary vein appeared to be completely occluded by growth. The superior vena cava was filled with clot, which, on dissection, was found to consist of several clots separately attached to the wall of the vein and joined together by post-mortem thrombus.

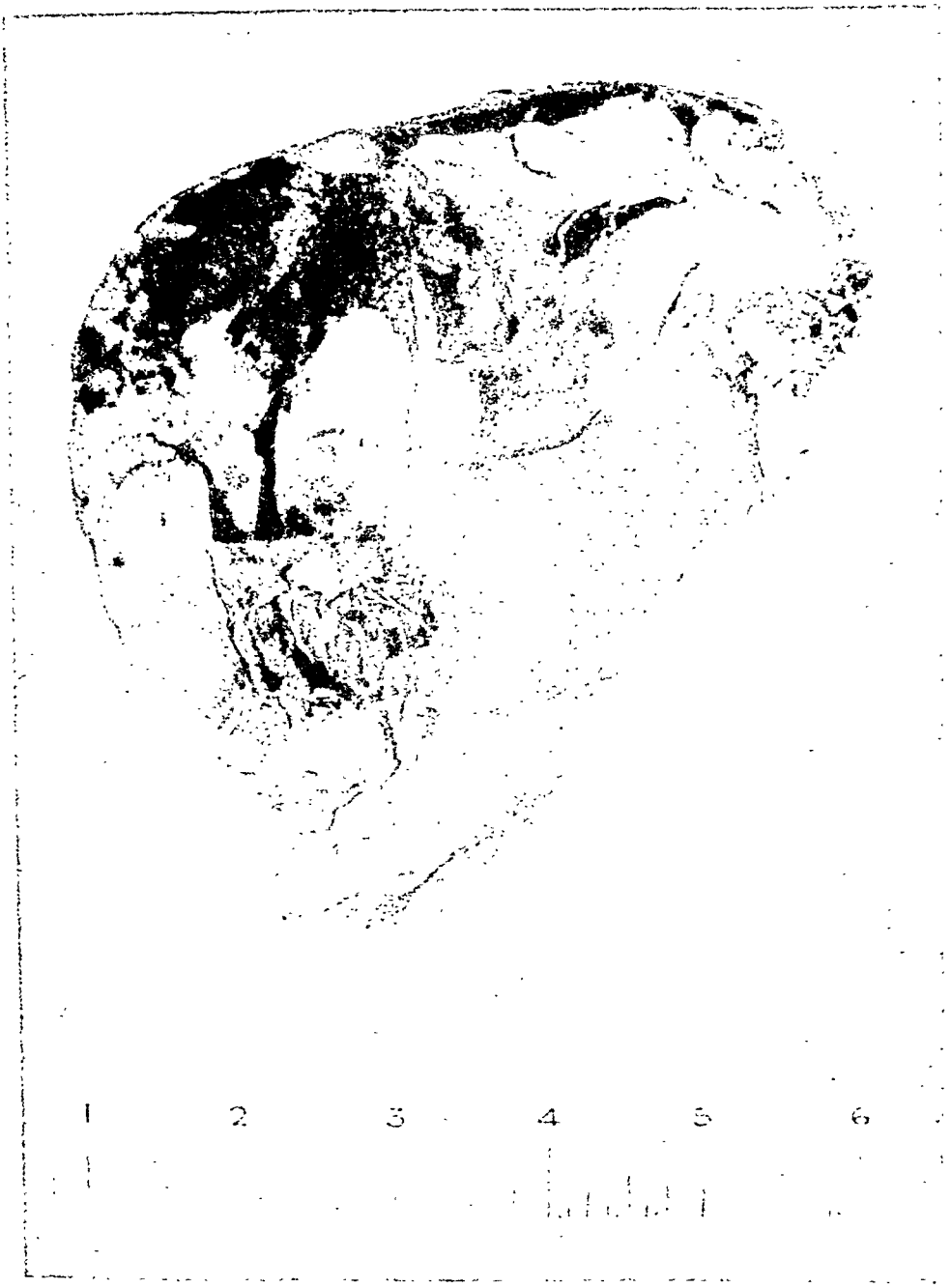

FIG. 1.—Case 1. Heart showing lobulated tumour filling right auricle.

The coronary arteries and aorta were normal. There were small ante-mortem thromboses in both femoral arteries immediately below the inguinal ligament.

Sections.—Heart: cellular growth invading myocardium (Fig. 2). Cells large and mostly round, with scanty eosinophilic cytoplasm. Some strands of

spindle-shaped cells were present. Nuclei, oval or round, with fine chromatin network. There were one or two areas with very large cells with giant nuclei. No true giant cells seen. Sections stained by Van Gieson showed no fibrous tissue. In many sections, stained with Mallory's phosphotungstic acid hæma-

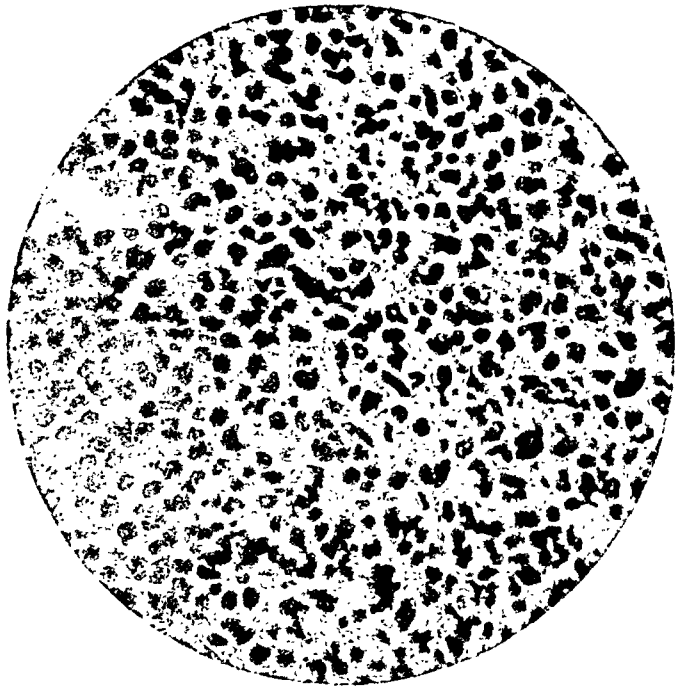

FIG. 2.—Case 1. Section of tumour showing structure. Hæmatoxylin and eosin. Magnification × 350.

toxylin and Heidenhain's iron hæmatoxylin, no cross striation demonstrated in the cells. No evidence of secondary growth in sections of the thromboses in the femoral arteries.

PSEUDO-MYXOMA OF LEFT AURICLE

Case 2. A man, aged 46 years, was admitted with a history of cardiac trouble since the age of 15 when he had influenza. He was always rather short of breath but was able to work until ten days ago when he became increasingly weak and breathless and vomited frequently. He had been treated for gastric symptoms between January and August, 1940, but otherwise had been well in the past apart from a gunshot wound in the neck in the last war. On admission he was extremely blue and dyspnœic with tense neck veins. Cold extremities. No œdema. Pulse 79, weak but regular. Blood pressure not registered (systolic below 90). Heart: grossly enlarged to left; loud apical systolic murmur. Lungs: congestion of both bases, more marked on the right. Abdomen: liver enlarged, almost to umbilicus, and tender. He died two days after admission.

Post-mortem Examination. Heart weight 750 g., grossly enlarged. Peri-

cardium and pericardial cavity normal. There was some hypertrophy of the right ventricle, which was filled with post-mortem clot. The tricuspid valve and the pulmonary valve were normal. Left auricle filled with a large pedunculated yellowish mass which had a short process projecting through the mitral valve into the left ventricular cavity. This mass was attached firmly to the middle wall of the left auricle over an area of about an inch in diameter (Fig. 3).

FIG. 3.—Case 2. Heart showing pedunculated tumour in left auricle.

The mass itself was solid in the lower part, but in the upper part was composed of small attached grape-like structures, which, on section, appeared to be myxomatous. Section of the solid parts showed structure partly laminated, partly hæmorrhagic, and partly amorphous. There was a small process, which was calcified, attached to the part projecting through the mitral valve. The mitral and the aortic valves and the coronary arteries were normal.

Sections.—Composed chiefly of structureless or fibrillary eosinophilic material in which were isolated groups and chords of cells (Fig. 4). In places these cells were flattened, and lined spaces which usually were filled with red

FIG. 4.—Case 2. Section of tumour showing general structure. Hæmatoxylin and eosin. Magnification × 120.

cells. Elsewhere the cells were rounded and had more cytoplasm and generally appeared like swollen connective tissue cells (Fig. 5). There was much iron containing pigment showing a perivascular distribution. Sections stained with thionin showed mucoid degeneration scattered irregularly through the sections.

MYCOTIC ANEURYSM SIMULATING PULMONARY STENOSIS

Case 3. A man, aged 25 years, was admitted on 31/12/41. He had always been quite well until eight months before when he was in a Shropshire hospital for six weeks with rheumatic fever. Shortly after his discharge he was passed fit for military service, " slight heart disease " being noted at the time. Two months later he was re-examined and said to be " cured." Four months before he had been discharged from the army on account of his heart. Six weeks before he had began to have aching in arm and leg joints without swelling, and was treated at home for rheumatic fever. At the same time he began to be short of breath, this symptom steadily increasing up to his admission. He also complained of thirst and had passed less urine than usual. For three days there had been



FIG. 5.—Case 2. Showing a cord of swollen connective tissue cells. Hæmatoxylin and eosin. Magnification × 350.

puffiness of his eyelids with slight headache. On admission he was wasted, with clubbing of the fingers, cyanosis, and dyspnœa, but was able to lie flat. There was puffiness of the eyelids, but no other peripheral œdema. The heart was enlarged to the left, the apex beat being almost out to the anterior axillary line in the fifth space, with a regular tachycardia at 138. Systolic and diastolic murmurs were present at both the mitral and aortic areas. There was a loud rough systolic murmur at the pulmonary area, which was conducted upwards and outwards to the left. A thrill was not felt. The blood pressure was 150/90. The lungs were normal. In the abdomen the liver edge was three inches below the costal margin and was smooth and tender. The spleen was just palpable. There was no ascites. No petechiæ were seen. A diagnosis of pulmonary stenosis with super-added infective endocarditis and perhaps rheumatic carditis was made. The patient died a few hours after admission.

Post-mortem Examination. Heart weight 630 g. Pericardium normal, but a pericardial effusion of about 6 oz. of clear yellow fluid. Both ventricles hypertrophied, particularly the left. Myocardium, pale in colour but not friable. Mitral valve, normal in every respect; no change found in the left auricle. Aortic valve, completely disorganized, cusps adherent and calcified with numerous small beady vegetations all over their surfaces. The orifice of the aortic valve was irregular and nowhere more than one-eighth of an inch diameter. The extreme fibrosis and calcification of the aortic valve had caused distortion of the sinus of Valsalva, and the orifices of the coronary arteries were completely pulled out of place. The anterior wall of the aorta, between the origin of the right coronary artery and aortic cusps, was infected and had given way to form a mycotic aneurysm pushing downwards in the interventricular wall. The cusps of the pulmonary valve were stretched over

the anterior wall of the aneurysm and very much distorted. The aneurysm projected into the right ventricular cavity and gave the appearance of a smooth rounded tumour (Fig. 6). The aorta itself was narrowed, but when it was

FIG. 6.—Case 3. Showing projection of the aneurysm into the right ventricle with distortion of the cusps of pulmonary valve.

opened there was no evidence of atherosclerosis. The distortion of the aortic valve was so great that it was impossible to tell whether it was tricuspid or not. The cavity of the aneurysm was lined by a smooth, shining membrane. In the wall of the left ventricle, at the root of the aorta, there was a cavity about one inch long and half an inch in diameter, filled with creamy blood-stained material. This was apparently an abscess in the myocardium extending directly from the infected anterior cusp of the aortic valve. The cavity of the right ventricle, apart from the distortion caused by the aneurysm, showed no abnormality. The tricuspid valve and the right auricle were normal. There was no occlusion of the coronary arteries.

Sections.—The wall of the aneurysm showed organizing and infected blood clot. The myocardium contained many free cells, macrophages, and polymorphs. There were some perivascular collections of macrophages suggesting the formation of Aschoff bodies.

Discussion

Clinical.—Intracardiac tumour is seldom suspected and less often diagnosed because of the rarity of the lesion and the absence of characteristic signs and symptoms. In adults the commonest findings are those of congestive cardiac failure and cardiac enlargement with or without murmurs suggesting valvular lesions. There may, however, be no signs or symptoms referable to the heart (Bradley and Maxwell, 1928). Other symptoms recorded have been cough, hæmoptysis, weakness, attacks of fainting, præcordial pain, abdominal pain, headache, and vomiting. Œdema is usually general, but may be confined to the face, neck, upper arm, and thorax, suggesting occlusion of the superior vena cava. Various pulse abnormalities have been described, and in two cases there was heart block. Pleural and pericardial effusions often occur and may be hæmorrhagic. The malignant tumours may give rise to secondary growths, presumably blood borne, in the lung, pancreas, intestine, etc. (Muller, 1932).

In fact, the presence of a tumour in the walls or cavities of the heart may simulate all kinds of cardiac disease, and such diagnostic criteria as one can formulate must lie in the very multiplicity of the signs. These may be such that they suggest two separate lesions that are unlikely to occur together, and the presence of even one markedly anomalous sign perhaps should lead one to include "tumour" in the differential diagnosis. In children, of course, the natural diagnosis has been congenital morbus cordis (Farber, 1931), but signs of cerebral sclerosis or other congenital abnormality should lead one to suspect rhabdomyoma of the heart, as this occurs in a large percentage of cases of tuberose sclerosis.

Case 3 particularly shows anomalous features. The signs were those of pulmonary stenosis of marked degree with probably old rheumatic lesions of the aortic and mitral valves and an added infective endocarditis. Pulmonary stenosis is usually congenital, but in this case it had not been discovered at his several previous medical examinations and must have developed within two or three months. The changing nature of the signs recorded by the medical board were in favour of the infective nature of the lesion. Although these

features raised doubts as to the nature of the valvular lesion, further study would probably not have led to an accurate diagnosis of the condition found post-mortem. In Case 1 the successive diagnoses had to be discarded for lack of confirmatory evidence. At the first examination she appeared to be a case of primary polycythæmia, but this could not be supported in face of the blood count. No evidence of syphilis could be found to corroborate a diagnosis of Ayerza's disease, and the lungs were comparatively clear. The peripheral thromboses were insufficient to account for the intense cyanosis. Such a degree of cyanosis should have been accompanied by secondary polycythæmia, or by the early appearance of right heart failure with congestion, or both. However, none of these conditions obtained until the patient was moribund. Had the patient been well enough to have been screened, the gross enlargement of the right auricle might have been demonstrated, and this, in conjunction with the physical signs, might have led to a correct diagnosis. In Case 2, the clinical appearances were those of a single rheumatic lesion of the mitral valve without a definite history of rheumatism. This does occur in both sexes of course, but is more common in females. A similar tumour, arising from the aortic valve and causing sudden death was described by Campbell and Carling (1934).

Pathological.—The chief interest lies in the pseudo-myxoma described in the second case. Nearly 200 primary heart tumours have been described and about half of these fall into the pseudo-myxoma group. The study of their histological features has resulted in two theories relating to their origin. Thorel (1903) and, more recently, Fawcett and Ward (1939) thought they were pedunculated thrombi, which, during the process of organization, underwent a mucoid degeneration that gave rise to their myxomatous appearance. Other observers contend that the tumours are primarily new growths, and each has given them names according to their variations in structure. Thus Rau (1898), Manifold (1915), and Schuster (1914) described cavernous angiomata; Hornowski (1906) and Orr (1942) described endotheliomata; Lloyd (1929) and Armstrong and Monckeburg (1911) described lymphangio-endotheliomata; Fabris (1923) described a fibro-angio-myxoma, and Brenner (1907) a hæmangio-elasto-myxoma. The basic histological structure tends to be constant in all these tumours, and difference of opinion as to their ætiology has arisen from different interpretations of the observed features. The various elements may be present in different proportions giving rise to rather widely varying pictures, but in all cases the matrix of the tumour is the structureless pseudo-myxomatous material. In this are spaces lined by endothelium, which may be large enough to resemble sinuses or as small as capillaries, and all intermediate stages are met with. If the sinus-like spaces predominate, the appearance of angioma is simulated. If instead of spaces, the cells are in rows or columns the appearance is that of an endothelioma. In our case these columns rarely contained more than two rows of cells and looked like strands of young connective tissue growing into the stroma. Scattered throughout the sections, often ranged perivascularly, are areas showing large or small masses of iron containing pigment.

Most observers are agreed that the mucoid tissue is the result of degeneration, but the presence of mucin has been said to denote the epithelial origin of

a tumour, although in these cases the only possible source of mucin would be the lining cells of the vascular spaces; perivascular distribution of the mucin in some of the tumours has been cited in favour of this. The presence of iron is said by some to be due to the breaking down of blood in the thrombus and by others to have resulted from hæmorrhage into the tumour, particularly in the angiomatous types. Elastic fibres have also been described and put forward as evidence of new growth, but Muller (1932) points out that they may occur in well-organized thrombi. The cellular elements have been regarded as neoplastic because in some cases they appear to reproduce differentiated structures such as blood and lymph sinuses, and sometimes appear hyperplastic, i.e. they may be swollen and contain one or two nuclei or may be built up into two or more layers. All these appearances, however, may be met with when young connective tissue cells invade blood clot during the process of organization. We have recently seen a case of mitral stenosis that showed a large plaque-like mass of organizing thrombus adherent to the medial wall of the left auricle, which histologically showed all the above features except that elastic tissue was absent. It would seem, therefore, that organizing thrombus can produce the picture called pseudo-myxoma, and in the absence of definite features, which could be ascribed only to a neoplasm, i.e. the presence of tumour tissue in the heart wall itself, it is reasonable to suppose that they are organizing thrombi.

These tumours usually occur in the left auricle and are often attached in the region of the scar of the foramen ovale. Meroz (1917) collected 40 reports of primary intracardiac tumour, 30 of which were in the left auricle. The surface of the tumours may either be smooth, as in our case, or have a granular appearance. On section the cut surface looks translucent and mucoid, and the outer layers may be composed of laminated blood clot.

Case 1 is a true sarcoma, composed of round and spindle cells. Bradley and Maxwell (1928) have classified 36 cases of primary sarcoma of the heart; 12 were spindle-cell, 10 round-cell, 4 giant-cell growths, 3 myxosarcomatous, and 1 each lymphosarcomatous and angiosarcomatous. These tumours are known to metastasize as in two cases reported by Muller (1932), one with a secondary nodule in the lung, and the other with secondary nodules in the lung, pancreas, and small intestine. This latter case and the case first reported by Bradley and Maxwell (1928) were examples of rhabdomyosarcomata with demonstrable cross striation in some of the tumour cells.

There is yet a third main group of intracardiac tumours, the congenital rhabdomyomata. These are composed of cells similar to embryonic heart muscle (" spider cells "), are often associated with tuberose sclerosis; they are never malignant and often multiple.

From our survey of the reported cases, it would appear that all the cases can be placed into one of the three main groups discussed: i.e.:—

(1) the pseudomyxomata, which for reasons already explained are probably not true tumours but organized thrombi,

(2) the true sarcomata, which may arise from any of the mesenchymal elements in the heart wall, and

(3) the congenital rhabdomyomata (dysontogenetic rhabdomyoma, hamartoma).

The pseudomyxomata form the largest group and comprise nearly half of the tumours described. One quarter of the cases fall into the class of primary sarcoma. Beck and Thatcher (1925) commented on thirty-three reported cases and added one of their own. Nowicki (1926) reported four cases, Matras (1927) one case, and Bradley and Maxwell (1928) and Muller (1932) added one and two cases respectively. The remaining 25 per cent of the cases belong to the category of congenital rhabdomyoma. Farber (1931) found forty-one cases reported, and since then we have only come across two more cases, one described by Ill and Gray (1941) and one by Stewart (1939).

Summary

Three cases of intracardiac tumour are described, a sarcoma, a "pseudomyxoma," and an aneurysm; which in life produced signs and symptoms attributable to Ayerza's syndrome, mitral stenosis, and pulmonary stenosis respectively.

The origin of pseudomyxomata of the heart is discussed. It is suggested that they are not primarily neoplastic but are pedunculated thrombi as all their histological features may be reproduced in organizing blood clots.

A classification of heart tumours is suggested:

(1) Benign tumours resulting from organization of blood clot—pseudomyxomata,

(2) Malignant tumours arising from any of the mesenchymal elements of the heart wall, the true sarcomata, and

(3) Benign congenital tumours arising from developing myocardial elements, the congenital rhabdomyomata (dysontogenetic rhabdomyoma, hamartoma).

Dr. G. H. Jennings kindly gave us permission to publish the clinical details of Case 2. The photographs were taken by Mr. H. D. J. Cole.

References

Armstrong, H., and Monckeburg, J. G. (1911). *Dtsch. Arch. klin. Med.*, **102**, 144.
Beck, C. S., and Thatcher, H. S. (1925). *Arch. intern. Med.*, **36**, 830.
Bradley, E. B., and Maxwell, F. S. (1928). *J. Amer. med. Ass.*, **91**, 1352.
Brenner, F. (1907). *Frankf. Z. Path.*, **1**, 492.
Campbell, M., and Carling, W. R. (1934). *Guy's Hospital Reports*, **84**, 41.
Fabris, A. (1923). *Arch. Path. Anat.*, **241**, 59.
Farber, S. (1931). *Amer. J. Path.*, **7**, 105.
Fawcett, R. E. M., and Ward, E. M. (1939). *Brit. Heart J.*, **1**, 249.
Hornowski, J. (1906). *Zbl. Allg. Path.*, **17**, 773.
Ill, C. H., and Gray, J. W. (1934). *Amer. J. Obstet. Gynaecc.*, **28**, 265.
Lloyd, P. C. (1929). *Bull. Johns Hopkins Hosp.*, **44**, 149.
Manifold, R. F. (1915). *Lancet*, **2**, 1027.
Matras, A. (1927). *Z. H. Kreislauflorsch.*, **19**, 233
Meroz, E. (1917). *Internat. Clin.*, **4**, 231.
Muller, W. (1932). *Virchow's Arch.*, **284**, 105.
Nowicki, W. (1926). *Virchow's Arch.*, **259**, 502.
Orr, J. W. (1942). *J. Path. Bact.*, **54**, 125.
Rau, F. (1898). *Arch. Path. Anat.*, **153**, 22.
Schuster, H. (1914). *Arch. Path. Anat.*, **215**, 335.
Stewart, T. D. (1939). *N. Zealand med. J.*, **38**, 19.
Thorel, C. (1903). *Ergebn. Allg. Path.*, **91**, 901.

GRAHAM STEELL

Graham Steell was one of the three original honorary members of the Cardiac Society. He was born in 1851, and died on January 10, 1942, in his ninety-first year. Happily to the very end, he retained to the full all his mental faculties. When, in recent years, the writer visited him in his London home, he often found him engrossed in a text-book of anatomy or medicine and always eager to discuss recent developments and to recall fascinating memories of his own teachers and contemporaries.

Graham Steell was the youngest son of Sir John Steell, sculptor to H.M. Queen Victoria in Scotland. The monument to Sir Walter Scott in Princes Street, which is familiar to all who have visited Edinburgh, was Sir John's work. Educated at the Edinburgh Academy, Steell's early ambition was to be a soldier; but he was persuaded by one of his brothers, for whom he had a great affection, to take up medicine. He qualified at Edinburgh in 1872, and, after spending the following winter studying in Berlin, became house-physician to George Balfour at the Edinburgh Royal Infirmary. It was doubtless this association with Balfour that was responsible for arousing Steell's interest in cardiology and for determining the field of medicine to which he devoted his life's work and in which he was destined to play such a distinguished part.

Except for a few months as resident medical officer to the Stirling Royal Infirmary, the next four years were spent in fever hospitals in Edinburgh, London, and Leeds, and his thesis for the degree of M.D., for which he was awarded a gold medal, was on scarlatina. Prior to coming to Manchester in 1878 he held the appointment of assistant to Professor (afterwards Sir Thomas) Fraser, in the department of materia medica and therapeutics at Edinburgh University.

In 1883, after serving for five years as resident medical officer, Steell was appointed assistant physician to the Manchester Royal Infirmary, to which institution and its patients he gave devoted service until his retirement from the active staff and from the university chair of clinical medicine at the age of sixty.

Amongst his testimonials for this post are many from distinguished men, including William Roberts, Thomas Fraser, William Broadbent, George Balfour, Daniel Leech, Lauder Brunton, Clifford Allbutt, James Ross, F. A. Mahomed, and William Turner. In his testimonial Mahomed wrote, " His modest retiring and courteous disposition must gain the highest esteem of all who have the privilege of knowing him well." The present writer, who had that privilege thirty years later, can find no words that would more aptly describe his character: in fact, his modesty and courtesy would have been almost embarrassing to his younger friends had they not realized the true-hearted kindness that lay below.

In view of his extensive experience in fevers, it is not surprising that many of his early papers were devoted to this subject, but from 1886 onwards, with the exception of occasional excursions into the adjacent pulmonary field, all but two of his publications dealt with cardiology.

His text-book on *Diseases of the Heart*, published in 1906, never achieved the popularity it deserved. In a letter of thanks for a presentation copy, Mackenzie wrote, " Many congratulations on your excellent handbook, and many thanks for the copy. I have been eagerly devouring it, and I have no hesitation in saying it is by far the best book on the heart on the market. Your remarks are so pungent and pithy that it is a delight to read."

This book was no mere compilation of current doctrine: the views expressed were based on the author's own clinical and pathological observations, the full significance of some of which was not apparent until many years later. For example, in reference to œdema he wrote:

> " Capricious distribution of dropsy is specially apt to occur in cases of the cardiac muscle-failure of beer-drinkers and of the disease known as beri-beri, of both of which diseases, it is curious to note, peripheral neuritis is a clinical feature. . . . Curious special localizations of œdema met with, in cases of the kind, have been the scrotum, and together the upper trunk, upper extremities, and scalp and neck, so that the œdema simulates that resulting from mediastinal tumour."

We now know that this type of heart failure, and the peripheral neuritis with which it is often associated, are due to vitamin B_1 deficiency: hence the relation that puzzled Steell, between beri-beri and chronic alcoholism.

Another problem that puzzled him was the occasional association of transient pericardial friction with angina pectoris. His paper recording these observations was published many years before the clinical syndrome of coronary thrombosis was recognized in this country.

The murmur of pulmonary incompetence that bears Steell's name was first described by him in a paper read to the Manchester Medical Society and afterwards published in the *Medical Chronicle* in 1888. He wrote as follows:

> " I wish to plead for the admission among the recognized auscultatory signs of disease of a murmur due to pulmonary regurgitation, such regurgitation occurring independently of disease or deformity of the valves, and as the result of long-continued excess of blood pressure in the pulmonary artery.
>
> " In cases of mitral obstruction there is occasionally heard over the pulmonary area (the sternal extremity of the third left costal cartilage), and below this region for the distance of an inch or two along the left border of the sternum, and rarely over the lowest part of the bone itself, a soft blowing diastolic murmur immediately following, or, more exactly, running off from the accentuated second sound, while the usual indications of aortic regurgitation, afforded by the pulse, etc., are absent. The maximum intensity of the murmur may be regarded as situated at the sternal end of the third and fourth intercostal spaces. When the second sound is reduplicated, the murmur proceeds from its latter part. That such a

murmur as I have described does exist, there can, I think, be no doubt. . . . The murmur of high pressure in the pulmonary artery is not peculiar to mitral stenosis, although it is most commonly met with as a consequence of this lesion. Any long-continued obstruction in the pulmonary circulation may produce it. The pulmonary valves, like the aortic, do not readily become incompetent, apart from structural changes. Probably no amount of blood pressure in the pulmonary artery will render them so suddenly, as, at least theoretically, the mitral valves may be rendered incompetent. Changes in the vessel, with widening of its channel, and, eventually, of its orifice, long precede the occurrence of incompetence of its valves. The pulmonary murmur of high pressure is probably never persistent at first, and one of its most remarkable features is, as a rule, its variableness in intensity. On some days it will be distinctly heard, on others it will be indistinct, or even inaudible; while extreme accentuation of the pulmonary second sound is always present, the closure of the pulmonary semilunar valves being generally perceptible to the hand placed over the pulmonary area, as a sharp thud. This non-persistence of the murmur, in the earlier stages, at any rate, is only what the study of dilatation of the aorta and the consequent regurgitation would lead us to expect. Indeed, so common is a soft blowing murmur, after an accentuated aortic second sound, that extreme accentuation should make us listen, with special care, for a murmur, and even though it be absent on the first occasion the search should not be abandoned. My belief is, that when the aortic second sound is extremely accentuated, regurgitation, to some extent, will probably occur sooner or later. Its supervention in aneurysm of the first part of the arch of the aorta is a familiar fact. Post-mortem, enlargement of the left ventricle, in these cases, may be a better indication of regurgitation having occurred during life than the usual test of filling the cut aorta with water, a proceeding which cannot imitate the action of the forcible blood currents in the living body. An accentuated second sound is no way incompatible with a certain amount of incompetence of the semilunar valves; on the contrary, an accentuated second sound, associated with a regurgitant murmur, is clinically common."

In addition to his text-book and numerous original papers in scientific journals, Steell published three small monographs devoted to the *Physical Signs of Cardiac Disease* (1881), the *Physical Signs of Thoracic Disease* (1900), and *The Use of the Sphygmograph in Clinical Medicine* (1889). The sphygmograph had always fascinated him, and he made a practice of taking pulse tracings from all his cardiac patients. From references to this subject in their correspondence it is evident that these records were of great interest to Mackenzie who, when in practice in Burnley, used often to go round Steell's wards in the Manchester Royal Infirmary. Two men outwardly more different it would be hard to imagine, but they were close friends and had the highest regard for each other's work.

Although keenly interested in auscultation (he always used a monaural stethoscope made of box-wood with a bell-shaped earpiece), Steell laid great

stress on disease of the heart muscle rather than of the valves as the factor of primary clinical importance. His "master," Balfour, had coined the term "curable mitral regurgitation" to distinguish the mitral incompetence associated with conditions such as chlorosis from the "mitral disease" due to a damaged valve. This conception greatly appealed to Steell, and in the preface to his book he wrote:

> "No mitral valves can be competent if they fail to receive that assistance from the heart muscle that they were designed to receive in the performance of their function."

In 1911 Steell delivered the Bradshaw lecture at the Royal College of Physicians. His subject "*Intra-thoracic Tumours and Aneurysms in their Clinical Aspect*" was one that had interested him deeply for many years and afforded ample scope for his special talents. He was at his best as a bedside teacher when demonstrating the physical signs of intrathoracic disease and considering their interpretation.

Steell was a lover of animals, and a staunch advocate of physical exercise: himself a boxer in his youth and later a keen horseman, he often recommended riding as the best form of exercise for those of his cardiac patients whose disability was slight. He was the last Manchester consultant to keep a brougham and pair. In a letter to the writer in 1931, he said, "For the last ten years and more the importance of exercise in the treatment of heart troubles has been more and more borne in upon me and, in my own case, I have more and more made application of it. . . . The beginning of my heart troubles was in 1898: an extreme irregularity and frequency of the pulse, which went on continuously for weeks. I have normally regarded this as auricular fibrillation, but your paper raises doubts in my mind. Your phrase 'showers of extrasystoles' at any rate appeals to me in a way impossible to anyone who has not gone through experience of such a condition." In addition to heart trouble he had more than his fair share of the diseases he knew so well. In his young days he contracted both typhoid and typhus, and in 1888 he was off work for some months, tubercle bacilli having been found in his sputum.

After the last war Steell retired from practice and went to live with his son, who was for a time in practice in Derbyshire and who later became a medical officer of the Ministry of Health, first in Newcastle and subsequently in London. The writer well remembers the concern of his son, when one day he discovered the old man embarking on an original research on the colour sense of young bullocks by waving a red handkerchief at them in the field adjacent to his house!

He married in 1886 Agnes Dunlop McKie, who was Lady Superintendent of nurses of the Manchester Royal Infirmary. She died in 1910. They had one son, to whom the writer is indebted for the great privilege of having enjoyed the friendship of Graham Steell.

CRIGHTON BRAMWELL.

HEMIPLEGIA IN CYANOTIC CONGENITAL HEART DISEASE

BY

BERYL CORNER AND BRUCE PERRY

From the Department of Medicine, University of Bristol, and the Bristol Children's Hospital

Received May 22, 1942

Although the cases to be described lack any anatomical observations, the association of uncomplicated cyanotic congenital heart disease with the sudden onset of hemiplegia appears worthy of record. All three cases have only recently come under our observation.

NOTES OF CASES

Case 1.—J. L. was first seen at the age of eight months. He was a first child, and because of the mother's "kidney trouble" the pregnancy was terminated three weeks early. Shortly after birth it was noticed that the hands and feet went blue at times and that when crying he appeared to get unduly out of breath. He had gained weight satisfactorily. On examination there was no marked cyanosis and the only clinical abnormality was a loud central systolic murmur. On X-ray, there was a heart shadow suggesting the tetralogy of Fallot. A month later he was admitted to Southmead Hospital because, following a particularly intense attack of cyanosis and dyspnoea five days before, it was noticed that the right arm and leg did not move normally and that on crying the face was drawn over to the left side. On admission there was a right hemiplegia. The cardiac physical signs were unchanged, there was no fever, and no other abnormality was found. He continued to have attacks of cyanosis of varying severity. A lumbar puncture a week after admission was blood-stained—apparently traumatic—but otherwise normal. A blood count showed 6,000,000 red cells with a haemoglobin of 90 per cent. Since then there has been no change.

Case 2.—D. B. was born normally and was found to have congenital heart disease at the age of three months. He progressed favourably except for attacks of cyanosis until the age of eleven months, when loss of power in the right arm and leg was noticed a week after an attack of bronchitis. He was admitted to hospital the next day and found to have a right hemiplegia. The cerebrospinal fluid two days after the onset showed 6 lymphocytes per c.mm. and 50 mg. of protein per 100 c.c. Ten days later this was normal. There

was a mild pyrexia for three weeks. Since then the child has remained the same. There is constant cyanosis with exacerbation in attacks. There is dextrocardia with a basal systolic murmur. X-ray examination shows a boot shaped heart with dextrocardia. Electrocardiogram shows right axis deviation when allowance is made for the dextrocardia. A recent blood count shows 9,000,000 red cells with a haemoglobin of about 160 per cent. This is probably a case of the tetralogy of Fallot with dextrocardia.

Case 3.—M. W. was first seen at the age of nine years. He is deeply cyanosed with a soft basal murmur. X-rays show a rather boot shaped heart with a small pulmonary arc. His electrocardiogram shows marked right axis deviation. He has 7,000,000 red cells per c.mm. and a haemoglobin of 140 per cent. The X-ray picture suggests that this may be a case of Fallot's tetralogy but the murmur is so soft as to raise doubts about this diagnosis. When first seen he had a right hemiplegia which was at first regarded as congenital. However, on further enquiry his mother states that this was first noticed at the age of eight months, after a week's illness in which he "seemed dazed."

Discussion

This syndrome was entirely new to us, and the only references found in the literature are the cases reported by Ford (1937) and the case recently reported by Wood (1942).

Ford's first case was a mentally defective child dying at the age of two and a half of pneumonia. He exhibited athetoid movements at the age of twelve months and the colour is said to have been "dusky." Post-mortem, there was a patent ductus arteriosus and a patent interventricular septum. The left middle cerebral artery showed an old thrombosis, partly recanalized, with an infarct involving the motor cortex and part of the temporal lobe and extending into the internal capsule and lenticular nucleus.

His other case was a child, blue from birth, who at ten months showed a basal systolic thrill and murmur and a red cell count of 7·5 millions. At two years of age he suddenly became stuporous and developed a left hemiplegia. A few days later he became more comatose and showed a bilateral extensor plantar response. He died shortly after. Post-mortem, there was atresia of the pulmonary artery, patent interventricular septum patent foramen ovale, and cardiac hypertrophy. There was a thrombosis of the right middle cerebral artery with infarction, and a later thrombosis of the superior longitudinal sinus and a small infarct involving part of the left motor cortex.

Wood's patient had been cyanosed from birth. There was no definite history of the onset of hemiplegia, but this apparently developed in infancy, since she had never walked and did not sit up until two years of age. Post-mortem, there was no gross vascular lesion but degenerative changes apparently due to the intense congestion. Bodechtel (1932) has described changes in the brain in congenital and acquired heart disease, apparently due to anoxaemia, but these changes would hardly appear sufficient to produce hemiplegia.

Ford attributes these thromboses to the polycythaemia and compares this with the cerebral thrombosis that may complicate polycythaemia vera in the adult. However, in our first case the polycythaemia was slight, and in Ford's first case the cardiac malformation should have produced little cyanosis except with the terminal pneumonia.

Since Wood's case showed no actual occlusion it appears that the brain lesion associated with cyanotic congenital heart disease may be produced in at least two ways. Obviously the possibility of embolism must be considered, but it would appear likely that if this were the cause, emboli elsewhere would have been observed. The possibility of a superimposed bacterial endocarditis seems to be excluded by the subsequent history. The actual pathology of the cases here reported must remain uncertain.

Summary

Three cases of cyanotic congenital heart disease developing sudden hemiplegia in infancy have been described. The possible mechanism of this has been discussed.

We are indebted to Dr. R. M. Norman for drawing our attention to the observations of Bodechtel.

References

Bodechtel, G. (1932). *Z. ges. Neurol. Psychiat.*, **140**, 657.
Ford, F. R. (1937). *Diseases of the Nervous System in Infancy, Childhood, and Adolescence. London.*
Wood, P. (1942). *Brit. Heart J.*, **4**, 11.

CONGENITAL PULMONARY ATRESIA WITH CEREBRAL THROMBOSIS AND HEMIPLEGIA

BY

ALASTAIR HUNTER AND JOHN M. LIPSCOMB

From the Cardiac Department of the London Hospital and the Bernhard Baron Institute of Pathology

Received July 7, 1942

In view of the recent communication of Corner and Bruce Perry (1942) the following case is of special interest.

A girl, aged 19 (Fig. 1), was first seen on February 21, 1942, when she was admitted to the London Hospital for dental extractions. Since the age of 2 she had been under observation for " heart trouble " with blueness and swollen fingers. Her activities had always been limited by shortness of breath, although for the last three years she had been capable of light work in the home. There had been no faints or cerebral attacks, and there was no history of congenital heart disease in parents or siblings.

She was a tall and well-developed girl with purple cyanosis; this was general, but most striking on the cheeks and lips, as well as in the fingers and toes, which were grossly clubbed. The pulse was regular and of good volume. The apex beat was palpable in the fifth space in the mid-clavicular line, and there were no thrills. Normal heart sounds were heard in all areas, and there was a diffuse systolic murmur of only moderate intensity, maximal in the pulmonary area and below it. The blood pressure was 120/80. There were scattered rhonchi over both lungs and slight lumbar œdema, but no other signs of heart failure.

Radiological examination showed much enlargement of the cardiac outline to the left, probably of the right ventricle, as it was of a *sabot* shape. There was a deep concavity in the pulmonary artery region and only slight hilar shadows (Fig. 2). The blood count showed: red cells, 7,160,000; white cells, 6120; hæmoglobin, 136 per cent (Sahli); and hæmatocrit readings, 65 and 75. A diagnosis of congenital pulmonary atresia was made by Dr. William Evans who noted the limited cardiac signs despite the great cyanosis.

Dental extractions were performed uneventfully under gas and oxygen anæsthesia. Venesection on three occasions had no effect upon the patient's condition or blood picture. She was discharged on March 14. On April 2 she was readmitted after an epileptiform fit preceded by difficulty in speech and loss of power in the left side of the face and left arm. The general appearance was unaltered unless the cyanosis was deeper, and there was now orthopnœa.

The temperature was 102 and the pulse rate 88. The cardiac signs were unchanged. There was drowsiness, slurring of speech, and neck rigidity. Slight left facial weakness of upper motor neurone type was combined with flaccid weakness of the left arm with absent tendon reflexes. These were the only abnormal signs in the nervous system. After admission the patient had several minor, and one major, epileptiform attacks. Lumbar puncture showed a yellow C.S.F. under pressure of 230 mm. It contained red cells (800 per

FIG. 1.—Photograph of patient showing cyanosis and clubbing of fingers.

c. mm.), no excess of white cells, and protein 30 mg. per 100 c.c. In subsequent days she improved, the nervous symptoms and signs disappeared, and she was fit to get up. But one month after admission she developed a sudden pain under the left costal margin with fever, attributed after necropsy to a paradoxical splenic infarct. The spleen was never felt, but great œdema of both lower limbs with tenderness in the groins indicated spreading iliac thrombosis. The general condition deteriorated and she died in coma on May 13, 1942, eight days after the final thrombotic illness.

Summary of Necropsy (Dr. W. W. Woods)

Heart failure. Thrombosis in cerebral and pelvic veins. Congenital atresia of orifice of pulmonary artery. Patency of interventricular septum. Enlargement of bronchial arteries.

Small pulmonary artery (1·3 cm. long; 1·3 cm. circumf.) starting from a blind end at upper margin of right ventricle and dividing into very thin-walled right and left pulmonary arteries (each 1·8 cm. circumf., with wall less than 0·05 cm. thick), which go into hila of lungs. No trace of conus arteriosus or pulmonary valves on inner surface of right ventricle (Fig. 3). Patency (3 cm. diam.) of upper end of interventri-

Fig. 2.—Teleradiogram, showing *Cœur en Sabot* and deep pulmonary bay with small hilar vessels.

cular septum immediately below anterior cusp of aortic valve and not involving pars membranacea septi. Greatly enlarged, very thin, almost transparent, right bronchial artery (2·5 cm. circumf.) arising (orifice 1 cm. diam.) from the aorta immediately beneath the level of the closed ductus arteriosus (Fig. 4), its three branches going to the three lobes of right lung. Upper left bronchial artery (0·5 cm. circumf.) arising from aorta, 0·7 cm. below the right, by an incongruously wide orifice (1 cm. diam.) and entering hilum of left lung. Lower left bronchial artery (1·2 cm. circumf.), with thin, almost transparent wall, arising (orifice 0·5 cm. diam.) from aorta 0·7 cm. below upper, and entering lower part of hilum of left lung. Foramen ovale and ductus arteriosus closed. Great hypertrophy of right ventricle (2 cm. thick), forming apex of heart. Small left ventricle (1 cm. thick). Normal pulmonary veins entering left auricle. Aortic orifice 9·5 cm. in circumference. Three abnormally large aortic cusps (width, upper edge, 4 cm.; depth, 2 cm.). Slight fibrous thickening of free margin of tricuspid valve and of free margins of aortic cusps. Large coronary arteries (right 1 cm., anterior descending 1·5 cm. circumf.). Slight atheroma of aorta. No atheroma of

FIG. 3.—Right ventricle opened, showing:

(A) Ventricular septal defect.
(B) Hypertrophied wall of right ventricle.
(C) Site of pulmonary atresia.
(D) Tricuspid valve leading to right auricle.

FIG. 4.—Aorta opened, showing:

(A) Dilated orifices of (upper) one right and (lower) two left bronchial arteries, maintaining pulmonary circulation.
(B) Normal intercostal arteries.
(C) Aortic valve.

bronchial arteries. Emphysema and moderate œdema of lungs. Very great dilatation of large left (1·2 cm. diam.) and right (1·7 cm. diam.) superior anastomotic vein of Trollard, posterior anastomotic vein of Labbé, and superficial Sylvian vein. These veins on right and a few tributaries of the right vein of Trollard filled with firm ante-mortem thrombus (Fig. 5). Canalized occlusion of termination of left superficial Sylvian vein. Cavernous and circular sinuses unfortunately not carefully examined during removal of pituitary body. No thrombosis nor dilatation of superior longitudinal and lateral sinuses. No petechiæ nor softening in horizontal sections of right cerebrum. Considerably adherent ante-mortem thrombus filling right common iliac vein and upper end of right external iliac. Less adherent ante-mortem thrombus filling left common iliac vein. Non-adherent ante-mortem thrombus filling lower fourth of inferior vena cava. More recent ante-mortem thrombus in femoral veins. Moderate œdema of left leg; slight of right. Recent ante-mortem thrombus in very dilated veins (0·6 cm. diam.) in myometrium of fundus of uterus, in parts of very conspicuous plexus of veins in each broad ligament, throughout dilated right ovarian vein and in lower end of dilated left ovarian vein. Bicornuate uterus. Softened anæmic infarct (7×3 cm.)

in œdematous, congested spleen, presumably due to an embolus from a thrombosed vein having crossed through the patent interventricular septum. Lightly adherent thrombus riding bifurcation of aorta, probably also a crossed embolus. Congestion and nephrosis of large, lipoid-flecked, kidneys. Diffuse congestion of liver, stomach, pancreas, and bladder.

Microscopical Examination

The brain and portions of kidney and lung were placed in 4 per cent saline formaldehyde. In the time available it was possible only to stain frozen sections by Herxheimer's method and to embed tissue in paraffin by a rapid method, using the exhaust pump, and to stain with hæmatoxylin and eosin, Weigert's iron hæmatoxylin with van Gieson, Weigert's fuchselin with neutral red, and by Lenhossek's method for Nissl bodies.

Brain. A horizontal segment was taken from the right cerebrum, where above the sharp anterior bend of the vein of Trollard a piece of the post-central gyrus is exposed (Fig. 5). The segment included the thrombosed vein, the post-central gyrus, the

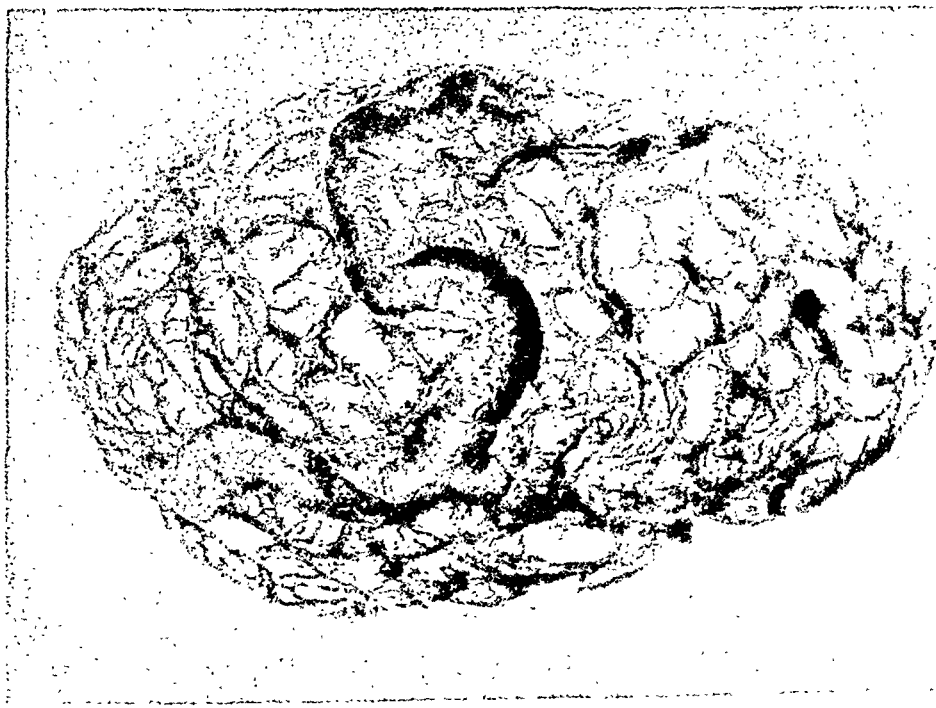

FIG. 5.—Right hemisphere; enlarged, thrombosed superior anastomotic vein of Trollard and posterior anastomotic vein of Labbé, joining superficial Sylvian vein. The anterior end is to the right, and the brain has been tilted so that the anterior and upper parts are more prominent.

inferior post-central sulcus, and the pre-central gyrus near the junction of its upper and middle thirds. Two other segments were taken from the inferior frontal gyrus, 3 and 3·5 cm. from the anterior pole, one for Herxheimer's method and one for rapid paraffin embedding.

The clot in the vein of Trollard is red, with a few small mixed areas. In its outer margin are scattered pigment granule cells, while early organization is shown by capillaries and a few fibrocytes. There is partial thrombosis of a vein deep in the

inferior post-central sulcus. The pia-arachnoid over the vein of Trollard and extending over the greater part of the summit of the post-central gyrus is greatly infiltrated with free, round endothelial cells; some contain pigment. In a narrow zone immediately above the vein are numerous neutrophil leucocytes. The pia in the inferior post-central sulcus is fibrosed, containing numerous fibrocytes, and is infiltrated chiefly with lymphocytes but also with monocytes, epithelioid cells, and a few neutrophil leucocytes and pigment granule-cells. Where the centre of the convexity of the vein is opposite the post-central gyrus the adjacent cortex, including the layer of small pyramidal cells, is densely infiltrated with rod and other apparently microglial cells. Similar cells extend in decreasing number to the polymorphic layer. In this anterior part of the gyrus, and to a less degree in the posterior, there is an obvious excess of small round, apparently oligodendroglial, cells about neurons, especially in the deeper layers. In the pre-central gyrus there is conspicuously less cellularity but the satellite cells in the deeper layers appear to be in excess of those in the prefrontal section. Even in the post-central gyrus few of the pyramidal cells have lost their shape and in the pre-central gyrus they are well shaped and do not differ from those in the prefrontal region. The nuclei of neurons are central, though the nucleoli are occasionally peripheral. The Nissl bodies are almost always finely granular and indistinct, though larger fused masses are occasionally seen in the periphery of the cytoplasm and most of the Betz cells contain deeply stained rounded masses. In the prefrontal section, however, Nissl bodies show similar changes, so that their condition everywhere is probably due to post-mortem change or rapid fixation and embedding. The conspicuous perivascular, perineuronal, and pericellular spaces of His demonstrate faulty fixation or embedding. There are no hæmorrhages. There are no fat granule-cells in the Herxheimer sections, which do not, however, include the thrombosed vein and the post-central cortex immediately to its side.

Kidneys. Greatly congested; glomeruli, large with considerable proliferative glomerulitis. Three glomerular adhesions were found, and there is early fibrosis and infiltration with lymphocytes and an occasional neutrophil leucocyte round a few glomeruli or about their afferent vessels. In the interstitial tissue a few spindle cells and small groups of foam cells contain lipoid; lipoid is present less often in cells of first convoluted tubules.

Lung, right lower lobe. Congested and emphysematous; emphysema severe and chronic, and alternating with scattered patches of partial collapse, in which the alveoli usually contain a coagulated exudate. No bronchiolitis. Pulmonary arteries well developed.

Discussion

Pulmonary atresia is an uncommon defect, Abbott (1936) finding 40 examples in 1000 confirmed cases of congenital morbus cordis. We have examined the necropsy reports of the London Hospital, covering a period of 31 years, and found 355 cases of congenital morbus cordis, other than those showing patent foramen ovale alone; among these were 16 cases of pulmonary atresia. Two main types are described, those in which the interventricular septum is closed and the pulmonary circulation is maintained by way of a patent foramen ovale, a dextroposed aorta, and a patent ductus arteriosus; and those in which the interventricular septum is perforate. The prognosis is different, being far worse in the first type with an average duration of life of 3 months and a maximum of 6 months, against an average of 3·4 years with a maximum of 13 years in the second type, as given in Abbott's (1928) series of 31 cases. Harrison (1929)

comments on the relatively favourable prognosis where the interventricular septum is patent, and cases, aged 33 and 30, have been reported by East and Barnard (1938), and Bach (1928), respectively. The collateral circulation in this type has been fully discussed by Harrison (1929), who emphasized the importance of the bronchial arteries in maintaining it when the ductus arteriosus was closed, and gave references. This was recently noted in two cases by East and Barnard (1938), and it was a feature in our case, where incidentally the aorta sprang normally from the left ventricle and was not dextroposed.

The bronchial arteries normally arise from the aorta or intercostal arteries and supply the lung tissue (Gray's Anatomy, 26th edition, 1935). They vary in number from one to three for each lung, generally with two on the left and one on the right, and with an anastomosis between these vessels and the branches of the pulmonary artery. The compensatory circulation may also be maintained by a patent ductus arteriosus, by the mediastinal, œsophageal, and other branches of the aorta, or by anomalous vessels arising from the subclavian and thyroidea ima arteries (Abbott, 1932).

The diagnosis of pulmonary atresia cannot always be made during life as the syndrome of gross cyanosis and clubbing of the fingers, with the *cœur en sabot* of right ventricular enlargement resembles closely the commoner form of Fallot's tetralogy where there is stenosis, not atresia. If a harsh systolic murmur and thrill in the pulmonary area are added the distinction seems impossible. But sometimes, where the septal defect is large, as in our case, the murmur is slight and the thrill absent; this should suggest the diagnosis.

Cerebral manifestations in pulmonary atresia and stenosis are well recognized. They have been attributed either to paradoxical embolism, or to cerebral thrombosis associated with the polycythæmia. We here record hemiplegia and epileptiform attacks which were shown at necropsy to be due to cerebral thrombosis. Their transient nature may be explained by the absence of softening of the brain although there was such extreme distension and thrombosis of the cerebral veins (see Fig. 5).

We are glad to acknowledge the kindness of Professor H. M. Turnbull, F.R.S., and Dr. W. W. Woods of the Bernhard Baron Institute of Pathology in furnishing us with the detailed necropsy report, and with Fig. 5. Professor Turnbull has kindly permitted reference to past records.

Dr. A. E. Clark Kennedy, Physician to the London Hospital, was good enough to allow us to publish this case which was admitted under his care, and Dr. William Evans has helped us in the Cardiac Department.

References

Abbott, M. E. (1928). *Blumer's Bedside Diagnosis*, Vol. II.
—— (1932). *Nelson's Loose Leaf Medicine*, 4, 207–321.
—— (1936). *Atlas of Congenital Cardiac Disease*, New York.
Bach, F. (1928). *Lancet*, 1, 1009.
Corner, B., and Perry, B. (1942). *Brit. Heart. J.*, 4, 120.
East, T., and Barnard, W. G. (1938). *Ibid.*, 834.
Harrison, W. F. (1929). *Amer. Heart J.*, 5, 212.

PARTIAL HEART BLOCK DUE TO DIGITALIS

BY

MAURICE CAMPBELL

From Guy's Hospital and the National Hospital for Diseases of the Heart

Received June 24, 1942

Amongst a series of cases of partial heart block, collected over a period of years, there were some in which treatment with digitalis was mainly or partly responsible. This group involves some special problems that seem worth separate consideration.

The slow pulse, even as slow as 35 in a minute, after the administration of digitalis was one of the original observations of Withering (1785). Much later, but for many years now, it has been recognized that heart block was the cause of the slowest heart rates after digitalis, though some lesser degree of slowing might be due to a direct or vagal effect on the S-A node. According to Cushny (1925, p. 220) the effect of digitalis on the A-V bundle is partly inhibitory through the vagus nerve, but partly, and sometimes mainly with full or long digitalization, a direct effect on the muscle of the A-V bundle.

The slow pulse after digitalis has even passed into literature and, if Mary Webb can be trusted, into the folk-lore of Shropshire and the Welsh border:

> "I suppose a dose of foxglove ud put her right, maybe?"
> "Ah! Foxglove'll lower the pulse as quick as anything. But you mun be careful. Dunna give her too much. When things get old and worn out they canna stand much of it." (Mary Webb (1924), Precious Bane.)

Mackenzie (1905, *b*) pointed out that those who already had partial heart block, as shown by a long a-c interval, were more susceptible to this effect of digitalis and were more likely to develop a recognizable degree of heart block. This is confirmed by the present study.

This series was obtained by looking through 10,000 consecutive electrocardiograms taken at Guy's Hospital during the twelve years 1927–38, and adding all others I had remembered to index. There were 141 cases with a prolonged P–R interval but no higher degree of block; and the term latent is used as a convenient one to describe this, since it is a true subdivision of heart block that is only made manifest by instrumental methods. There were 29 which also had, at times, partial heart block with dropped beats.

In 26 of these 170, treatment with digitalis was the sole or an important cause of the heart block, and in another 6 it may have been the cause. However, these digitalis cases were not equally distributed: as many as 38 per cent of those with dropped beats were due to digitalis or similar drugs (Table I), but

only 14 per cent of those with latent heart block (26 per cent of those with a P–R interval of 0·26 sec. or more, and 12 per cent of those with it between 0·25 and 0·20 sec.)

TABLE I

HEART BLOCK CAUSED BY OR INCREASED BY DIGITALIS

	Total number of cases	Number due to or increased by digitalis (*a*)	Number possibly due to digitalis (*b*)	Percenta due to digitalis (*a*) and (*b*)
Partial heart block with dropped beats	29	11	0	38
Latent heart block—				
(*a*) P–R, 0·26 and above ..	31	7	1	26
(*b*) P–R, 0·20–0·25 sec. ..	110	8	5	12
	170	26	6	19

To write of digitalis without discussing auricular fibrillation is of course to leave out its most important use. The high degree of heart block that is often produced is well known; but here we are not concerned with this aspect of digitalis overdosage.

CASES WITH DROPPED BEATS

The eleven cases with dropped beats are summarized in Table II, and short notes of two of them follow to give more illustrative details.

Case 2. A man, aged 24, with a large heart and mitral stenosis, was admitted to hospital for his second attack of congestive failure. His P–R interval at various times without digitalis was 0·23–0·25 sec. He was given 30 minims of tincture of digitalis daily from May 8 to 31, when block was noted, and four days later there was still 2:1 heart block, partial heart block with dropped beats, and sino-auricular block (Fig. 1). Many records were obtained and the average results are shown below.

2:1 heart block:	P–R,	0·25 (almost his normal), dropped beat.
3:2 block:	P–R,	0·24, 0·33, d.b.

Single records of lesser degrees of block are shown below.

4:3 block:	P–R,	0·25,	0·31,	0·39,	d.b.			
5:4 block:	P–R,	0·25,	0·31,	0·36,	0·39,	d.b.		
6:5 block:	P–R,	0·26,	0·31,	0·35,	0·39,	0·42,	d.b.	
7:6 block:	P–R,	0·25,	0·29,	0·32,	0·36,	0·39,	0·42,	d.b.

On May 24 his P–R interval had been 0·25 sec., and on May 26 and May 28 his temperature, which had been normal, rose to 100·6° F., suggesting that a return of active carditis was the decisive factor in bringing about his heart block on May 31. His recovery was uneventful and twelve days later the P–R interval had returned to 0·25 sec.

Case 4. A woman, aged 68, had congestive heart failure and high blood pressure. Treated with 45 minims of tincture of digitalis daily, her pulse rate, which had been 100–80 on admission, was charted at under 50 on the tenth day, and digitalis was stopped. Dropped beats were recorded, generally with the sequence: P–R, 0·23 sec., 0·31 sec., d.b., etc. The heart rate remained about 50 for ten days, and that day

FIG. 1.—Dropped beats after 2, 3, 4, 5, and 6 responses with a lengthening P–R interval. The auricular waves are marked with a dot (·); in three of the longer pauses (marked with a cross) and perhaps in a fourth there is also sinoauricular block. The auricular rate was about 60. In some other records 2:1 heart block was the most usual finding. The time marker is not visible in this print and has been marked on in seconds and fifths. (Case 2).

dropped beats were again recorded with the average sequence of P–R, 0·21 sec., 0·41 sec., d.b., etc. After another seven days, during which the heart rate was regularly over 80, she was started again on digitalis—this time 2 grains of the leaf daily—and took this regularly, the P–R interval remaining just below 0·21 sec., as at first. It is strange that so little digitalis should have produced this and probably infection was the extra cause (see page 135).

DISCUSSION OF CASES WITH DROPPED BEATS

All these eleven patients had dropped beats, developing as the first sign of over-digitalization or quickly after this, and disappearing within a few days when it was stopped. Sometimes the dropped beats were only observed for a day or two so that we did not obtain a cardiogram, the patients being under the care of various physicians in different wards. Most often the dropped beats persisted, for from three to five days, and in one case at least they were present the greater part of the time for ten days.

The P–R Interval before Digitalization. In nine cases digitalis was being used in some form; in one, strophanthin; and in one (Case 28), quinidine; the last has been described elsewhere and is only mentioned as evidence that quinidine can produce the same effect (Campbell, 1932). In seven of the remaining ten, the P–R interval without digitalis was known and the figures were 0·16, 0·20, 0·21, 0·21, 0·22, 0·24, and 0·25 sec. Thus it was prolonged in all except the first (Case 27) where an unreasonable amount of strophanthin had been given to a patient with pyrexia because of tachycardia after tonsillectomy. This bears out the experience of Mackenzie (1905, *b*) that it is the patient with latent heart block who is apt to develop dropped beats under digitalis treatment.

Apart from the presence of latent heart block there seemed no other ætiological factor common to all these cases. Rheumatic and syphilitic valvular

disease and myocardial disease, with and without high blood pressure, were all represented. Probably rheumatic disease formed a smaller proportion than in many conditions because of the tendency of rheumatic hearts to fail with auricular fibrillation, which would automatically exclude them from this study. The effect of digitalis on the P–R interval in these patients is shown in Table II.

TABLE II

THE PRODUCTION OF DROPPED BEATS FROM DIGITALIS THERAPY

Case No.	Sex and age	Diagnosis	P–R interval			Digitalis treatment	
			with digitalis		without digitalis		
			with dropped beats	without dropped beats		Daily amount	No. of days
2	m. 24	Mitral stenosis; C.F.*; active carditis.	0·24–0·42	—	0·24	30 minims of tincture	23
4	f. 68	High blood pressure; C.F.*; pyrexia.	0·23–0·31 0·21–0·41	—	0·21	45 minims of tincture	10
8	m. 44	High blood pressure; C.F.*; pyrexia.	0·25–0·29	0·25	—	3 grains of leaf and later 20 minims	18
9	f. 66	Left ventricular failure (died).	0·24–0·42	0·40	—	6 grains of leaf	5
11	f. 41	High blood pressure; C.F.*; (died).	0·18–0·26	0·26	0·20	45 minims of tincture	14
12	f. 72	Carcinoma; C.F.*	—	0·28	—	69 minims of tincture	9
18	f. 36	Mitral stenosis; acute rheumatism.	0·23–0·38	0·30	0·25	1/80 grain of Nat. dig., and quinidine	?6
19	f. 58	High blood pressure; C.F.*	0·19–0·38	—	0·21	60 minims of tincture	14
26	m. 41	Syphilitic A.I.; C.F.*; pyrexia.	—	0·29	0·22	60 minims of tincture	33
27	f. 31	Tonsillectomy; pyrexia	—	0·28	0·16	3/200 grain of strophanthin	7
28	m. 40	Thyroidectomy for hyperthyroidism	0·23–0·46	—	0·18	15 grains quinidine	—

* C.F.=congestive failure.

Infection or Pyrexia. Although latent heart block was already present in nearly all these cases, and in addition in most of them congestive failure, yet another conditional cause was generally present. Of the ten, two had active rheumatic carditis (one with failure) and four others (three with failure) had some degree of pyrexia, at the time, so that there was probably some infection making the heart more susceptible to digitalis.

In the first two with active rheumatic carditis (Cases 2 and 18) it is not surprising that dropped beats developed as they are liable to occur in this condition, even without digitalis. In a third (Case 27) there had been a fairly severe infection with pyrexia for some time. In her case, however, the amount of strophanthin given was excessive, and in Case 18 also the amount of digitalis was more than is usual and certainly excessive when quinidine was given at the same time.

Relatively slight infections seem to have had an important effect on the heart in the other three. In one (Case 26) there was "influenza" with a temperature for three days and probably it would hardly have been referred to in the notes if heart block had not developed. The sequence of events is illustrated in Fig. 2. Digitalis was stopped after he had taken 60 minims of the tincture daily for 33 days because the heart rate fell to an irregular 50 a minute (seventh day of fig. 2). For four days it varied between 50 and 80, and one day the P–R interval was 0·29 sec. though no dropped beats were recorded. The heart rate, then, remained about 80; and after seven days' break digitalis

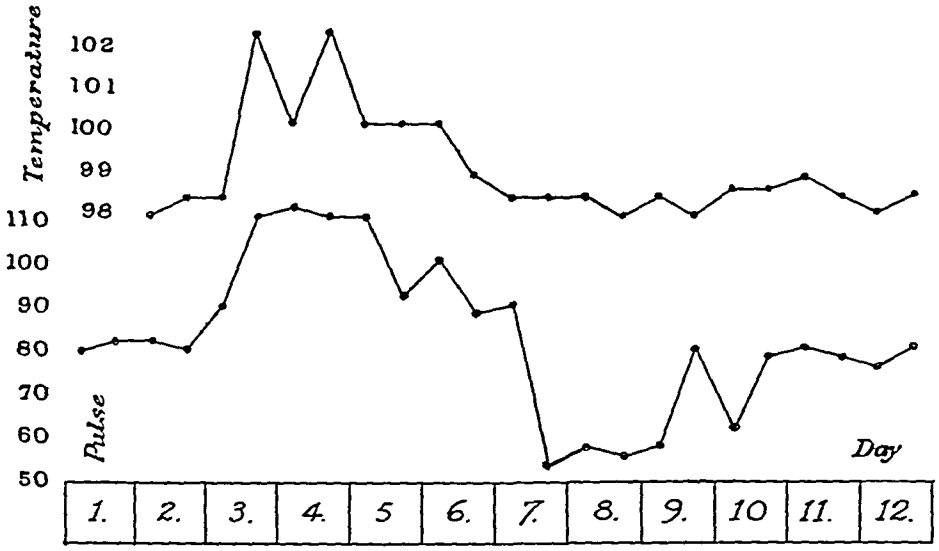

FIG. 2.—A slow pulse due to heart block after a transient infection. The upper line represents the temperature which returned to normal after four days (third to sixth days inclusive). The lower line represents the heart rate which rose with the onset of the temperature but fell sharply five days later (seventh day in fig.) when heart block developed. (Case 26)

was resumed, this time 45 minims daily, and continued until his discharge four weeks later, without any return of dropped beats. On admission with failure and without digitalis, the P–R interval had been 0·22; on discharge with digitalis (45 minims daily) but without failure, it was 0·23; and six months before without either, it had been 0·18 sec.

In the other two the pyrexia was even more trivial and no special cause for it was found. However, in one (Case 8) there was little doubt of the connection because the first time dropped beats were observed there had been a rise of temperature to 99·5° or 100° each evening for eight days; and the second time the dropped beats occurred when the rise was about its maximum, reaching 100° F. every evening; after this there was no more pyrexia, and for the remaining three weeks while he was in hospital he was able to continue with the same amount of digitalis without any recurrence of dropped beats. In the other (Case 4) the connection again seemed a close one, but not proved so clearly, as her treatment was resumed with a smaller dose of digitalis. Two days after her block was first observed her temperature rose to 100° F. for two days, and again

for three days at the time the second cardiogram showing block was taken, when she had already been without digitalis for ten days.

In none of the last three cases was there any reason to think that the slight pyrexia was a sign of recurrent, but undiagnosed, rheumatic carditis; one had syphilitic aortic incompetence with congestive failure, and the last two were elderly patients with congestive failure secondary to high blood pressure.

Cushny (1925, p. 90) states that as the temperature is raised experimentally the heart, whether isolated or in the intact animal, becomes more susceptible to digitalis; this being due to a direct action on the muscle as well as to the effect of the acceleration of the heart rate. It seems unlikely, however, that these small rises of temperature in transient infections would be enough to act in this way.

Thus six of the ten cases had some infection at the time of their dropped beats. Two others had hearts that were very gravely damaged as shown by the fact that one (Case 9) died suddenly the next day (see p. 140) and another (Case 11) died three weeks later in spite of all treatment. Cushny (1925, p. 225) says that when the heart is reduced to a state of malnutrition the block through direct muscular action is attained early and easily from digitalis, so that this may have been an additional cause in these two cases.

It seems, therefore, that the presence of infection or of a heart that is almost moribund makes a patient prone to develop partial heart block with dropped beats from an amount of digitalis that would not ordinarily produce this. Three cases supported this directly by being able to take the same amount of digitalis, when they had no pyrexia, without dropped beats developing (Cases 2, 8, and 26).

Accepting this, there were only two patients (Cases 12 and 19) who developed dropped beats under treatment without any additional cause: both had been given 60 minims of tincture of digitalis daily, one for 14 days and the other for 9 days. Perhaps 14 days may be rather longer than many patients can take this amount, but another (Case 26) had taken it for 33 days and even then the onset of an infection was certainly a partial cause of his dropped beats. The quantity of digitalis that was being taken by all these cases is discussed later (see p. 139).

The Effect of Digitalis on the P–R Interval. This is shown in Table II. The average P–R interval before digitalis therapy was 0·21 sec. In seven cases there was a record of the P–R interval about the time of the dropped beats, but at a moment when they were absent and there was latent heart block without dropped beats. The average figure was 0·29 sec.

Where there were dropped beats they generally occurred after two normal, if slow, responses, i.e. 3:2 heart block (and this was the only group where there were enough for statistical treatment). In three the P–R interval of the response before the dropped beat was moderately prolonged, the average figure being 0·22 sec., 0·29 sec., dropped beat. In the other six the P–R interval of the response before the dropped beat was much longer, and the average figures were 0·22 sec., 0·41 sec., dropped beat. It did not seem possible to find any reason for the difference between these two groups; in fact one patient (Case 4) after

an interval of five days varied just as much as these two very different sets of figures.

The P–R interval at a time when there were no dropped beats was on the average about half-way between the two P–R intervals that came before the dropped beat; but this was only an average of very divergent figures, and in individual cases it might be little longer than the first P–R interval or nearly as long as the second.

The first P–R interval after the dropped beat was on the average much the same as the P–R interval without any digitalis, and here there was much closer agreement in individual cases.

Latent Heart Block without Dropped Beats

In addition to the 11 cases with dropped beats, there were 15 others where digitalis treatment lengthened the conduction time, and another 6 (making 21 in all) where this was probable, but not quite certain, as there was no record of the usual P–R interval without digitalis. In 8 of these the 21, P–R interval was 0·26 sec. or more; some details of these cases are shown in Table III.

TABLE III

Prolongation of the P–R Interval to 0·26 sec. and above by Digitalis

Case No.	Sex and age	Diagnosis	P–R interval		Daily amount of digitalis
			with digitalis	without digitalis	
45	f. 15	Mitral stenosis	0·36 0·40	0·28* 0·28*	45 minims tincture 3 grains leaf
48	f. 18	Acute rheumatism; aortic incompetence.	0·31	0·20	5 gr. of leaf for several days
57	m. 54	Mitral stenosis; congestive failure.	0·34	0·26†	1/100 gr. Nat. dig. for several days
41	m. 68	High blood pressure; auricular flutter.	0·30	0·24	1/150 gr. Nat. dig. for 7 days (see text)
61	m. 51	Left ventricular failure ..	0·28	0·18	75 minims tincture for 21 days
38	m. 58	High blood pressure; congestive failure.	0·28	0·20	80 minims tincture for 28 days
53	f. 47	High blood pressure; congestive failure.	0·27	—	45 minims daily
46	m. 60	Heart failure; coronary thrombosis.	0·26	0·21	1/200 gr. Nat. dig. for 18 days

* Some years later it was 0·36 without digitalis. † Still on some digitalis.

The P–R Interval before Digitalization. Some degree of heart block before digitalis treatment seemed the most important factor in allowing digitalis to increase this significantly. Where the P–R interval was increased to 0·26 sec. or above by digitalis, only one of the seven where the P–R interval was known had one of less than 0·20 sec. without digitalis; his was 0·18 sec. and he was given 75 minims of the tincture daily for 21 days (Case 61). In the eighth the P–R

interval without digitalis was not known. The average figures for the P–R intervals before and after digitalis were 0·22 and 0·30 sec. respectively.

Where the P–R interval was increased to something less than 0·26 sec. by digitalis, it was above 0·18 sec. without digitalis in all of the eight, except in one with acute infection and severe congestive failure and in one during pregnancy; in both these it was only 0·16 sec. There were five others in this group where the P–R interval without digitalis was not known. The average figures before and after digitalis were 0·19 and 0·22 sec. respectively.

Other Aetiological Factors. The presence of latent heart block before digitalization was the main factor that was common to nearly all of the cases. The type of heart disease seemed of no significance and all varieties were present in different patients; nine of the twenty-one had valvular disease, nearly always rheumatic, and the other twelve had primary myocardial disease, six of these with high blood pressure and three at least with disease of the coronary arteries.

Heart failure was naturally present in the great majority as it is the main indication for digitalis. The reasons for its administration in four of the other six without failure was tachycardia and cyanosis (Case 45), some undue dyspnœa during pregnancy, auricular flutter (Case 41), and frequent extrasystoles; in the other two there seemed to have been no adequate reason for the prescription of digitalis.

The other factor that seemed common to these cases—at any rate to those where the P–R interval was most increased—was a rather bad prognosis. There were eight in whom it was lengthened to 0·26 sec. or more, and two of these were not followed for long enough to know the outlook. Of the other six, one did well, one had acute pulmonary œdema in the fifth year, and four died after 1, 1, 4, and 8 years respectively. As digitalis was generally used for a failing heart, and heart failure with normal rhythm has a worse prognosis than failure with auricular fibrillation, one could not expect the patients to live for very long, but these figures are worse than might be expected.

Infection or Pyrexia. Active infection was much less in evidence as a cause than in the cases with dropped beats, but was present in three. One had infective endocarditis and congestive failure. A second, a girl of 18, to whom 5 grains of digitalis leaf has been given daily for several days without any adequate reason had a recurrence of acute rheumatism at the time (Case 48; P–R from 0·20 to 0·31 sec.). A third, a boy of 7, was critically ill with congestive failure due to acute myocarditis and acute nephritis following tonsillitis: probably, he owed his life to digitalis treatment, though the P–R interval lengthened from 0·16 to 0·21 sec.; this last may partly have been due to his myocarditis, as some of the inversion of the T waves certainly was, but seemed more closely related to the time of his treatment with digitalis than of his active infection. A fourth was recovering from recent broncho-pneumonia, but this seemed rather the exciting cause of his congestive failure than of his partial heart block (Case 57).

One case where the P–R interval was not lengthened by digitalis was striking in this connection. A woman, aged 56, suffering from the after effects of tonsillitis and broncho-pneumonia some months before and from auricular

fibrillation that was probably due to old hyperthyroidism, had a P–R interval of 0·13 sec. after treatment with 45 minims of tincture of digitalis daily for five weeks; fibrillation had stopped after a few days treatment with digitalis and may possibly have been paroxysmal. Four months later she was again admitted with an acute rheumatic infection, most unlike rheumatic fever and with no other signs of cardiac involvement, and while she was being treated with sodium salicylate only, her P–R interval was 0·22 sec.; presumably this was due to the infection, and it had been only 0·13 sec. when she was treated with digitalis.

Digitalis

The Amount of Digitalis. In few of these patients could the increase in the heart block be attributed to an amount of digitalis that was obviously excessive, and curiously enough the largest amounts had sometimes been given where there seemed no indication for digitalis therapy (Cases 18, 27, and 48).

In the ten where dropped beats developed, three had large doses of digitalis—1/240 grain of Nativelle's digitaline, t.i.d., and some quinidine, probably for 6 days (Case 18, with acute rheumatism); 1/200 grain of strophanthin, t.i.d., for 7 days (Case 27, with tachycardia and pyrexia after tonsillectomy); and 6 grains of the leaf daily for 5 days (Case 9, with left ventricular failure). Certainly in the first two there seemed no reason why digitalis should have been given. Three others had 60 minims of tincture daily for 9, 14, and 33 days, and even then the last only developed dropped beats with an intercurrent infection (Case 26). Of the remaining four, two had the standard dose of 45 minims daily and two had only 30 and 20 minims daily. In the last two these amounts had been taken for 23 and 18 days respectively; and recurrent infection (once rheumatic and once of unknown origin) was almost certainly the precipitating cause, as later when they had no pyrexia they were able to take the same amount without the production of dropped beats.

In the group of eight, with the greater increase of conduction time but no dropped beats, four had amounts that were large—5 grains of the leaf daily for no apparent reason (Case 48, with recurrent rheumatism); 1/100 grain of Nativelle's digitaline daily for several days (Case 57); 75 minims of the tincture daily for 21 days (Case 61); and 80 minims of the tincture daily for 28 days (Case 38); these two last, however, were both large heavy men.

In the other four of these eight, and in the thirteen with the lesser increase in the conduction time, the amount of digitalis was certainly not unusually large. In two only, who had about 60 minims daily, was it above 45 minims of the tincture daily (or its equivalent), and in five it was less than this.

The cause, therefore, rarely lay in excessive amounts of digitalis, and this might be expected where most cases were being treated at hospital, though it is only fair to add that during the years in question massive digitalization has not been a popular method of treatment at Guy's Hospital—and, in my opinion, rightly so. In general, during continued treatment, failing to give an adequate amount of digitalis is much more common than giving too much.

Other Symptoms. Little has been said about other symptoms produced by

the overdose with digitalis. Price (1941) states that they are anorexia, nausea, vomiting, and diarrhœa, in addition the very varied effects on the rhythm. Unfortunately in this series of cases special notes were not taken about the general condition of the patient, and no useful conclusions can be drawn about the relative stages at which the general symptoms and the slower pulse occurred. Nausea and vomiting were noted most, but it is surprising how often there was no note of other symptoms, and how the house officer in charge did not stop the exhibition of digitalis until partial heart block with dropped beats was observed. It is also surprising that extrasystoles were not noted; no single case was observed where they were seen in the cardiographic record at the time of full digitalization, though of course they would have been difficult, if not impossible, to recognize clinically when there were dropped beats.

Indications for Digitalis in Heart Block. The old contraindications to digitalis therapy have gradually been swept away, and Cushny (1925, p. 233) in lending his authority to this view agrees that digitalis may be useful even when there is complete heart block, but still looks with doubt at its use when there is partial block. Obviously the risk of increasing this must be taken into account; but when failure is present, digitalis should always be used in adequate amounts until experience shows that the drawbacks, if any, outweigh the advantages.

These results have made it clear that when there is congestive failure with latent heart block, an increase in this, even with dropped beats, is liable to occur after reasonable amounts of digitalis. There seemed, however, no great drawback even in cases where dropped beats were produced, and in general the block passed off quickly within two to four days of the digitalis being stopped, though once it persisted for ten days. As might be expected from its slow absorption and slow effect, there was sometimes a higher degree of block the day after digitalis had been stopped, and this would be a danger if the condition was not recognized. Freedom from ill-effects is dependent, therefore, on the heart block being recognized with reasonable speed, but care and knowledge are always needed to make the most effective use of digitalis.

One of these patients died suddenly, soon after block had been observed and digitalis stopped; but she was extremely ill before and had, post-mortem, advanced disease of the coronary arteries with a badly scarred ventricle, so that sudden death was an ever-present risk; it is possible but far from certain that digitalis may have caused her death by producing ventricular fibrillation; it is probable that it had already prolonged her life in previous attacks.

When failure is not present, there are fewer indications for digitalis and the recognition of partial heart block may decide against it. This, however, must not be made a general rule, and one case is of special interest because the high degree of block might have prevented treatment with digitalis in a girl who was greatly benefited and continued taking it most of the time for several years. She had high grade mitral stenosis with much cyanosis and dyspnœa. Dozens of electrocardiograms between 1931 and 1938 never showed a shorter P–R interval than 0·26 sec.; in 1932, 45 minims of the tincture daily increased it from 0·28 to 0·36 sec., and in 1933 a period of treatment with 3 grains of the leaf daily increased it to 0·40 sec. (see Fig. 3). Gradually, during the course

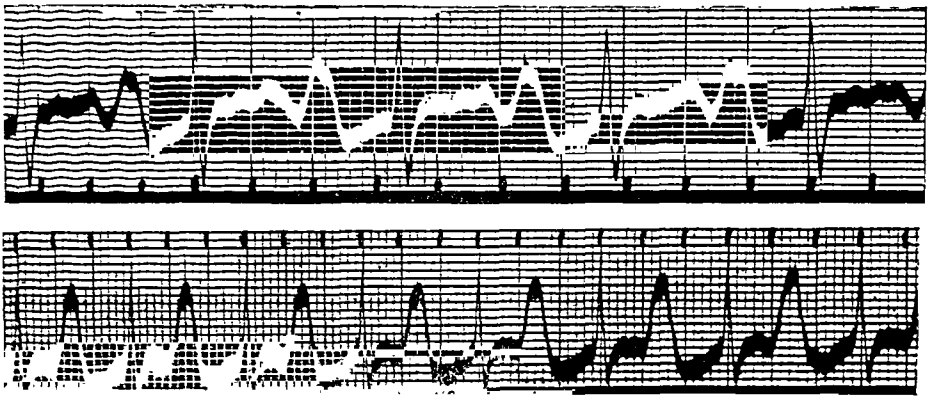

FIG. 3.—Latent heart block, present for eight years without a dropped beat being noted.
(A) Above. 13/5/31. The shortest P–R interval of 0·28 sec.
(B) Below. 24/11/33. The P–R interval had been increased from 0·28 to 0·40 sec. by digitalis, but later it increased to 0·36 sec. without digitalis.
The P wave was always large, but in (B) it is exaggerated as the tachycardia and the still longer P–R interval have superimposed it on the T wave. (Case 45)

of these seven years, the P–R interval rose from 0·26 to 0·36 sec., even when she was not taking digitalis. It is surprising that at no time (and she attended hospital regularly for years) was a dropped beat observed (Case 45).

Mackenzie (1905, *a*) described a somewhat similar case where the a–c interval was two-fifths of a second and remained so for twelve years; no dropped beats were observed except for one short period about the middle of the time. He emphasized that digitalis must be used whenever indicated, even in partial heart block, and that sometimes when there was effective slowing the conductivity might even be improved. Cohn and Fraser (1913) have suggested, as an explanation of how digitalis may help in some cases of mitral disease, that it may act by lengthening the A-V interval and thus facilitating the passage of blood from auricle to ventricle.

SUMMARY AND CONCLUSIONS

Digitalis therapy is one of the commonest causes of partial heart block with dropped beats, and a common cause of a P–R interval that is much prolonged without dropped beats. Other factors, however, are generally present, and the most important of these seems to be some lengthening of the P–R interval before digitalis therapy; even then, a concurrent infection is often the immediate cause of the dropped beats. In a series of cases of partial heart block nearly 40 per cent of those with dropped beats were being given digitalis, and 15 per cent of those with latent heart block.

The most essential prerequisite was some prolongation of the P–R interval before treatment. In those with partial heart block and dropped beats, and in those with latent heart block it averaged 0·21 sec. Only in three of twenty-three was the P–R interval below 0·18 sec.; in these three it was 0·16 sec., and in two of them there was acute infection also. When there were no dropped beats,

the P R interval was on the average increased to 0·26 sec. When there were dropped beats, there were most often two responses before the dropped beat, and the lengthening P–R intervals averaged 0·22 sec., 0·37 sec., dropped beat, etc. This, however, was the average of very varied figures, which averaged 0·22, 0·29, dropped beat, etc., in three, and 0·22, 0·41, dropped beat, etc., in six patients. No special difference could be found between the groups with these different responses. Apart from the presence of latent heart block the ætiology of the underlying heart disease did not seem of importance, though naturally congestive failure was present in the majority, as this was usually the indication for digitalis.

The presence of a concurrent infection seemed the next most important factor. When there were dropped beats, more than half had some active infection at the time. Sometimes this was a severe infection such as active rheumatic carditis, but often it seemed of a trivial nature, and it was only because digitalis could be taken at other times without producing dropped beats or because the rise of temperature ran so closely parallel to their onset that one could be sure of the connection. When there was latent heart block, an active infection was less often present, but was noted as the cause in a few cases. In others where there was no infection but a heart that was very seriously damaged (as shown by the patient's death within a relatively short time) this seemed an additional factor making the conduction time more sensitive to digitalis than usually.

Large amounts of digitalis were rarely the cause. Three of these cases were taking amounts that would generally be thought excessive (and curiously enough two of these had acute infections at the time and there seemed no reason why any digitalis should have been given); seven had amounts that were large, but quite reasonable; and twenty-two were taking amounts that were average or sometimes even small.

In general, there seemed to be no severe ill-effects, even when there were dropped beats: and the block passed off quickly (within two or three days), but, of course, this immunity is dependent on the heart block being recognized quickly.

There seems no reason why the chance finding of latent heart block should prevent adequate treatment with digitalis where this is indicated, though naturally the case should be watched even more carefully than usual.

References

Campbell, M. (1932). *Lancet*, **2**, 1157.
Cohn, A. E., and Fraser, F. R. (1913). *J. Pharm. exper. Ther.*, **5**, 512.
Cushny, A. R. (1925). *The Action and Uses in Medicine of Digitalis and its Allies*, London, 1st edit.
Mackenzie, J. (1905, *a*). *Brit. Med. J.*, **1**, 520.
—— (1905, *b*). *Ibid.*, **1**, 587.
Price, F. W. (1941). *A Textbook of the Practice of Medicine*, Oxford University Press, 6th edit., p. 868.
Withering, W. (1875). *An Account of the Foxglove and some of its Medical Uses*, Birmingham and London.

BLOOD PRESSURE AND OLD AGE

BY

TREVOR H. HOWELL

From the Royal Hospital, Chelsea

Received June 20, 1942

Twenty years ago, Thompson and Todd (1922) published an article entitled " Old age and blood pressure problems." They recorded the blood pressure in a hundred and two Chelsea pensioners over the age of seventy-five, noting that forty-six of them had systolic figures over 150 mm. and twenty-three over 170 mm. They also found that apparently similar men in normal health showed great differences in blood pressure without obvious cause.

Several other writers have published figures of blood pressure readings in old age and these show considerable variation in their estimate of the normal. For example, Thewlis (1941) quotes Saller as stating that the average figures for men and women between the ages of sixty and sixty-seven are 173/93 and 216/102 respectively, and between sixty-seven and eighty-nine 186/80 and 222/112 respectively. Willius (1931), on the other hand, taking seven hundred cases over the age of seventy-five, attending the Mayo clinic, has figures varying from 109/75 to 127/74 mm. as the averages of his (two-year) groups. Even so, 74 per cent of his patients had systolic figures over 140 mm. and 40 per cent diastolic figures over 90 mm. Robinson and Brucer (1939), who took normal cases for insurance purposes, Bowes (1917), Richter (1925), and Wildt (1912) all published figures for five-year age groups. These are shown in Table I below, together with those of the present series.

TABLE I

AGE AND MEAN BLOOD PRESSURE

Age Groups	Robinson & Brucer	Richter	Wildt	Bowes	Howell
60–64	—	138/74	137/76	—	—
65–69	139/75	150/71	143/78	151/82	149/80
70–74	137/77	150/73	148/80	160/86	157/83
75–79	154/80	155/68	153/82	166/86	166/87
80–84	147/87	157/69	148/78	175/84	158/84
85–89		161/67	162/85	170/90	147/79
over 90	—	—	129/59	142/81	
Number of cases	189	165	?	150	120

All the above figures are lower than those of Saller but higher than those of Willius. They agree that a rise of pressure is customary after the age of sixty, reaching a peak somewhere between seventy-five and eighty-nine but falling

thereafter. More than this cannot be deduced without a careful analysis of the clinical material from which the figures were taken. The present study was an attempt to carry the work of Thompson and Todd a stage further by classifying the cases observed and trying to find some relationship between blood pressure, arteriosclerosis, mental state, and physical condition.

Conditions and Standards

The investigations were carried out on Chelsea pensioners, all tough veterans of the old professional British army. Their ages ranged from 65 to 92 and they comprised all men admitted to the Infirmary of the Royal Hospital, Chelsea, during a period of six months. Each patient was classified by blood pressure figures, the state of the arteries, renal concentration power, mental state, and physical condition. The blood pressure was taken usually once a week, but more often if the condition of a patient was changing rapidly. The method used was that recommended by the American Heart Association and the Cardiac Society of Great Britain and Ireland.

Owing to the evacuation of the Infirmary into temporary quarters, due to enemy action, the normal sources of X-ray and pathological investigations were not available, so that clinical methods only were used.

Variations in blood pressure.—Weekly variations of pressure were frequent within narrow limits. For instance, one patient kept between 190/90 and 210/110 throughout the whole period under review. Another stayed between 120/70 and 140/80, and a third between 140/80 and 160/90. Systolic figures appeared to vary about 20–25 mm. and diastolic figures 10–20 mm., but while the patient remained in his usual state, they rarely changed more than this. No significant pressure difference was found between the right and left arm of any patient, including those who were hemiplegic.

Infections, especially those with diarrhœa or prolonged pyrexia, almost always caused a fall in blood pressure. This might be as much as 50 mm. (systolic) with pneumonia, 25 mm. with enteritis, and 20 mm. with bronchitis. Any form of cardiac failure also lowered the blood pressure, which might fall from 180/90 to 90/60 in a week. The later stages of cancer were also associated with a drop in pressure. One patient, observed over two and a half years, went from 200/90 to 115/65 before death, while another fell from 190/90 to 110/60 in a few weeks. This was observed in seven cases.

The Blood Pressure

Three main groups were noted. The first was composed of those who remained above 160 mm. systolic throughout the period of observation. This was classed as raised blood pressure, and included 42 per cent of the total. The second consisted of those with systolic figures below 160 mm. but above 115 mm. The third was made up of those with systolic pressures under 115 mm. and included 5 per cent of the total. While these groups were arbitrary ones, nevertheless they corresponded with certain clinical classes.

High blood pressure.—Fifty of the patients had mean systolic pressures over 160 mm. during the period of investigation. Ten more, originally in this group,

dropped to lower levels with cancer, infections, or heart failure. (These cases either died or became invalids, instead of living a fairly normal life as they had done before.) Both ninety-two year olds were in this class.

TABLE III

AGE AND BLOOD PRESSURE

Age	Total number	Systolic over 160 mm.	Diastolic over 100 mm.
Under 70	26	40%	8%
70–74	33	36%	12%
75–79	34	51%	18%
Over 80	27	42%	4%

Thirty-three of the men were physically active and twelve more only slightly incapacitated. Mentally, eleven were of normal adult intelligence, twenty-five were of normal senile intellect, and fourteen had some mental impairment. Eighteen had very thickened palpable arteries, while only two had arteries that were relatively soft. Nineteen had a specific gravity of urine below 1015, but only two had albuminuria.

This group with raised blood pressure included many of the fittest men in the Infirmary. Eighteen of them had local disabilities, such as old injuries or impaired vision, which made them unsuitable for Chelsea with the possibility of air raids. The rest were suffering from such conditions as bronchitis, enlarged prostate, or mild senile dementia, while four were hemiplegic. The higher ranges of blood pressure were unusual, only eight patients having systolic figures over 200 mm. and only thirteen having diastolic pressures regularly over 100 mm.

Low blood pressure.—Six patients had systolic figures regularly below 115 mm. and five more had similar pressures for long periods. The only survivor of the first class was a case of colitis, the others all dying of cancer or cardiac failure. The temporary members of the group suffered from chronic bronchitis (2), pneumonia, septicæmia, or sciatica. In each case the systolic pressure rose to a level of 130–140 mm. on recovery.

ARTERIOSCLEROSIS AND MENTAL CONDITION

Arteriosclerosis.—Each patient was classified according to the state of his arteries as slightly thickened (+), moderately thickened (++), or considerably thickened (+++). No case had soft vessels. Both radial, brachial, and temporal arteries were taken into consideration before grading. In fifty patients, the findings were compared with the state of the retinal arteries. Some local variations were often found, as in the case of a man of 84 whose right radial was considerably thickened, but whose other accessible arteries were just palpable, and the retinal vessels little thickened. Another, suffering from senile diabetes, had slightly thickened palpable arteries with a markedly arteriosclerotic fundus.

The oldest man with only slight thickening of the arteries was 84. Five of the group had normal adult intelligence, while seven had ordinary senile mentality.

Only one showed mental impairment—the diabetic referred to above. Eleven were active enough to walk in the grounds of the Infirmary and to go up and down stairs without difficulty. Only two had hypertension, while three sometimes had pressures below 115 mm. systolic. This seemed to suggest a connexion between soft arteries and good physical and mental condition.

TABLE III

ARTERIOSCLEROSIS AND BLOOD PRESSURE

Arterial thickening	Toal number	Raised blood pressure	Lowered blood pressure	Mentally impaired
Slight	13	16%	24%	8%
Moderate	80	38%	4%	22%
Marked	27	66%	20%	32%

Twenty-seven had extremely thickened arteries. Each member of the group where the pressure was not raised was in a feeble physical condition, unfit for much exertion. Five were also mentally impaired. Eighteen normally had a raised pressure, six of them being over 80. Eight of them had intelligence below normal senile standards: none were above it.

Out of fifty cases whose ocular fundi were examined, some thirty showed arteries thickened and tortuous in the centre of the disc, narrowing peripherally. Many of these had some irregularity in the lumen of the vessels. Sixteen had arteries that were narrowed, but more or less straight, throughout their course, not showing any irregularities. Two seemed to be normal and two had vessels that were difficult to see clearly. The state of the vessels appeared to have no relation to the level of blood pressure or the general state of the arterial tree, thirteen of the first class and eleven of the second having a raised pressure.

Of those with marked arteriosclerosis, the patients with raised blood pressure were, on the whole, more active and alert than the rest. It seemed that, over the age of seventy-five, marked thickening of the arteries was not important prognostically, especially when the blood pressure was raised. Below seventy and with relatively low blood pressure, some mental and physical impairment was usual. The power of recovery from injuries and infections was certainly poorer than in those with raised blood pressure who were a few years older.

Mental condition.—The mental state of patients was assessed as normal adult, normal senile, or impaired. The first class is self-explanatory. The second included those who could behave rationally and carry on a sensible conversation, but whose perceptions were somewhat dull and whose mental processes were slower than those of younger persons. The third class was composed of those who were clearly abnormal or subnormal.

Fifteen patients had normal adult intelligence. All were physically active and three actually employed on light duties in the infirmary. The oldest member of this group was 75 years of age. Eleven had a raised blood pressure and ten showed moderate thickening of the arteries, while none had extreme thickening. None of these cases had urine with specific gravity below 1015.

TABLE IV

MENTAL CONDITION AND CIRCULATION

Mental standard	Total number	With raised blood pressure	Arterial thickening +	++	+++
Adult	15	73%	33%	67%	—
Senile	78	33%	10%	66%	24%
Impaired	27	50%	4%	66%	30%

The normal senile group included seventy-eight patients, of whom twenty-five had raised blood pressure. Nineteen had marked arteriosclerosis, but in seven the thickening was only slight. Sometimes a man in this class would go downhill and become mentally impaired, and this was usually associated with some intercurrent disease or change in blood pressure. For example, a patient whose general levels were between 120 and 150 mm. systolic became mentally worse on falling to 110 mm.; this was a mild case of the syndrome of progressive cerebral ischæmia (Howell, 1941).

Twenty-seven cases were mentally impaired. Fourteen of these had a raised blood pressure and two had pressures below 115 mm. systolic. Only one had slight thickening of his arteries and he had also an arteriosclerotic fundus oculi. Eighteen had moderate, and eight marked thickening of the arteries. Ten of the cases had a low specific gravity of urine, while only one had a figure above 1025. Six of these mentally impaired patients were hemiplegic. Thirteen were among the group whose fundus oculi was examined; nine had arteries thickened in the centre of the disc but narrowing peripherally, and the rest had vessels that were straight and narrow throughout their course.

DISCUSSION

As we have seen above, a systolic pressure above 160 mm. is common in old age. In the five-year age groups examined, the proportion varied from a third to a half of all cases. Among the oldest patients, the fittest were those with a high pressure; and a figure below 125 mm. was only seen in three men over 80, two of whom were dying and the third of whom had exceptionally soft arteries for his age. The findings suggest that increased pressure is needed to offset the arteriosclerosis that becomes more pronounced with age (see Table V). Marked thickening of arteries with a relatively low blood pressure is associated with poor physical condition, while raised blood pressure and very thick arteries are compatible with relative fitness and activity. The connexion is not so clear in the case of mental impairment, but we can say that no man with very thickened arteries had adult intelligence and that no patient with impaired intellect had less than moderate arteriosclerosis.

Measurement of the specific gravity did not give much help in the assessment of a patient's condition, only 10 per cent of cases having a figure above 1025 for early morning urine. Robinson and Brucer (1939) suggest that old age depends on low weight, low blood pressure, and a slow pulse. Experience at the Royal Hospital, Chelsea, does not accord with this, however. Seven out of

TABLE V

AGE, ARTERIOSCLEROSIS, AND RAISED BLOOD PRESSURE

Age	Total number	Arteries +	Arteries ++	Arteries +++	Patients with high blood pressure
Below 70	26	20%	65%	15%	40%
70–74	33	15%	70%	15%	37%
75–79	34	6%	76%	18%	50%
Over 80	27	4%	52%	44%	33%

ten pensioners over ninety in recent years have been stout rather than thin: both ninety-two year olds in the present series had a systolic pressure habitually over 160 mm., while a pensioner, killed by enemy action at the age of a hundred, had a pressure of 150/80 during the last two years of his life. This man was also far from thin.

It seems that the raised blood pressure arising in old age is beneficent compared with that of younger persons. In the present series of cases, many of the younger men who had been admitted to the Royal Hospital as In-pensioners with high blood pressure, were in poor condition compared with their elders. As arteriosclerosis increases, a greater head of pressure is necessary to prevent ischæmia of vital organs or tissues, so that senile hypertension may well be compensatory in character. In the absence of raised pressure, vital ischæmia takes place, resulting in impaired function, either mental or physical. With the old man with raised blood pressure, cardiac defeat or a vascular accident eventually terminates life, but he is often spared the lingering existence, dependent on others for everything, that falls to the lot of some aged folk.

SUMMARY

A rise of systolic blood pressure is common after the age of sixty.

In the present series of 120 Chelsea pensioners, 42 per cent had systolic figures regularly over 160 mm.

Cancer, cardiac failure, and infections often cause a fall in blood pressure.

Marked arteriosclerosis, in the absence of raised blood pressure, is usually associated with poor physical condition.

It is suggested that the raised blood pressure of old age is a form of compensation tending to prevent ischæmia of vital structures.

I should like to express my thanks to the nursing staff of the Royal Hospital, Chelsea, for their assistance in my investigations.

REFERENCES

Bowes, L. M. (1917). *J. Lab. clin. Med.*, **2**, 256.
Howell, T. H. (1941). *Postgrad. med. J.*, **17**, 195.
Richter, A. (1925). *Deutsch. Arch. klin. Med.*, **148**, 111.
Robinson, S. C., and Brucer, M. (1939). *Arch. intern. Med.*, **64**, 409.
Thewlis, M. W. (1941). *The Care of the Aged* (Kimpton).
Thompson, R. J. C., and Todd, R. (1922). *Lancet*, **2**, 503.
Willius, F. A. (1931). *Amer. J. med. Sci.*, **182**, 1.

TRANSIENT INVERTED T WAVES AFTER PAROXYSMAL TACHYCARDIA

BY

GEORGE M. CURRIE

From the Kilmarnock Infirmary

Received July 21, 1942

Graybiel and White (1934) have stressed that care must be taken in the diagnosis of serious heart disease when inverted T_1 or T_2 waves are the only abnormal finding, and that this inversion is not invariably associated with organic disease. They cited two cases of paroxysmal tachycardia in young robust adults, one followed by inverted T_1 and the other by inverted T_2 and T_3 waves; there was no sign of organic disease and there was a gradual return to a normal cardiogram. Campbell and Elliot (1939) record two cases of ventricular tachycardia that gave transient changes simulating coronary thrombosis; one of these gave a history of diphtheria and the other was of long standing and had been suffering from increasing dyspnœa during the intervals between attacks; both died suddenly at a later date. These cases show that the general condition must be given prime consideration in forming a prognosis.

It is generally recognized that the commonest causes of inversion of T waves are coronary thrombosis, myocardial disease due to toxæmia or hypertension, large doses of digitalis, the physiological effect of taking cold drinks, and the position of the heart. White (1941) has recently shown that change of posture may bring about an inversion of T waves especially in persons of the neuro-circulatory asthenic type.

Present Case

A girl, aged 13 years, was admitted to Kilmarnock Infirmary with paroxysmal tachycardia that had already lasted 24 hours. The attack stopped spontaneously after a total duration of 36 hours; it was unaffected by any of the usual procedures to terminate it.

Previous History. An only child, nervous and of nervous parentage; whooping cough at 2 years but no sequelæ; no other ailments except chicken-pox, until her first attack of tachycardia three years previous to the present one, when she got a fright while on a swing; six attacks since then; her mother stated that these seemed to come on after an attack of flatulent indigestion but with no actual warning, the first thing the child felt being a " thumping " in her chest; the duration varied from 2 to 24 hours and each attack stopped suddenly, leaving the patient well but weak for some days.

Examination. On admission, pulse rate 214, respirations 26, and temperature normal. During the paroxysm there was an obvious impulse over the cardiac area; there was no enlargement of the heart; a systolic murmur most marked just to the left of the sternum; no signs of pulmonary congestion or of enlargement of the liver or spleen; but some flatulent gastric distention: a cardiogram confirmed the diagnosis of paroxysmal tachycardia, most likely of ventricular origin: radiological report, no abnormality either of heart or lungs. The next morning her pulse rate was 96 and the blood pressure was 112/82; she was comfortable but apprehensive; the cardiogram showed lowered S–T and inverted T_2 and T_3; on the next day it was the same; four days after the attack there was also some slight inversion of T_1; thereafter there was steady improve-



FIG. 1.—Attack on 31/10/39.

(A) During attack. (B) Following day. (C) 2 days after. (D) 4 days after. (E) 13 days after. (F) 30 days after.

ment till on 30/11/39 it was normal (Fig. 1). The patient was kept resting in bed for eight days and was dismissed at the end of two weeks.

On 4/6/40 re-examination showed a similar normal cardiogram; she had kept fairly well except for a morbidly introspective mentality for a girl of her years; she had been kept on a simple carminative mixture and small doses of phenobarbital.

On 28/8/40 she was seen at the start of another attack and a cardiogram taken within an hour was similar in form to the first but the T waves were higher; it should be remembered that the former had been taken 24 hours after the onset. This attack lasted three hours. The records in this case (Fig. 2) show that on 1/9/40 T_2 and T_3 were inverted but the S–T interval was unaffected; on 11/9/40 T_2 was isoelectric and T_3 only slightly inverted; on 25/9/40 there was a return to normal.

On 20/6/41 the cardiogram was normal; in the interval there had been no further attacks and the patient had much improved generally; she had been encouraged to lead a normal life; she mixed with other girls, and at the same

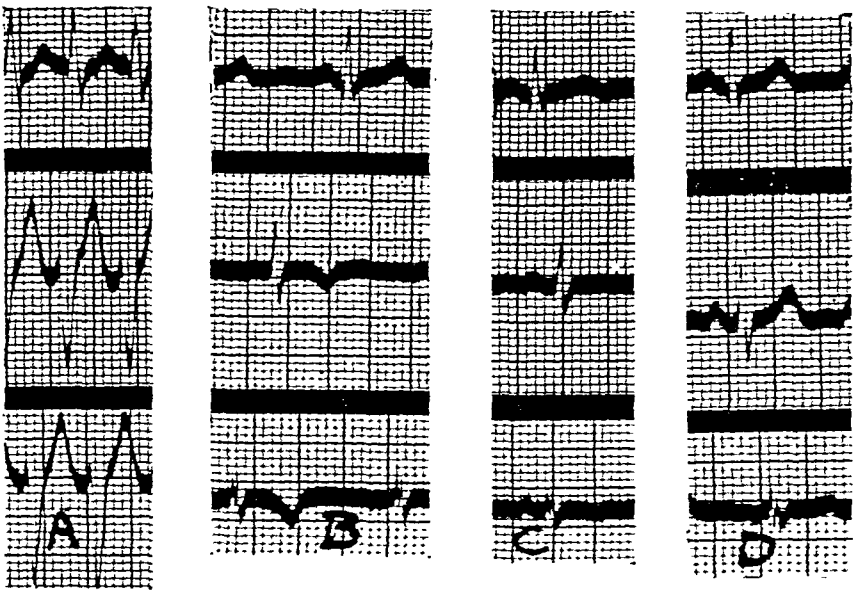

FIG. 2.—Attack on 28/8/40.
(A) During attack. (B) 4 days later. (C) 14 days later. (D) 28 days later.

time her mother had been prevailed upon not to shelter her only child so much; she was now working in an office.

At the present time (April, 1942) she is well and has had no return of the tachycardia since August, 1940; her pulse rate and blood pressure are normal, as is also the cardiac condition; her nervousness is decidedly less.

DISCUSSION

When this patient first came under observation she was classed as neuro-circulatory asthenia on account of her general state and the absence of organic disease and of any history of disease leading to cardiac complications; she was easily tired and excited, and had palpitation and dyspnœa with slight exertion and excitement, and slight tachycardia even when resting.

The degree of inversion of the T waves and the disturbance of the S–T interval appeared less after the second attack which was only 3 hours duration as against 36 hours in the first; this would seem to indicate that the duration and hence the degree of strain on the myocardium affect the amount of temporary change in the cardiogram; this is important when one comes to consider the cause of the inversion, and lends weight to the theory that it is due to overstrain of the myocardium.

The primary fact that emerges is that abnormalities simulating coronary thrombosis have arisen apart from detectable organic disease; if the paroxysmal condition had not been confirmed at the time of the attack, the subsequent records might have raised suspicion of serious heart disease. The second series confirmed the transient nature of the cardiographic abnormality. The case

has not been reported earlier in order that a sufficient time should elapse to rule out the development of cardiac complications. In view of the different endings in the cases quoted and the present one—fatal in those of Campbell and Elliot, apparent recovery in those of Graybiel and White and the present case—the clinical findings should be taken into consideration, when it is seen that a bad prognosis was probable in the fatal cases in view of the presence of organic lesion or toxic history, while in the other three cases there was no discoverable organic lesion. This is obviously another instance of a condition where negative T waves may not have the serious prognostic import usually attributed to them.

Summary

A case of recurrent paroxysmal tachycardia in a girl with neuro-circulatory asthenia is described; at the time of first observation she was 13 years of age and is now 16; serial cardiograms during and after each attack showed transient inversion of the T waves and a lowering of the S–T interval in one series; there was a return to normal in each case in a month; the degree of the inversion is probably affected by the duration of the attack. The relative importance of the clinical over the cardiographic findings in giving a prognosis in such cases is stressed, and a possible cause of the inversion is put forward.

Addendum. Since this article was written Campbell (1942) has reported three cases in addition to those already referred to (Campbell and Elliot, 1939); these additional cases were of the clinically " benign " type, and the transient alteration in the T waves was considered not to " indicate any organic disease but to be a completely reversible process indicating some degree of exhaustion or strain of the heart muscle," a conclusion agreeing with that already formed regarding the present case.

References

Campbell, M., and Elliot, G. A. (1939). *Brit. Heart J.*, **1**, 123.
—— (1942). *Ibid.*, 4, 49.
Graybiel, A., and White, P. D. (1934). *Amer. Heart J.*, **10**, 345.
White, P. D., Chamberlain, F. L., and Graybiel, A. (1941). *Brit. Heart J.*, **3**, 233.

PROGNOSIS IN PAROXYSMAL TACHYCARDIA AND PAROXYSMAL AURICULAR FIBRILLATION

BY

W. TREVOR COOKE AND PAUL D. WHITE

From the Cardiac Laboratory, Massachusetts General Hospital, Boston, Mass., U.S.A.

Received September 12, 1942

In 1888, Bristowe wrote of " Recurrent palpitations of extreme rapidity in persons otherwise healthy "; he was, however, extremely guarded as to the correct prognosis in this condition, seeing that six out of nine of the cases he described died before their time. Similarly, two of the three cases recorded by Bouveret (1889) died of congestive failure during an actual paroxysm. Indeed the early reports are characterized by the number of fatal cases, so that it is not surprising to find Herringham (1897) writing " when one sees a robust and healthy person subject to these attacks, it is tempting to make light of them, but this ought never to be done. The condition seems always to tend to get worse and, in the end, to kill."

We do not in our generation take such a gloomy view of the attacks, but even now it is not uncommon to find patients, who are otherwise organically sound, living a life of a cardiac cripple following the pronouncement of a poor prognosis. We are, therefore, submitting our observations on a large number of patients with paroxysmal auricular tachycardia, especially on those who are otherwise perfectly healthy, in order that a more optimistic outlook shall be the rule to counteract the somewhat pessimistic attitude of earlier writers.

The basis of this paper has been chiefly the private case records of one of us (P.D.W.), these consisting of more than 600 cases of paroxysmal tachycardia. In addition, all those in the index files of the Massachusetts General Hospital between the years 1928–38 were reviewed. Numerous others from the cardiographic laboratory were also collected so that the total number of cases considered was more than 750. A separate paper has been submitted dealing with paroxysmal ventricular tachycardia.

Immediate Prognosis of Paroxysmal Auricular Tachycardia

The likelihood of any particular attack ceasing, in spite of the most alarming symptoms, is practically certain. Cases are, however, encountered from time to time in which death takes place during an attack, and there were seven in this series in which death was due, directly or indirectly, to a paroxysm.

Case 16. A woman, aged 44, was admitted to the hospital on the seventh day of a paroxysm of auricular tachycardia with signs of congestive failure. Shortly after,

she had a femoral embolus and a little later, during a recurrence of her tachycardia, a cerebral embolus from which she died.

Case 18. A boy, aged 4, had had repeated attacks of tachycardia since the age of 2, on many occasions developing signs of congestive failure. Injection of the cervical ganglia was carried out with some success, but finally, after numerous and almost continuous paroxysms, he had a cerebral embolus and died.

Case 10. A man, aged 42, started with paroxysms of auricular tachycardia at the age of 16. At 26, he had joint pains and " heart trouble." The attacks of tachycardia became frequent, being associated with loss of consciousness, hæmoptysis, and pulmonary œdema on one or two occasions. Between the attacks he was able to work as a carpenter. He was finally admitted in an attack with acute pulmonary œdema from which he died. He had " tight " mitral stenosis.

Case 29. An obese woman, aged 48, developed paroxysmal auricular tachycardia the morning following bilateral salpingo-oophorectomy and hysterectomy. She became unconscious, with a blood pressure of 80/60, and died 8 hours after the onset. EC., paroxysmal auricular tachycardia, rate 180.

Case 30. A woman, aged 42, had had a difficult and prolonged convalescence following an operation for intestinal obstruction. Paroxysmal tachycardia set in 24 hours before death, and did not respond to any treatment. She died after the rapid development of failure (B.P. 60/30). Autopsy showed an apparently normal heart.

Case 31. A woman, aged 57, developed paroxysmal auricular tachycardia, at a rate of 220, with the picture of profound surgical shock. The temperature gradually rose, and she died in circulatory failure, 12 hours after onset. Her blood pressure was 110/80, her usual pressure being 200/100. Autopsy showed a normal heart.

Case 55. A boy, aged 2, started very frequent paroxysms of auricular tachycardia following pneumonia and whooping cough with the development of congestive failure. No treatment was of any avail and he died.

Very little comment is needed on these cases. Three of the deaths occurred in patients who were already sick from severe major operations. The tachycardia, with the production of profound shock, superimposed upon the trauma of the operation, merely proved to be the straw that broke the camel's back. Two of them, it will be seen, developed cerebral emboli. Just as there is always a possibility of cerebral emboli in auricular fibrillation so too the same possibility is always present in a paroxysm of tachycardia that continues for any length of time, especially when congestive failure develops. Case 10 illustrates the danger that is always present in those who have both mitral stenosis and paroxysmal tachycardia. Five others were encountered with mitral stenosis and severe pulmonary œdema from paroxysmal tachycardia, but without a fatal termination.

The Remote Effect of the Paroxysms

Numerous individual cases in which attacks have occurred over several years have been reported (e.g. Palmer, 1937; Cowan, 1939). Hume (1930) collected a series of 130 cases in which the average duration was over 30 years, while Campbell and Elliott (1939) reported in their series of 100 cases, a group of 28 with apparently normal hearts whose paroxysms had been occurring for an average of 23 years. There were two deaths during the attacks in this group. There is no reported evidence to suggest that permanent organic heart disease may be produced by such repeated paroxysms.

In this survey, 80 cases with otherwise normal hearts were followed up. These, except for 4 hospital cases, were patients who had been seen in consultation and had had their paroxysms over a period of ten years at least. Of these 80, 57 were traced either by letter, through their own medical practitioner, or in person.

The average age of the group that has been traced was 58 years and the average length of time since the onset of the attacks was 25 years. The longest duration for any patient was 64 years. His attacks apparently caused no serious inconvenience and he classed them merely as a nuisance.

Case 32. A man aged 72, had had his first attack at the age of 7. Since then he had had 1 to 2 attacks of tachycardia for a year, varying from 6 to 24 hours in duration. When last seen, he had diabetes and mild coronary disease, and had 6 to 8 attacks a year which were well controlled with quinidine. He was still very active.

It was found that five of the patients had died, but there was no evidence to associate the paroxysms with the deaths of any of the first three patients.

Case 37. A woman, aged 52, had had paroxysmal tachycardia for approximately 25 years. She died following an operation for gallstones, but the exact details were unknown.

Case 38. A man, aged 69, had had 6 to 8 attacks a year for 32 years. He died of pneumonia despite a week in an oxygen tent.

Case 39. A woman, aged 75, had had paroxysmal auricular tachycardia for 15 years. The exact cause of death was not known.

Case 40. A man, aged 55, had had paroxysmal auricular tachycardia for 40 years. Over the last 4 years of his life, he suffered with symptoms of hypertensive coronary heart disease. The paroxysms became very much more frequent and congestive failure was precipitated. He died at home, but the details could not be obtained.

Case 26. A woman, aged 50, had had paroxysmal auricular tachycardia for 18 years. It had been extremely troublesome the whole period, at times causing slight cardiac enlargement. She died following an operation for carcinoma of the breast. Autopsy showed a recent auricular infarct.

Unfortunately no adequate histological studies had been carried out on this case and the heart was not available for re-study. The patient herself had been otherwise healthy and able to carry out her duties as a nurse. One can only speculate as to what modifications there may have been in the blood supply of the S-A and A-V nodes. The abnormalities of rhythm during the paroxysms in this case have been reported by Sprague and White (1925).

Thus, concerning the prognosis in patients with paroxysms occurring over many years, there seems to be no conclusive evidence in this small series to justify any adverse statement and, indeed, medico-actuarial figures suggest that such patients have a slightly better expectation of life than normal.

According to Campbell and Elliot, the prognosis of paroxysmal auricular tachycardia " as regards life is excellent, unless appearing relatively late in life it is the first indication of disease of the coronary arteries or unless before the paroxysms have started there is already serious heart disease. In general, the prognosis depends on the condition of the heart muscle and should be decided

without reference to the paroxysms." It is not, however, our experience that the prognosis is poor, even coming on late in life, and the following two cases are examples of the relative insignificance of attacks in the majority of such patients.

Case 34. A woman, aged 78, began to have rather frequent attacks at the age of 56. These continued until about three years ago when they practically disappeared. She now writes of her excellent health—no doctors, no medicine, and the ability to undertake five-hour train journeys by herself.

Case 35. A woman, aged 80, started to have attacks when 56, with occasional paroxysms lasting three to six hours. She now has slight hypertension, but is quite active.

Moreover, a survey of 398 consecutive cases of paroxysmal tachycardia seen in consultation showed that there were 69 with coronary heart disease and/or hypertension, with the onset of the arrhythmia after the age of 40. Included among these there were 16 patients with coronary thrombosis. Out of 128 patients with otherwise normal hearts in this same series, 57 started their attacks after the age of 40. Thus, excluding the cases of coronary thrombosis, there were approximately equal numbers with and without organic heart disease starting after the age of 40. The whole of this group has not been followed up, but a large number of the patients had been re-examined from time to time; most of the remainder were first seen four to five years after the onset of the tachycardia. These patients, therefore, form a group from which it is possible to draw some conclusions as to the prognostic significance of tachycardia arising in the second half of life.

Two patients of this older group with apparently normal hearts died unexpectedly. The first died following an operation for gallstones at the age of 52; and the second, a man, also aged 52, died while swimming, one year after he had been diagnosed as having an irritable normal heart. In neither of these were the exact details as to the mode of death available. Even taking into consideration these two deaths, the impression was left that only in a very few of the cases with apparently normal hearts was paroxysmal auricular tachycardia the first symptom of serious organic heart disease.

In the group that already had coronary disease, the attacks of tachycardia did not appear to make any appreciable difference to the ultimate prognosis.

Master, Dack, and Jaffe (1937) studied the arrhythmias that were found in 300 cases of acute coronary thrombosis and found 9 (3 per cent) with paroxysmal auricular tachycardia. Only 2 died (a result of the thrombosis), and it was considered that patients with paroxysmal auricular tachycardia usually survived.

Frequent paroxysms might justify a more serious prognosis in a damaged heart than the organic disease itself warrants. It would be logical to suppose that a severe paroxysm of auricular tachycardia with its attendant low blood pressure might easily precipitate a coronary thrombosis. Indeed, the descriptions in some of the earlier reports (e.g. Bristowe, Bouveret) suggest this possibility. In none of the cases in our series was there any evidence to show that such an event had taken place. However, it might be exceedingly difficult to determine which occurred first, the tachycardia or the thrombosis.

To sum up, paroxysmal auricular tachycardia arising in later life, may warrant a more serious prognosis in individual and comparatively uncommon cases, but as a general rule, the attacks have little or no influence on the ultimate outcome.

Prognosis as to the frequency of the attacks.—It is difficult to give any forecast as to the possibility of gaining complete freedom from the attacks. Some patients, such as Case 41, had attacks every two to three weeks and became very disheartened because the attacks showed no improvement and, as the years went by, became very much more frequent: while others, such as Case 42, suddenly had complete remission. This patient had increasingly frequent attacks for five years until the tachycardia became almost constant and signs of congestive failure were present: then following treatment with quinidine, she has been entirely free from attacks for fourteen years.

The patient with the most frequent attacks was Case 43, who stated that he had as many as 10 to 12 attacks in a day and that the attacks had been present for the past 25 years.

The prognosis of any given case is inextricably bound up with treatment. Some patients seem to undergo a spontaneous cure, others react to specific treatment, and a number continue unchecked by any measure whatsoever. It seems impossible to foretell in what way a given case will react. As a rough guide, the patients who are extremely neurotic and have developed a marked degree of neurocirculatory asthenia, have a poor chance of getting rid of the attacks.

Duration of the attacks.—Attacks of long duration have been recorded by many writers (Bouveret; Bristowe; Hamilton and Hurvitz, 1932; Gallavardin; Veil and Froment, 1930; Marvin, 1923). It has also been emphasized frequently that such attacks of long duration are uncommon. One infant, aged 18 months, was seen in whom paroxysmal auricular tachycardia had been present for over twelve months; she was otherwise a perfectly normal and well-developed child.

Lewis (1936) states that the attacks in each individual patient are usually of the same duration. We have found, however, that the duration of the attacks is extremely variable. It is, therefore, impossible to give a forecast of the length of any future paroxysm, although one can usually safely say that paroxysms of more than 24 hours in duration are uncommon.

Prognosis in Paroxysmal Auricular Fibrillation

Parkinson and Campbell (1931), as a result of their review of 200 cases of paroxysmal auricular fibrillation, considered that the prognosis in the immediate attack was excellent as it would seldom last more than two days, and that the ultimate prognosis depended mainly on the condition of the heart muscle independently of the paroxysms; though these increased the risk of fibrillation becoming established, which happened in almost one quarter of all the cases and in a higher proportion of those with rheumatic heart disease or with very frequent paroxysms. They made no actual statement, however, as to the

prognostic meaning of attacks in a damaged heart, whether such attacks would mean a more serious prognosis than a similar heart without such attacks.

White and Bland (1931) in a report on the prognosis of angina pectoris and of coronary thrombosis, found that the incidence of paroxysmal auricular fibrillation was low in both conditions. In the 500 cases of angina, there were only 11 examples and 4 others in which the attack occurred as a terminal event. In the 200 cases of coronary thrombosis, attacks of fibrillation occurred at the time of the actual thrombosis in 13: of these, 4 died after one month and within one year, and 5 others were still alive after four years. From their experience, fibrillation did not seem to increase the gravity of the prognosis.

Master, Dack, and Jaffe (1937) in their 300 cases of acute coronary thrombosis, found 22 with fibrillation. In half these there had been a previous paroxysm. The average age of the group was 60 and the males predominated in the ratio of 2 to 1. In 18 there was a history of previous hypertension. 10 cases died, 5 during the period of the arrhythmia. Comparing the mortality of the cases with and without arrhythmia in acute thrombosis, they found a slightly increased mortality in the cases with fibrillation. They concluded that the relatively low incidence of abnormal rhythms was due to the copious blood supply to the A-V node protecting it from serious damage.

We found the incidence of auricular fibrillation in a consecutive series of 1400 cases of angina pectoris and coronary thrombosis to be small, only 4 per cent. Many of these, who had coronary heart disease when first seen, were followed for several years until they finally died in a ripe old age. In none of them could it be said that auricular fibrillation had accelerated death. For example, one patient, a physician, had had attacks every three to six months for the past 28 years and was still active at the age of 83, though he had also intraventricular block. Another example is Case 47, who was still active though restricted at the age of 73 after attacks over the previous 14 years. One woman, aged 76, who had had attacks for the past 5 years, successfully underwent an operation for carcinoma of the breast.

In 1936, Orgain, Wolff, and White reported on the prognosis of paroxysmal auricular fibrillation occurring in otherwise apparently normal hearts. They were able to follow up 40 cases out of a group of 46. They concluded that the prognosis for life and for the maintenance of adequate cardiac function was, with rare exceptions, excellent. These cases with the addition of numerous private and of 4 hospital cases give a series of 88 cases. The diagnosis of paroxysmal auricular fibrillation and a heart otherwise normal had been made in every one of the 88 cases. The abnormal rhythm had been diagnosed by a physician in 26 cases, by a characteristic history in 10 cases, by physicians on themselves in 3 cases, and in the remaining 49 cases by electrocardiogram. Of these, 78 were traced either in person, by letter, or through their local practitioner.

Of the 78 cases that were traced, 22 were found to have died. The ages of onset and at death of these cases, and comments as to the mode of death, have been listed in the appendix. It will be seen that 6 died with auricular fibrillation complicating toxæmia, operation, or infection; 7 died of cardiac causes, chiefly

coronary thrombosis; 6 died unexpectedly; and 3 died of causes probably not connected with the heart, most likely of cancer. In none of the 4 cases of coronary thrombosis was there an autopsy. In the 6 who died unexpectedly, one must assume that there was in each case a cardiac cause, most probably coronary thrombosis. There were only 2 who were under the age of 40 at the time of death, and they were both given to alcoholic excess.

The 56 living patients may be divided into groups for the better estimation of the prognosis: 13 of the survivors were physicians and will be considered separately.

(*a*) *Age of onset between* 40 *and* 60, *and the time since onset more than two years.*—This group contained 23 cases, the average age of onset being 49 years and the average duration since the onset being 12 years. The number of other cases in this age group who had died was 16, of whom 4 died following operation or infection. Excluding these 4, the average duration from onset to death of the remaining 12 was 13 years, and the average age of onset approximately the same as for the whole group. Of the 23 alive, 6 developed signs of coronary insufficiency, either clinical or electrocardiographic. These developed 16, 15, 10, 8, 6, and 4 years after the onset of the paroxysms.

In this group, paroxysmal fibrillation may be the first signs of a serious heart disease, but there does not seem to be any evidence to suggest that the prognosis is any other than that of the underlying heart disease when it becomes evident.

(*b*) *Age of onset below* 40, *and duration more than two years.*—This group contained 16 patients that were living, with an average age at onset of 26 years and duration of 19 years. Excluding one who died of infection and alcoholism, 3 others died after 16, 13, and 8 years, respectively. Only one of those alive appears to have developed cardiac insufficiency, 32 years after the onset, at the age of 70.

The prognosis in this group appears to be excellent.

(*c*) *Physicians.*—This group contained 14 physicians. Only one of these has died. He developed hypertension and permanent auricular fibrillation, eventually dying of carcinoma of the œsophagus 24 years after the onset. The average age of onset was 42 years, and the average duration, in 12 of the doctors who had had attacks for more than two years, was 24 years. This high incidence in doctors was noted by Parkinson and Campbell. It suggests that the condition is more common than is usually supposed and that the prognosis is good.

(*d*) *Miscellaneous group.*—One man whose attacks came on at the age of 75 was still alive at the age of 86 although his exact condition was not known. In this group there were 3 patients with the abnormal complexes of the type described by Wolff, Parkinson, and White. They were all well after 1, 8, and 18 years, respectively. There were 9 patients who had only one attack. These were still healthy.

To sum up, the occurrence of paroxysmal auricular fibrillation should be regarded in general as having no serious prognostic significance, but when occurring in patients over the age of 40, it may be the first signs of organic

heart disease, in which case the prognosis given will depend upon the appearance and severity of the coronary heart symptoms.

Frequency and duration of paroxysms.—As in paroxysmal auricular tachycardia, it is impossible to give any forecast as to either the frequency, the duration, or the prospects of gaining complete freedom from the attacks. In those getting paroxysms with increasing frequency, permanent fibrillation eventually sets in. Occasionally, however, the paroxysms will be frequent for four or five years, causing very great inconvenience and discomfort, and no measure will give any relief until the onset of permanent fibrillation.

In rheumatic heart disease, it is usually thought that paroxysmal fibrillation heralds the approach of permanent fibrillation in the near future. In one patient, however, attacks were frequent for 13 years before this happened. Another had had attacks for 13 years; she was still working, having both mitral and aortic rheumatic disease. Yet another, with a similar heart lesion, had had paroxysmal auricular tachycardia for 10 years, and then for the last 3 years paroxysmal auricular tachycardia and auricular fibrillation. She recognized the difference in rhythm by the difference in the "position of the palpitation" in her chest.

A patient with a probable inter-auricular septal defect had her attacks for the greatest period of time without the occurrence of permanent fibrillation. They started when she was 13, and when last seen she was 58; her activities then were severely curtailed by angina pectoris.

The actual attacks themselves are short. In over half of the total series of 88 cases, they lasted less than 24 hours, and of these the most usual duration was less than 12 hours. Parkinson and Campbell consider that attacks lasting over seven days tend to be permanent, unless treated with quinidine. This is probably true, but with the introduction of quinidine, the outlook is changed. Case 51 had frequent paroxysms of fibrillation, one of which lasted for over three months before he was treated with quinidine. He was well nine years later, with normal rhythm, and was exceedingly active professionally. There were several cases of a similar nature in this survey. With an adequate maintenance dose of quinidine, the prognosis for the continuation of normal rhythm is good.

The prognosis of paroxysmal auricular flutter is essentially that of paroxysmal auricular fibrillation. Orgain, Wolff, and White (1936) recorded 7 cases in patients otherwise normal. It was possible to trace 6 of these who were still alive and well—29, 18, 7, 17, 32, and 9 years, respectively, after the onset. These findings confirm the good prognosis given in the original paper.

Summary and Conclusions

When the cardiovascular system is normal, attacks of paroxysmal tachycardia are uncomfortable, but relatively unimportant incidents.

The probability of any attack ceasing is extremely good, but the occurrence of an attack in a patient seriously ill must be regarded with some apprehension, and the occurrence of heart failure as a result of the attack may lead to the formation of intracardiac thrombi and subsequent emboli.

The occurrence of paroxysmal auricular tachycardia in apparently healthy persons seems to have no effect upon the prospect of their longevity. When occurring late in life, the prognosis, in general, is that of the underlying heart disease, if present.

Paroxysmal auricular fibrillation is probably common. When occurring in patients below the age of 40, it may be considered as having no prognostic significance, while in later life the occurrence of fibrillation may, in some cases, be the first sign of serious heart disease.

It is impossible to forecast with any certainty either the frequency or the duration of the attacks of paroxysmal auricular tachycardia and fibrillation.

The basis of this paper formed part of a thesis submitted by one of us (W.T.C.) and accepted for the degree of M.D. of the University of Cambridge. The work was carried out while W.T.C. was holding a Research Fellowship in Medicine, Harvard University, and the Walter Myers Travelling Studentship, Birmingham University, 1938–1939.

References

Bouveret, J. (1889). *Rev. Med. Paris*, 60, 753, 839.
Bristowe, J. S. (1888). *Brain*, 10, 164.
Campbell, M., and Elliott, G. A. (1939). *Brit. Heart J.*, 1, 123.
Cowan, J. (1939). *Brit. Heart J.*, 1, 3.
Gallavardin, L., Veil, P., and Froment, R. (1930). *J. Med. Lyon.*, 11, 517.
Hamilton, B. E., and Hurvitz, D. (1932). *Amer. Heart J.*, 7, 274.
Herringham, W. P. (1897). *Edin. Med. J.*, 1, 366.
Hume, W. E. (1930). *Lancet*, 2, 1055.
Lewis, T. (1936). *Diseases of the Heart, London.*
Marvin, H. M. (1923). *Heart*, 10, 279.
Master, A. M., Dack, and Jaffe, H. L.(1937). *Ann. intern. Med.*, 11, 735.
Orgain, E. S., Wolff, L., and White, P. D. (1936). *Arch. intern. Med.*, 57, 493.
Palmer, J. H. (1937). *Medical Research Council, Special Series, No.* 222.
Parkinson, J., and Campbell, M. (1930). *Quart. J. Med.*, 23, 67.
Sprague, H. B., and White, P. D. (1925). *M. Clinics. N. Amer.*, 8, 1855.
White, P. D., and Bland, E. F. (1932). *Amer. Heart J.*, 7, 1.
Wolff, L., Parkinson, J., and White, P. D. (1930). *Amer. Heart J.*, 5, 685.

APPENDIX

Deaths that have Occurred in 22 out of 78 Cases with Paroxysmal Auricular Fibrillation and Hearts otherwise Normal.

Sex,	Age at Onset,	Age at Death	Comments as to Mode of Death, etc.
M.	53	76	Apparently enjoyed excellent health until two hours before death, which was assigned to coronary thrombosis. Had taken daily quinidine which controlled paroxysms.
M.	59	71	Took quinidine, 6 grains daily, and had occasional paroxysms. Died of coronary thrombosis following golf. No previous symptoms suggestive of coronary insufficiency.
M.	54	74	Angina pectoris one year before death, and much more frequent attacks of paroxysmal fibrillation. Died suddenly, but no details available.
F.	57	66	Asthma for thirty years, and died during an attack. Post-mortem: recent thrombosis in the left ventricle.
M.	44	62	Last three years of life, under treatment for hypertensive coronary heart disease; rhythm normal all this time. Autopsy: old coronary thrombosis.

Sex, Age at Onset, and Age at Death			Comments as to Mode of Death, etc.
F.	49	70	Died of carcinoma of stomach, attacks of fibrillation having continued without other cardiac symptoms until death.
M.	35	59	Hypertension and permanent auricular fibrillation for last five years of life. Died from carcinoma of œsophagus.
F.	45	65	Died after an acute intestinal infection and signs of mental upset. Her doctor stated: no evidence that heart played any part in her death.
F.	48	51	Quite well for three years prior to her death. On returning to work following pneumonia, she dropped dead.
M.	52	68	Free from attacks for the last seven years of his life. Died unexpectedly, but details not known.
F.	64	68	Died following a convulsive seizure and a number of attacks of congestive failure. Fibrillation not present at time of death.
F.	29	42	Died with acute pulmonary œdema following an epileptic attack. No other details available.
F.	44	53	Died suddenly three years after being passed as having an irritable normal heart. Permanent fibrillation was thought to have set in.
F.	48	51	Follow-up study revealed she was dead, but details unknown.
M.	27	35	Died in congestive failure, with permanent auricular fibrillation. Alcoholic excesses played a major role.
F.	52	56	Asthma for twenty years. Died during a paroxysm of auricular fibrillation following a severe septic throat.
F.	51	51	Paroxysm of auricular fibrillation during erysipelas. Normal rhythm restored with quinidine, but died three months later, details unknown.
M.	53	53	Right-sided empyema for one year. Developed auricular fibrillation when this was reopened and died ten days later. Autopsy showed normal heart.
F.	58	58	Developed paroxysmal auricular fibrillation following an operation for rectal malignancy. Autopsy showed normal heart and lungs.
F.	66	66	Developed a severe sore throat a fortnight before death. Collapsed with onset of auricular fibrillation and died ten days later. Autopsy showed normal heart.
F.	57	57	Collapsed following an operation. Had auricular fibrillation for two days and died two days later. Autopsy showed normal heart.
M.	35	35	Developed auricular fibrillation following exposure and alcoholic excess. Died of tetanus.

FAINTING AND FITS IN CARDIAC INFARCTION

BY

HAROLD COOKSON

Received September 18, 1942

Thoracic pain, the cardinal symptom, may be absent in acute cardiac infarction, the best known equivalents being dyspnœa or other signs of congestive failure, and more rarely abdominal and cerebral syndromes. With pain of great intensity, syncopal symptoms may occur also as a result of cerebral vascular complications, and sudden death, which is not infrequent in this condition, can be regarded as the extreme form of syncopal attack. But occasionally disturbances of consciousness are a most prominent feature of the attack apart from all these conditions, with pain absent or displaced into the background. This is especially so at the onset of the attack. Many papers on cardiac infarction without much or any pain have referred mainly to patients with congestive failure, and disturbances of consciousness have not often been mentioned. (Bean & Read, 1942; Boyd & Werblow, 1937; East & Bain, 1928; Gorham & Martin, 1938; Gross & Sternberg, 1939; Hay, 1933; and Kennedy, 1937.) In the present series, seen among some 200 cases of acute cardiac infarction, syncopal symptoms were prominent in 15, in 10 at the onset and in 5 in the course of the illness.

Syncopal Attacks at the Onset

Of 10 patients in whom cardiac infarction was ushered in by a syncopal attack (Table I) 5 were men and 5 women. The average age was advanced, five being 70 or more. Consciousness was partly or completely lost in all, but no convulsion was observed. The patient's appearance was that of severe shock or peripheral circulatory failure, the radial pulse being usually imperceptible, the skin pale and moist, and vomiting almost invariable. Of eight patients in whom the heart rate was known during the syncope, it was slow (50 or less) in five, in two there was sinus tachycardia, and in one with ventricular tachycardia the rate was 160. No cardiogram was obtained during these initial symptoms, but in one instance (Case 7) in which sinus bradycardia was recorded, pallor and a complaint of faintness while the tracing was being taken coincided with a drop in rate to about 24 a minute. In most of the other cases cardiograms taken between the second day and sixth week of the illness showed abnormal rhythms. In one and probably in a second there was A-V nodal rhythm, in two auricular flutter, in one auricular fibrillation, and in one ventricular tachycardia. The site of infarction could be located in nine; six in the posterior wall, three in the anterior wall, and the remaining

one probably also of the anterior type. Pain was absent or slight in five, moderate in four, and severe in one; in two it was confined to the abdomen. Six patients died between the first day and the fourth month, three from congestive failure, one after a hemiplegia, one suddenly, and one with symptoms of shock. The four survivors, who have lived an average of about three years since the attack, were with one exception the youngest of the group. None of these patients had previously suffered from any serious cardiac symptoms. In two there had been previous symptoms of cerebral origin and in five a high blood pressure reading was obtained at some time.

TABLE I

SYNCOPE AT ONSET IN CARDIAC INFARCTION

Case No., Sex, and Age	Attack	Rhythm Recorded	Site of Infarction (*above*) and Degree of Pain (*below*)	Result
1. M./72	Unconscious; no pulse; heart 48.	Nodal rhythm (8 days later).	Anterior. None.	Failure. Died 8th day.
2. M./62	Fainting; no pulse; heart 35.	? Nodal rhythm; short runs V.P.T. (six weeks after onset).	Posterior. Moderate.	Failure. Died 7th week
3. F./79	Fainting; ? heart rate.	Auricular flutter (2nd day).	Posterior. Severe (abdomen).	Hemiplegia. Died 15th day.
4. M./44	Fainting; ? heart rate.	Auricular flutter (20th day).	Posterior. None.	Well 2 years later.
5. F./72	Fainting; no pulse; heart 44.	Auricular fibrillation (8th hour).	Anterior. Moderate.	Died suddenly 1st day.
6. F./55	Fainting; pulse 160.	Ventricular tachycardia (4th day).	? Anterior. Slight (abdomen).	Failure. Died 4th month.
7. M./45	Fainting.	N.R. rate 33.	Posterior. Slight.	Well 1 year later.
8. F./70	Fainting; pulse 50.	N.R.; rate 75 (10th day).	Posterior. None.	Well 3 years later.
9. M./53	Fainting.	N.R., S.A.; rate 70 (2nd day).	Posterior. Moderate.	Well 5 years later.
10. F./82	Fainting.	N.R.; rate 120 (2nd day).	Anterior. Moderate.	Died 3rd day.

N.R.—Normal rhythm. S.A.—Sinus arhythmia.
V.P.T.—Ventricular paroxysmal tachycardia.

Case 1.* An active man of 72, previously well except for moderate hypertension and some transient cerebral symptoms one year before, was found unconscious just after he had gone to bed. When his doctor arrived, radial pulse imperceptible, some vomiting, heart rate about 48, and sounds only just audible. Next day the rate rose to 55 and remained there until death. Congestive failure developed within a day or

* All patients were seen in private practice and post-mortem examination was not possible in any.

two. The rhythm (Fig. 1) has been classed as nodal but resembles those recorded from subjects free of heart disease with physiological short P–R bundle branch block curves. Any of the interpretations that have been suggested for such curves would apply equally to this one. There are changes in the RS–T segments suggesting anterior infarction, though in lead IVR they are atypical.

Case 2. A man, aged 62, fell down in a faint when walking home. When seen by his doctor, he was sweating, bluish-gray in colour, some epigastric pain, radial pulse imperceptible, heart rate about 35. After vomiting, condition improved and next day perfectly well; heart rate still 35. After ten days allowed up but ten days

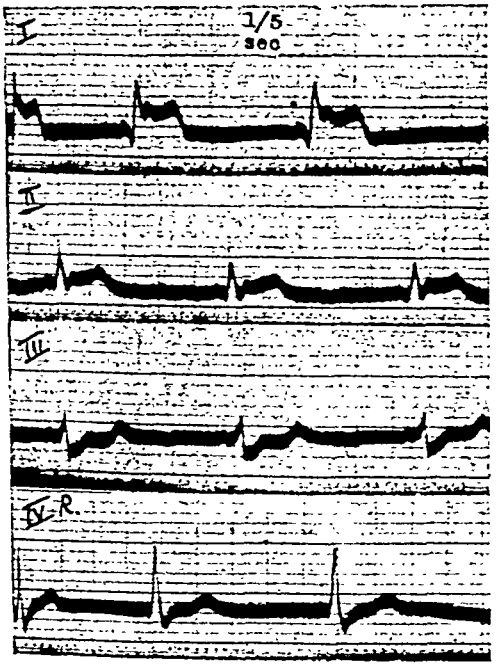

FIG. 1.—Case 1. Taken on the eighth day, a few hours before death. Regular rhythm, rate 60; short P–R interval, wide QRS complex.

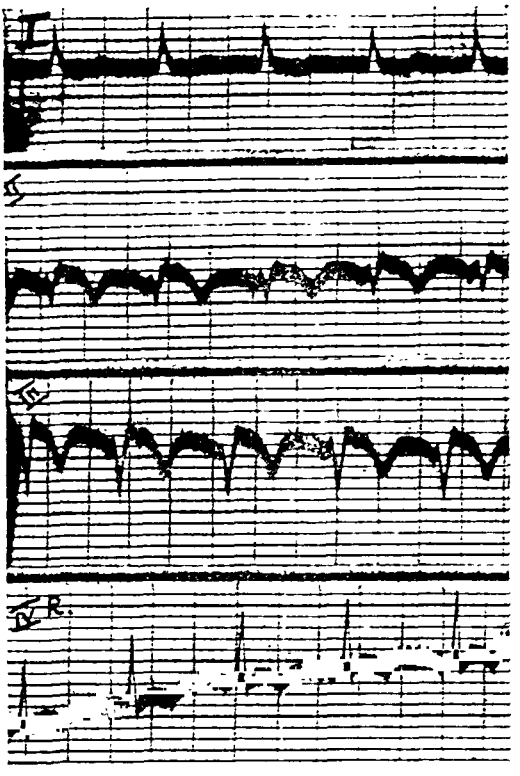

FIG. 2.—Case 4. Taken on the twentieth day. Auricular flutter (A. about 230 with 2 : 1 block); RS–T and T changes suggesting posterior infarction.

later some abdominal discomfort, dyspnœa, œdema in the feet and back, and rales at the lung bases. In the sixth week, the B.P. was 180/90, and there was severe orthopnœa and systemic venous congestion. Cardiogram: a basal ventricular rhythm, probably nodal, rate of 60 to 70, P wave absent; ventricular extrasystoles, some interpolated, sometimes multiple; left axis deviation, QRS low voltage; RS–T depressed in lead I, elevated in lead III; posterior infarction. Two days later the patient vomited and died suddenly.

Case 3. A woman of 79, previously quite well, fainted in a lavatory. When seen by her doctor, severe upper abdominal pain, which next day was felt only in the left iliac fossa; there was dyspnœa, cold skin, sweating, and cyanosis; many fine rales at the left lung base; B.P. 120/100. Cardiogram: auricular flutter, A. 240 with variable 2 : 1, 3 : 1 block, right axis deviation; elevation of RS–T segment in all leads, T_2 and T_3 inverted, Q_3 present. Posterior infarction. Good progress until

the twelfth day when a sudden left hemiplegia was followed by her death three days later.

Case 4. A healthy man of 44 felt short of breath while playing golf; later became faint, vomited, and had a cold sweat. During next few days, slight icteric tint of the skin, systolic B.P. under 100, and some dyspnœa. Fig. 2 suggested posterior infarction. He was given digitalis, and 13 days later cardiogram showed normal rhythm, rate 85, P–R interval 0·35 sec., frequent ventricular extrasystoles some interpolated, RS–T deviation and T inversion less. Good progress, and well two years later.

Case 5. A woman of 72, previously well, fainted and then vomited. When seen by her doctor soon after, radial pulse imperceptible, but later palpable, rate 44; complained of pain behind mid-sternum, in jaw, and in left arm. Cardiogram taken nine hours after onset showed auricular fibrillation, ventricular rate about 165, QRS complex wide, R absent in lead IVR; RS–T deviation upward in leads I and IVR, downward in leads II and III. Anterior infarction. A few minutes after this was taken she died suddenly.

Case 6. A woman of 55 with hypertension for some years, hemiplegia two years before, and transient blindness one year before. In bed with epigastric pain for two or three weeks. Sudden faint attack with ashen colour, heart rate of 160, and orthopnœa. Four days later, Fig. 3 showed ventricular tachycardia, and two days

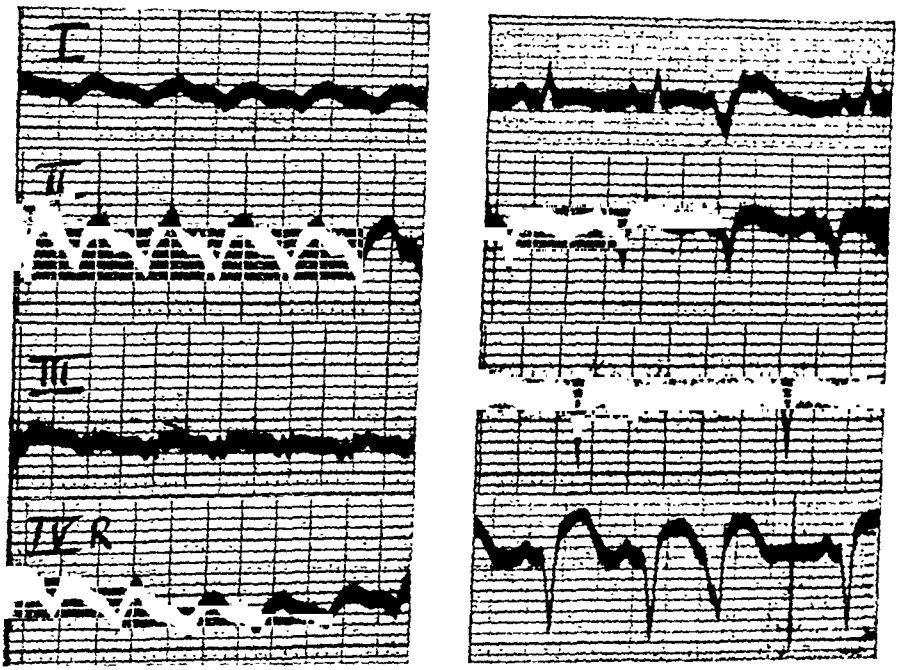

FIG. 3.—Case 6. (A) Taken on the fourth day. Ventricular tachycardia, rate 155. (B) Two days later after 15 grains of quinidine. Normal rhythm, rate 95; R wave absent in leads II, III, and IVR; upward deviation of RS–T in all leads; occasional ventricular extrasystoles.

later after quinidine, normal rhythm. Periodic dyspnœa during the following weeks with a right pleural effusion. Then œdema of the legs which cleared up, but after increasing weakness the patient died in the fourth month.

Case 7. A man of 45 had some sternal discomfort after a day's shooting; he slept well and felt well next morning but fainted after a bath. When seen by his doctor, colour gray and some upper sternal discomfort; pulse rate was 40. Six hours

later comfortable, apex beat much out and heaving; B.P. 140/80. Fig. 4 showed sinus rhythm, at rate of 33 a minute. During the tracing heart rate varied and at the slower rate (under 24), pallor and faintness. Cardiogram nine weeks later, similar except for rate of 75, no deviation of RS–T segments, T_2 just negative, T_3 inverted. Well 15 months after the attack.

Case 8. A woman of 70 fainted without obvious cause; no pain but some sensation of wanting to defæcate; when seen, pulse rate 50 regular. Known to have had B.P. of 220/100 four years before. On the tenth day, comfortable, with no signs

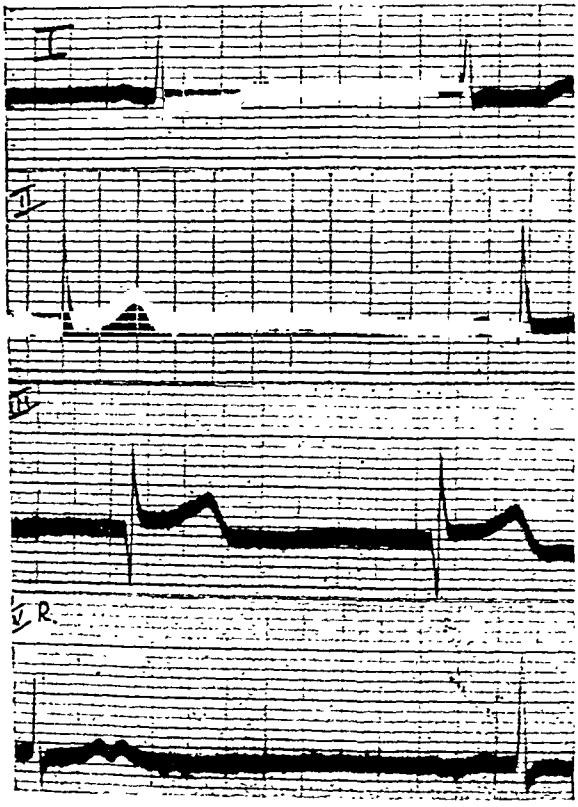

FIG. 4.—Case 7. Sinus rhythm, rate 33; P–R interval 0·20 sec.; P wave notched; small Q_2, large Q_3, QRS complex rather wide; RS–T depression in leads I and IVR, elevation in II and III; suggesting posterior infarction.

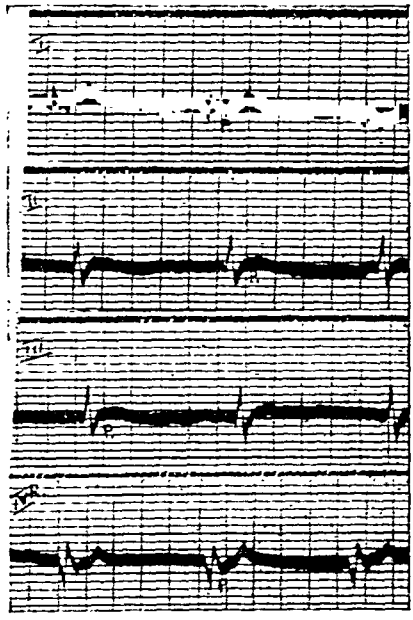

FIG. 5.—Case 11. Taken ten hours after the onset. Rhythm almost regular, rate 55; QRS, 0·1 sec.; negative P following QRS; RS–T slightly depressed in leads I and IVR, slightly elevated in leads II and III. Nodal rhythm; intraventricular block; posterior infarction.

of failure; B.P. 230/110. EC. showed normal rhythm, rate 80, QRS complex 0·09 sec., slight depression of RS–T in leads I, II, and IVR, T_2 diphasic, T_3 inverted; small Q_3; occasional ventricular extrasystoles. Three years later fairly well but auricular fibrillation; Q_3 no longer present and T_2 and T_3 upright.

Case 9. A man of 53, a chronic alcoholic, had fainted and then complained of upper sternal pain. When seen immediately by his doctor, sweating and colour ashen; pulse 68, regular. Next day felt well; B.P. 110/80, liver enlarged, no signs of failure. Cardiogram: normal rhythm, rate 70, QRS complex low voltage, T_2 just negative, T_3 inverted. Posterior infarction. Good recovery and no cardiac symptoms five years later.

Case 10. A woman of 82 fainted and had pain between shoulders with radiation into both arms. In bed next day, comfortable except for aching in back. No

dyspnœa; apex beat just out, loud systolic murmur at apex; B.P. 80/60. A cardiogram showed normal rhythm, rate 120 a minute; a very small R in lead IVR; slight depression of RS–T in leads II and III, and elevation in IVR; T wave in leads I and IVR just negative; suggests anterior infarction. Death occurred on the third day.

Syncopal Attacks in the Course of Cardiac Infarction

Observations were made on five patients with disturbances of consciousness in the course of cardiac infarction that had begun in a typical way with anginal pain (Table II). There were four men and one woman, and the average age was 69. In two there was loss of consciousness without any fit; the other three had Stokes-Adams attacks. The faint or fit occurred on the first day of the illness in two cases, while the latest was on the tenth day. Cardiograms showed nodal rhythm immediately before and after the attack in one; complete heart block during the attack and two hours after the attack respectively in two; sinus tachycardia and multiple auricular extrasystoles in one a few minutes after an attack; and sinus tachycardia between attacks in one. In four cases the site of the infarction was posterior; in the remaining one it could not be determined. Chest pain was moderate and of typical distribution in four cases, but in one it was severe and confined to an area below the left scapula throughout the illness. All five patients died within 29 days of the onset of the infarction. Previous anginal attacks had been experienced by two of them.

TABLE II

Syncope in the Course of Acute Cardiac Infarction

Case No., Sex, and Age	Attack	Rhythm Recorded	Site of Infarction (*above*) and Degree of Pain (*below*)	Result
11. F./79	Stokes-Adams (1st day).	Nodal rhythm (before and after).	*Posterior.* Moderate (chest).	Died 1st day.
12. M./67	Fainting (1st day).	C.H.B. (2 hours after attack).	Posterior. Moderate (chest).	Died 1st day.
13. M./69	Stokes-Adams (10th day).	C.H.B. (in attack).	? Moderate (chest).	Died 29th day.
14. M./69	Fainting (3rd day).	Sinus tachycardia and Aur. P.C. (after attack).	Posterior. Moderate (chest).	Died 4th day.
15. M./62	Stokes-Adams (5th day).	Sinus tachycardia (between attacks).	Posterior. Severe (back).	Died 10th day.

C.H.B.—Complete heart block. Aur. P.C.—Auricular premature contractions.

Case 11. A woman of 79 with old-standing hypertension, but a normal cardiogram five years before, and no cardiac symptoms. Retrosternal pain one morning through to the back with numbness of the forearm and wrists, lasted until relieved by morphia five hours later. Heart rate then 90 regular; B.P. 220/110. In after-

noon speech incoherent but had recovered by evening. Fig. 5, taken ten hours after onset, showed nodal rhythm, intraventricular block, and posterior infarction. Immediately after this curve had been taken, the patient became strange in manner; and vomiting, pallor, and stupor followed, and then a sudden brief tonic contraction of all limbs. The patient was then quite unconscious and cold and clammy, and the radial pulse could not be felt. The electrodes were still attached, and Fig. 6 showing

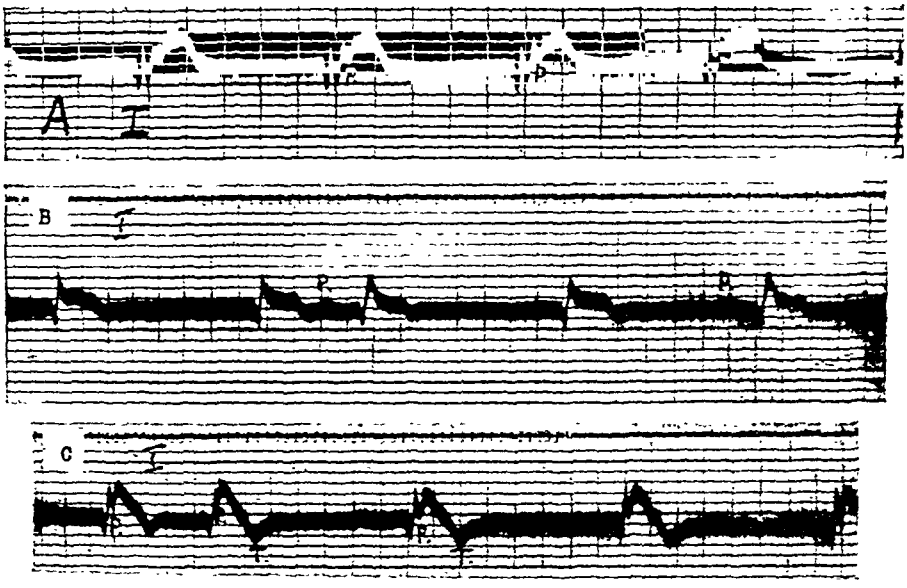

FIG. 6.—Case 11. (A) Nodal rhythm, rate 60; QRS, W-shaped; elevation of RS–T. (B) Taken ten minutes after (A). Change in the form of QRS; RS–T elevation less, with a very small negative T wave; a shallow negative P wave in the RS–T segment; the third and fifth cycles represent sinus beats with prolonged P–R interval.

(C) Taken after breathing had stopped. Nodal rhythm with one premature beat, increased upward deviation of RS–T and deeper inversion of T; rate about 40 a minute.

nodal rhythm was taken immediately. The rate continued to decrease and the voltage of the complexes to diminish until they finally ceased 25 minutes after the onset of the attack.

Case 12. A man of 67 woke at 6 a.m. with pain in the mid-chest radiating into both arms, neck, and jaw. He stayed in bed and at 3 p.m. was found unconscious. When seen by his doctor soon after, there was pallor, pulse imperceptible, heart irregular, rate 120. After a short time the pulse could be felt with a rate of 56. At 5 p.m. his skin was pale yellow and moist; some dyspnœa, cervical veins engorged; abdomen a little distended; apex beat heaving in anterior axillary line; heart sounds very distant; B.P. 100/60. Complete heart block (Fig. 7). Death occurred the same day. There was a history in this case of anterior infarction 5 years before and of paroxysmal dyspnœa on and off for 4 years.

Case 13. A man of 69 with effort angina for 18 months and a prolonged attack of rest angina 8 months previously. On the tenth day of a second attack of prolonged rest angina, Stokes-Adams attacks began and recurred at intervals of a few minutes. Between the seizures the pulse was irregular, rate about 100; during them the radial pulse could not be felt but as consciousness was regained the beating was resumed at the rapid rate. Fig. 8 taken between attacks shows partial heart block, and the lower strip of lead III taken during a Stokes-Adams attack shows complete heart block. Pulmonary congestion developed and death occurred immediately after a Stokes-Adams attack 19 days later.

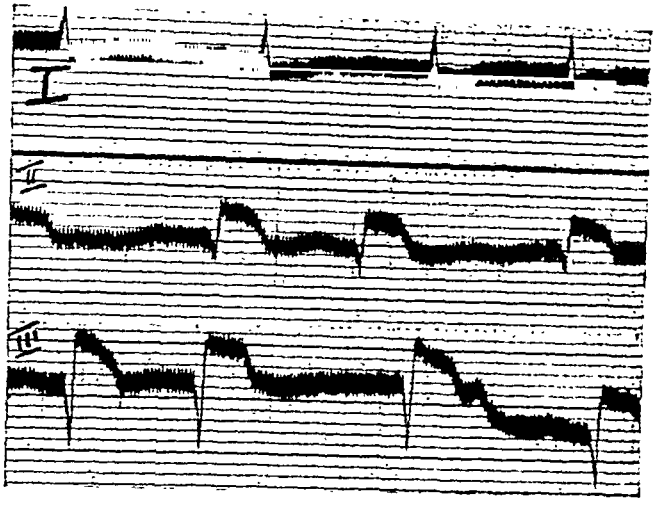

FIG. 7.—Case 12. Complete heart block with an occasional premature beat; ventricular rate 56; changes in QRS, RS–T, and T, suggesting posterior infarction.

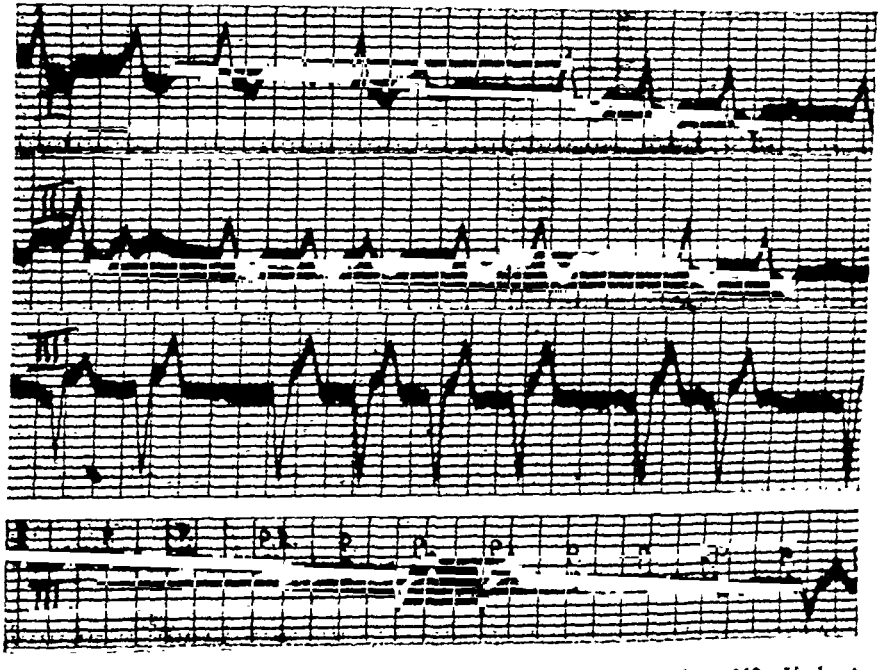

FIG. 8.—Case 13. Partial heart block and intraventricular block: A about 110; V about 100; occasional ventricular extrasystoles. The lower strip of lead III taken during a Stokes-Adams attack shows complete heart block; A, 110; V, 34: QRS and T very low voltage: the third, fourth, and sixth ventricular complexes represent a response to supraventricular impulses or alternatively ventricular extrasystoles.

Case 14. A man of 69 after three days of pain in the chest and left arm had repeated brief fainting attacks. There was recurrent vomiting but little dyspnœa; apex beat heaving in the anterior axillary line; radial pulse barely palpable, systolic murmur at the apex. Cardiogram on the third day showed sinus tachycardia with short runs of auricular extrasystoles; rate 135 per minute; RS–T depression in lead I, elevation in lead III; T positive in leads I and IVR, inverted in leads II and III; Q of 4 mm. amplitude in lead III. Posterior infarction. Death on the fourth day.

Case 15. A man of 62: slight chest pain for some months and pain below left scapula for five days. Pulse 120, completely irregular. Two days later dyspnœa, vomiting, irregular tachycardia, and persistence of the back pain which became worse while being examined, and the pulse was felt to become progressively slower and more feeble; there was extreme pallor, respiration stopped, and there was a generalized convulsion lasting a few seconds. Consciousness was regained immediately, the pulse returning with a rate of 108 and still completely irregular. The back pain was again distressing and was not controlled until 3/4 grain morphia had been given within half an hour. Slight pyrexia. B.P. 150/95, apex beat not palpable; no signs of failure. Cardiogram 8 hours later showed normal rhythm, rate 110 a minute; P–R interval less than 0 2 sec.; T_1 just positive, T_2 flat, T_3 just negative. Next day another Stokes-Adams attack, again preceded by intense pain in back. Some blood-stained sputum. On succeeding days further Stokes-Adams attacks and death on tenth day. Two other cardiograms taken between the attacks also showed sinus tachycardia with normal A-V conduction; there were progressive changes in the QRS complexes and T waves, consistent with posterior infarction.

Discussion

The syncope that sometimes marks the onset of cardiac infarction is generally accompanied by severe shock or peripheral circulatory failure, with an abnormally slow heart rate. It may come on very abruptly so that the patient has no warning before he falls to the ground. Anginal pain may be mild or absent throughout. Congestive failure follows, not infrequently, after a short interval. The prognosis in cardiac infarction with syncopal onset, judging from the ten cases reported here, among which there were six deaths within three months, is much graver than usual. However, the average age of these fatal cases was advanced, and the mortality of acute cardiac infarction in the elderly is very high. To produce the sudden syncope of the onset several factors are probably operating, but the principal one must be a nervous reflex leading to vasomotor depression and vagal stimulation causing bradycardia. A subsidiary effect is the reduced force and efficiency of systole that results from the inactivity of the infarcted area of myocardium. There is also the possibility of a direct ischæmic effect on the auricles causing bradycardia and abnormal rhythms. If so, it would fit in with the infarction being more often of the posterior type (excluding one case with ventricular tachycardia there were six posterior and three anterior infarctions), since according to Gross (1921) the right coronary artery takes a larger share in the arterial supply to the auricles. Further support for such an effect is the finding, both at the time of the attacks and later, of depression of the pacemaker and of auricular fibrillation and flutter. Cushing *et al.* (1942) found an abnormal auricular mechanism in 17 of 23 cases of auricular infarction. Finally the influence of age must be considered. This, when it reduces the elasticity of the arterial tree and when it is accompanied by degenerative vascular changes in the brain, must sensitize the cerebrum to any reduction in blood flow. Severe general

and focal cerebral symptoms in cardiac infarction, in the absence of any acute lesion in the arteries of the brain, have been described (Bean & Read, 1942).

Of the five cases here reported with syncope or fit occurring after the onset of cardiac infarction, it was possible to establish the mechanism of the heart beat during the actual attack in one only (Case 13): in this a Stokes-Adams attack coincided with a period of complete heart block, the ventricular rate falling from 100 to 34; cardiac standstill did not occur. As the attack terminated the original rhythm and rate was resumed. In Case 12 complete block was present two hours after a syncopal attack, and although an irregular tachycardia had been noted immediately after the attack, this does not exclude the possibility that it was determined by block, as Case 13 shows. The incidence of complete block in cardiac infarction has been reported as 2 to 3 per cent (Kerr, 1937), but only a proportion of these have Stokes-Adams attacks or even syncopal symptoms.

Nodal rhythm was recorded in Case 11 immediately before a Stokes-Adams seizure, and was again recorded as soon as the convulsion had subsided though consciousness was not recovered and death occurred a few minutes later. A cerebral vascular complication, especially hæmorrhage, has to be considered here, but a further coronary occlusion with acute peripheral circulatory failure would fit in with the change in the ventricular complexes of the cardiogram after the attack.

In Case 14 syncopal attacks appeared on the third day of a cardiac infarct in a man who had slowly passed into a shocked condition. There was sinus tachycardia and short runs of auricular premature beats, the last suggesting that syncope was dependent on auricular paroxysmal tachycardia.

The Stokes-Adams attacks in Case 15 were peculiar in being preceded by great intensification of anginal pain which was located below the left scapula, the pulse at the same time becoming progressively weaker and slower. Cardiograms taken on three separate days between attacks all showed sinus tachycardia with normal A-V conduction, providing no clue to the mechanism involved. This might have been paroxysmal heart block with ventricular standstill except that in this condition the ventricle usually ceases abruptly without preliminary change in heart rate or force. (Parkinson, Papp, and Evans, 1941; Cookson, unpublished observation.) But in any attempt at an explanation the significance of the pain that heralded the attack must be taken into account and it may be that nervous reflexes arising in the heart were largely responsible. On this view the mechanism would be similar to that suggested for the initial syncopal symptoms.

No patient with syncope or Stokes-Adams seizures survived many days, indicating a prognosis even more serious than in the first group.

Summary

Among 200 patients with acute cardiac infarction, a syncopal or epileptiform attack was observed in 15. At the onset syncope occurred in ten, of whom five were aged 70 or more. They presented the appearance of severe

peripheral circulatory failure, often combined with a slow heart rate but in one there was ventricular tachycardia. Pain might be absent or slight. In five the cardiogram showed abnormal rhythms of supraventricular origin. Posterior infarction was commoner than anterior. Six of the patients had died by the fourth month. Possible causes of the syncope are briefly discussed.

Syncope and fits in the course of cardiac infarction are reported in five patients whose average age was 69. Two had suffered previously from anginal pain. Two had syncope and three had Stokes-Adams attacks. All five died within 29 days of the onset. Abnormal rhythms were recorded in four. Cardiograms during the actual attack showed complete heart block in one, and nodal rhythm with a change in the ventricular complex immediately after a short convulsion in another. Indirect evidence as to the mechanism underlying the attacks in the remaining cases is given.

References

Bean, W. B., and Read, C. T. (1942). *Amer. Heart J.*, 23, 362.
Boyd, L. J., and Werblow, S. C. (1937). *Amer. J. med. Sci.*, 194, 814.
Cushing, E. H., Feil, H. S., Stanton, E. J., and Wartman, W. B. (1942). *Brit. Heart J.*, 4, 17.
Gorham, L. W., and Martin, S. J. (1938). *Arch. intern. Med.*, 62, 821.
Gross, H., and Sternberg, W. H. (1939). *Arch. intern. Med.*, 64, 249.
Gross, L.(1921). *The Blood Supply to the Heart.* New York.
Hay, J. (1933). *Lancet*, 2, 787.
Kennedy, J. A. (1937). *Amer. Heart J.*, 14, 703.
Kerr, J. D. O. (1937). *Lancet*, 2, 1066.
Parkinson, J., Papp, C., and Evans, W. (1941). *Brit. Heart J.*, 3, 171.

PROCEEDINGS OF THE CARDIAC SOCIETY OF GREAT BRITAIN AND IRELAND

The SIXTH ANNUAL GENERAL MEETING of the Cardiac Society of Great Britain and Ireland was held in the School of Mineralogy Lecture Theatre, at Cambridge, on Friday, April 10, 1942.

CHAIRMAN: L. B. COLE

44 Members, 4 Temporary Members, and 8 Visitors were present.
The Chairman took the chair at 10.15 a.m.

PRIVATE BUSINESS

1. The minutes of the last meeting having been printed in the Journal were confirmed and signed.
2. The accounts, audited by Bramwell and Gibson, were presented by the Council and approved, the balance being £61 1*s.* 11*d.*
3. The following two new Members were elected :—

   E. J. Wayne, Sheffield, (Ordinary Member).
   Morgan Jones, Manchester, (Associate Member).

   Ten of the present Associate Members were re-elected for a further period of three years.
4. Terence East and William Evans were elected Members of the Council for the years 1942–46. Gilchrist was appointed to act as a Substitute Member on the Council, so long as Hill (1940–44) was abroad on service.
5. William Evans was appointed to act as Assistant Secretary for the year, and Shirley Smith was thanked for his services during the previous three years.
6. The Society decided that as a war measure the Council should have the power to invite certain members of the Empire Forces or other visitors interested in cardiology to become temporary members for the year, such members being supernumerary to the numbers allowed by the rules and not to pay any subscription.
7. The Secretary reported that :—
   (*a*) since the last meeting he had learnt with regret of the death of Graham Steell, another of the Honorary Members, and that Bramwell had written a notice for the British Heart Journal.
   (*b*) the Committee appointed last year to consider the appointment of members from other parts of the British Empire, had reported that owing to wartime difficulties it was not thought a good time to have any fresh developments in this direction, but that the present situation would best be met by the appointment of temporary members as had now been decided.
   (*c*) the position of the British Heart Journal was satisfactory and the circulation well maintained; and the printers had managed to produce the April 1941 number almost at the right date, in spite of the serious damage done at their works shortly before, and were meeting all the difficulties caused by the war most satisfactorily.

Discussion on Cardiac Defects Found at Recruiting Medical Boards
(*Morning Session*)

Starling gave his experiences as Chairman of a Medical Board. He spoke on the difficulty in the diagnosis of early endocardial lesions, especially by medical officers who were not primarily interested in cardiology. The presence of the functional systolic murmur which disappeared on full inspiration and often with a change of posture still occasioned much doubt in the minds of some members of the board. During two and a half years he had supervised the rejection of about 50 cardiac cases from the Services and 24 of these were cases of early mitral stenosis or aortic regurgitation. None of them had any symptoms nor did a number of them give a story of a past rheumatic infection. Starling also called attention to the confusion that existed at Medical Boards and also in the profession regarding the estimation of blood pressure and the interpretation of a raised one, and he particularly emphasized the need to take three readings before labelling a recruit as showing a raised blood pressure.

Short Communications

Cardiac Diagnosis in Recruits

John Parkinson presented some observations arising from routine examination of 500 candidates referred by recruiting medical boards for a cardiological examination because of suspected cardiac defects. Experience of diagnosis in civil life was gained mostly on developed disease with symptoms, whereas wartime provided a distinct opportunity for studying and codifying the first signs of early and symptomless cardiac disease. There was a wealth of borderline cases. Textbooks gave the characteristic rather than the earliest diagnostic signs, and comprehensive diagnosis might better be provided as (*a*) early diagnosis, (*b*) established diagnosis, and (*c*) differential diagnosis.

Aortic Incompetence was twice as common as mitral stenosis in these recruits. The apex-beat was affected in force or position in only half of the 50 clear cases, and then it rarely reached the sixth interspace. In half there was a mitral systolic murmur, which too often satisfied an examiner as being primarily mitral, but should certainly raise the possibility of a causative aortic incompetence. A loud aortic second sound might obscure the diastolic murmur. The blood pressure was valueless in the slighter cases. Left axis deviation was commonly absent, though T_2 and T_3 inversion was recorded with it in three cases, and T_1 inversion in none. Cardioscopy (X-ray screening of the heart) showed increased convexity of the left ventricle in most, and this was nicely confirmed in the left oblique position. Hearing the aortic diastolic murmur and seeing the enlarged left ventricle were the foundations of an early diagnosis, and attention should be concentrated on these.

Mitral Stenosis was studied in 25 early cases. There was no thrill, though the apex beat might be sudden in quality. A short presystolic murmur was heard in 15, but in 9 of these only immediately on lying on the left side after exertion. This invaluable technique was a bequest from the last world war. A sharp loud first sound at the apex is in itself insufficient, but a long loud and constant mitral systolic murmur needs only radiological support to establish the diagnosis. In the anterior view there may be a slight extension outwards of the left border of the heart in the conus region, not so much as a convexity—merely a broadening of the heart at the conus level. With this or without, in the right oblique view the left auricle (atrium) is seen to be enlarged because the opacified œsophagus *changes direction* backwards at a high level—at the top of the auricle. This early sign may precede any obvious increase in the

convexity of the auricle as a whole. Right axis deviation or P wave changes in the electrocardiogram are seldom of assistance in early diagnosis, both being absent in the majority.

Early High Blood Pressure. There were 18 cases with a blood pressure above 160/90, and an average of 175/100. Eight were aged 20–30 years, ten were aged 31–40. The apex beat was displaced or forcible (or both) in half the cases, and a mitral systolic murmur was noticeable also in half. Cardioscopic support was obtained in more than half the cases, the left ventricle being enlarged and unduly convex. Electrocardiographic evidence was almost valueless.

Various Cardiac Defects. There were 20, i.e. 4 per cent, with congenital lesions. In 30 healthy cases, it was simply the well-known apparent displacement of the apex-beat from slight scoliosis that led the medical board to suspect enlargement. Nervous tachycardia was the feature in 30 cases. There were 8 cases with slight thyroid enlargement, mostly without tachycardia. Coronary thrombosis had occurred in three recruits aged 31, 32, and 35 respectively.

In conclusion, attention was directed to :—

(1) The need for routine radioscopy by the cardiologist, and its usefulness in early diagnosis.

(2) The restricted value of the electrocardiograph for this purpose; only in doubtful arrhythmia or precocious anginal pain was it applicable to recruiting medical problems.

(3) A duty of the Cardiac Society to take a leading part after the war in pressing for national research on rheumatic fever in childhood.

The Electrocardiogram in Friedreich Disease

William Evans

(Published in full; p. 91)

Fainting and Fits in Cardiac Infarction

Harold Cookson

Apart from pain of great intensity, cerebral vascular complications, and sudden death, which might be regarded as the extreme form of syncopal attack, disturbances of consciousness had been noted in a small proportion of cases of acute cardiac infarction. The chief clinical features of 13 such cases were given. Faintness or loss of consciousness had occurred as the initial symptom in 9 and early examination had shown the picture of peripheral circulatory failure combined with bradycardia in most. Of 4 cases with disturbance of consciousness after the onset, three had Stokes-Adams attacks, on the first, fifth, and tenth days respectively ; in the fourth there was fainting on the third day associated with sinus tachycardia and short runs of auricular premature beats.

Cardiograms taken at the time of the attacks or at varying intervals thereafter had shown a disturbance of rhythm in the majority. All the common varieties of abnormal rhythm had been recorded. The site of infarction was nearly always posterior. Pain might be completely absent. Eight of the 13 patients had died within six weeks.

To account for the picture of peripheral circulatory failure combined with bradycardia seen in those with syncopal symptoms at the onset it was suggested that the factors were: (1) reflex vaso-motor depression and vagal stimulation; (2) a direct mechanical effect of the infarct on cardiac output; and (3) possibly ischæmia of the auricles; The last would fit in with the observation that the infarct was usually of the posterior type and also with the occurrence of rhythms depending on depression of the pacemaker and of auricular flutter and fibrillation.

(Published in full; p. 163)

Inversion of T Waves after Attacks of Angina Pectoris

Donald Hall and Kemball Price (*introduced*)

Kemball Price described a case in which inversion of the T wave in leads I and IV followed an attack of angina pectoris but only persisted for twelve days. The T wave in lead IV again became inverted after a further anginal attack and was directed upwards following amyl nitrate inhalation. Two months later the cardiographic changes remained permanent after prolonged pain; at necropsy cardiac infarction was found present. He suggested that during the first two attacks there might have been an interference with the blood supply to a portion of a muscle bundle, but short of infarction from occlusion of a main coronary artery.

After luncheon a demonstration was given on Hypertension of Renal Origin by E. B. Verney, F. J. Lockett, and W J. O'Connor (*all introduced*). Several dogs were shown in different stages where operations had been performed so that the blood-pressure could be measured in arterial loops and the blood supply to the kidney clamped in an accurate manner.

Discussion on the Importance of the Cardiovascular System in Aviation Medicine

Rook said that in *The Medical Examination of Candidates for Flying Training* too much stress can be placed on tests of cardiovascular efficiency. So long as there is no organic lesion of heart or vessels and the pulse rate and blood pressure readings are within fairly wide limits, most candidates can be accepted, whatever their reactions to the various tests, for it has been shown that proper training will soon bring their physical efficiency to a high level. Of all the factors necessary to make a war-time pilot, temperament is the most important; physical efficiency can be improved, temperament is largely unalterable, at any rate within a short period.

Operational Flying throws a strain on the cardiovascular system chiefly in two ways, firstly owing to the effect of altitude and secondly as the result of variations in speed. *Anoxia* begins to show its effect fairly early in an ascent causing, at first, increase in the pulse rate and in the pulse pressure. The severity of the effects depends on certain variable factors : (1) the altitude to which the ascent is made; (2) the duration of stay at altitude; and (3) the rate of ascent. In pilots acclimatization to altitude such as occurs in mountaineers is almost unknown and permanent changes in the size of the heart or in the blood are rarely seen. Actually deterioration is more likely to occur than acclimatization. The normal cardiovascular system can withstand anoxia better than most of the other systems of the body, and the circulation may still be going on when respiration and all reflexes have ceased. With the damaged heart anoxia is a potent factor in producing symptoms and may lead to failure.

The effects of *Acceleration and Deceleration* are especially of importance to the war-time pilot. These effects are met with chiefly while caterpulting or during turns at high speeds. The resultant forces may cause symptoms by their action on the more fluid parts of the body, principally the blood. On the arterial side these forces interfere with the flow of the blood, while on the venous side they prevent return to the auricles and lead to inadequate filling of the ventricles. In most instances the forces act from the head towards the legs (positive accelerations) producing an anæmia of the brain and causing symptoms that include temporary blindness and possibly actual loss of consciousness. If the forces act from the legs towards the head (negative accelerations) intense engorgement of the cerebral vessels and severe symptoms may result. Transverse accelerations, which act across the long axis of the body, affect the cardiovascular system least. It is possible by bracing the abdominal muscles and bending

forward so that the forces act partly transversely to counteract the effect of positive accelerations to some extent.

SQUADRON LEADER W. K. STEWART, A.F.C. (*introduced*), from the Royal Air Force Physiological Laboratory, demonstrated a film showing the effect of positive acceleration occurring during actual flight.

HEMIPLEGIA IN CYANOTIC CONGENITAL HEART DISEASE

BRUCE PERRY

(Published in full; p. 121)

SYPHILITIC ANGINA PECTORIS

EVAN BEDFORD AND EVAN JONES

(To be published in full)

LIGATURE OF SIX CASES OF INFECTED DUCTUS ARTERIOSUS

BOURNE reported six cases (the first already reported in this Journal, Vol. 3, 228, 1941), all of whom survived the operation by six weeks or more, and five of whom completely recovered; one case with a mycotic aneurysm died showing a continuation of the infection. One was alive 27 months and another 17 months after the operation. Four were back at full work. Chemotherapy was used as an adjunct to ligature, but that ligation was the effective factor was proved by the fact that it produced cure when chemotherapy failed or when chemotherapy was withheld. In all cases the diastolic pressure increased greatly after the operation but became lowered to the normal after a period of six weeks or so. The systolic pressure was increased to a lesser extent. The heart in the only case in which accurate pre-operative measurement on cardioscopy was possible was found to be 2 cm. less in its transverse diameter 17 months after the operation; the previously enlarged pulmonary conus had disappeared. In this case and in one other the typical systolic-diastolic murmur returned after an interval and the cause of this was obscure because the blood pressure and heart outline continued to be normal.

CHEST LEAD, CR_7, IN POSTERIOR CARDIAC INFARCTION

A. HUNTER (*introduced*) AND WILLIAM EVANS mentioned the difficulties in diagnosis between inversion of the T wave in lead III in posterior cardiac infarction and in other conditions, either in health or disease. He showed the results obtained from the use of a chest lead (CR_7) in which an exploring electrode was placed in the left posterior axillary line and paired with one on the right arm. Changes towards inversion of the T wave in this lead appeared in the majority of cases of cardiac infarction although it was shown as well in the limb leads, but its importance was found in confirming the physiological nature of inversion of the T_3 in health for the CR_7 was always upright in this circumstance. Apart from assisting in the diagnosis of physiological inversion of the T_3 from the inverted T_3 of cardiac infarction, the chest lead CR_7 was also found to aid the recognition of the cardiogram of pericardial disease which might suggest posterior cardiac infarction.

(To be published in full.)

THE RETURN OF NORMAL RHYTHM AFTER TOTAL THYROIDECTOMY FOR MITRAL STENOSIS AND AURICULAR FIBRILLATION

COOKSON said that occasional cases had been reported, suggesting that the secretion of the normal thyroid gland might lead to the development of auricular fibrillation in non-goitrous heart disease. In two cases seen by Cookson, in which toxic goitre, mitral stenosis, and auricular fibrillation had been combined, total thyroidectomy had been carried out, and in each case the rhythm had returned to normal spontaneously. An account was given of the clinical condition and autopsy findings in a woman with mitral stenosis, auricular fibrillation, and recurrent failure. Her whole thyroid had been removed, and three or four months after the operation, when signs of myxœdema were obvious, normal rhythm was found to have returned. There were then no signs of failure and her effort tolerance had improved. The radiogram, however, showed considerable increase in the cardiac silhouette and resembled in shape that of pericardial effusion. The patient remained well for four months. Symptoms and signs of failure then appeared but the pulse remained regular. She died after a week's illness; necropsy showed advanced mitral stenosis and the pericardium contained 24 oz. of clear yellow fluid. It was considered probable that severe myxœdema had played a part in the final breakdown, particularly through the effect of a large pericardial effusion.

* * * * * *

* * * * *

The dinner was held at Caius by kind permission of the Bursar. EMMANUEL proposed the health of the Society.

BRAMWELL proposed the health of the guests, including the Master and the President of the College of Physicians. The Master replied on behalf of the guests.

INDEX

A

A curious syndrome, with signs suggesting cervical arterio-venous fistula, with pulses in neck and arms lost (Thomas Lewis and Joan Stokes). 57.
Arterio-venous fistula, with pulses in neck and arms lost, a curious syndrome, with signs suggesting cervical (Thomas Lewis and Joan Stokes). 57.
Atrial septal defect, congenital pulmonary stenosis with left ventricular enlargement associated with (Paul Wood). 11.
Auricles (atria), infarction of the cardiac (E. H. Cushing, H. S. Feil, E. J. Stanton, and W. B. Wartman). 17.

B

Barber, Hugh: Electrocardiographic changes due to trauma. 83.
Blood pressure and old age (Trevor H. Howell). 143.
Bramwell, Crighton: Graham Steell. 115.
Bundle branch block, prognosis of right (George A. Perera, Samuel A. Levine, and Herman Erlanger). 35.

C

Campbell, Maurice: Inversion of T waves after long paroxysms of tachycardia. 49.
——: Partial heart block due to digitalis. 131.
Cardiac auricles (atria), infarction of the (E. H. Cushing, H. S. Feil, E. J. Stanton and W. B. Wartman). 17.
Cardiac infarction, fainting and fits in (Harold Cookson). 163.
Cardiac Society of Great Britain and Ireland, Proceedings of the. 174.
Castleden, L. I. M. (and J. L. Hamilton-Paterson): Intracardiac tumours. 103.
Cerebral thrombosis and hemiplegia, congenital pulmonary atresia with (Alastair Hunter and John M. Lipscomb). 124.
Cervical arterio-venous fistula, with pulses in neck and arms lost, a curious syndrome with signs suggesting (Thomas Lewis and Joan Stokes). 57.
Chest leads in congenital and acquired dextrocardia (J. S. Richardson). 80.
Conducting system of the vertebrate heart, the (Francis Davis). 66.
Congenital and acquired dextrocardia, chest leads in (J. S. Richardson). 80.
Congenital heart block (William Stein and J. S. Uhr). 7.
Congenital heart disease, hemiplegia in cyanotic (Beryl Corner and Bruce Perry) 121.
Congenital pulmonary atresia with cerebral thrombosis and hemiplegia (Alastair Hunter and John M. Lipscomb). 124.
Congenital pulmonary stenosis with left ventricular enlargement associated with atrial septal defect (Paul Wood). 11.
Cooke, W. Trevor (and Paul D. White): Prognosis of paroxysmal tachycardia and paroxysmal auricular fibrillation. 153.
Cookson, Harold: Fainting and fits in cardiac infarction. 163.
Corner, Beryl (and Bruce Perry): Hemiplegia in cyanotic congenital heart disease. 121.
Currie, George M.: Transient inverted T waves after paroxysmal tachycardia. 149.
Cushing, E. H. (and H. S. Feil, E. J. Stanton, and W. B. Wartman): Infarction of the cardiac auricles (atria). 17.
Cyanotic congenital heart disease, hemiplegia in (Beryl Corner and Bruce Perry). 121.

D

Davis, Francis: The conducting system of the vertebrate heart. 66.
Dextrocardia, chest leads in congenital and acquired (J. S. Richardson). 80.
Digitalis, partial heart block due to (Maurice Campbell). 131.
Digitalis poisoning, two cases of (K. Douglas Wilkinson). 1.
Dr. Samuel Johnson: the medical history as recorded by James Boswell (Terence East). 43

E

East, Terence: Dr. Samuel Johnson: the medical history as recorded by James Boswell. 43.
Electrocardiogram in Friedreich disease (William Evans and Gordon Wright). 91.
Electrocardiographic changes due to trauma (Hugh Barber). 83.
Erlanger, H. (and G. A. Perera and S. A. Levine): Prognosis of right bundle branch block. 35.
Evans, William (and Gordon Wright): Electrocardiogram in Friedreich disease. 91.

F

Fainting and fits in cardiac infarction (Harold Cookson). 163.
Feil, H. S. (and E. H. Cushing, E. J. Stanton, and W. B. Wartman): Infarction of the cardiac auricles (atria). 17.
Fits in cardiac infarction, fainting and (Harold Cookson). 163.
Friedreich disease, electrocardiogram in (William Evans and Gordon Wright). 91.

G

Graham Steell (Crighton Bramwell). 115.

H

Hamilton-Paterson, J. L. (and L. I. M. Castleden): Intracardiac tumours. 103.
Heart block, congenital (William Stein and J. S. Uhr). 7.
Hemiplegia, congenital pulmonary atresia with cerebral thrombosis and (Alastair Hunter and John M. Lipscomb). 124.
Hemiplegia in cyanotic congenital heart disease (Beryl Corner and Bruce Perry). 121.
Historical note, the sino-auricular node; a (Arthur Keith). 77.
Howell, Trevor H.: Blood pressure and old age. 143.
Hunter, Alastair (and John M. Lipscomb): Congenital pulmonary atresia with cerebral thrombosis and hemiplegia. 124.

I

Index. 180.
Infarction of the cardiac auricles (atria) (E. H. Cushing, H. S. Feil, E. J. Stanton, and W. B. Wartman). 17.
Intracardiac tumours (J. L. Hamilton-Paterson and L. I. M. Castleden). 103.
Inversion of T waves after long paroxysms of tachycardia (Maurice Campbell). 49.

J

Johnson, Dr. Samuel: the medical history as recorded by James Boswell (Terence East). 43.

K

Keith, Arthur: The sino-auricular node: a historical note. 77.

L

Levine, Samuel A. (George A. Perera and Herman Erlanger): Prognosis of right bundle branch block. 35.
Lewis, Thomas (and Joan Stokes): A curious syndrome, with signs suggesting cervical arterio-venous fistula, with pulses in neck and arms lost. 57.
Lipscomb, John M. (and Alastair Hunter): Congenital pulmonary atresia with cerebral thrombosis and hemiplegia. 124.

O

Old age, blood pressure and (Trevor H. Howell). 143

P

Paroxysmal auricular fibrillation, prognosis of paroxysmal tachycardia and (W. Trevor Cooke and Paul D. White). 153.
Paroxysmal tachycardia and paroxysmal auricular fibrillation, prognosis of (W. Trevor Cooke and Paul D. White). 153.
Paroxysmal tachycardia, transient inverted T waves after (George M. Currie). 149.
Paroxysms of tachycardia, inversion of T waves after long (Maurice Campbell). 49.
Partial heart block due to digitalis (Maurice Campbell). 131.
Perera, G. A. (and S. A. Levine and H. Erlanger): Prognosis of right bundle branch block. 35.
Perry, Bruce (and Beryl Corner): Hemiplegia in cyanotic congenital heart disease. 121.

Proceedings of the Cardiac Society of Great Britain and Ireland. 174.
Prognosis of paroxysmal tachycardia and paroxysmal auricular fibrillation (W. Trevor Cooke and Paul D. White). 153.
Prognosis of right bundle branch block (G. A. Perera, S. A. Levine, and H. Erlanger). 35.
Pulmonary stenosis with left ventricular enlargement associated with atrial septal defect, congenital (Paul Wood). 11.

R

Richardson, J. S : Chest leads in congenital and acquired dextrocardia. 80.

S

Sino-auricular node: a historical note, the (Arthur Keith). 77.
Stanton, E. J. (and E. H. Cushing, H. S. Feil, and W. B. Wartman): Infarction of the cardiac auricles (atria). 17.
Steell, Graham (Crighton Bramwell). 115.
Stein, W. (and J. S. Uhr): Congenital heart block. 7.
Stokes, Joan (and Thomas Lewis): A curious syndrome, with signs suggesting cervical arterio-venous fistula, with pulses in neck and arms lost. 57.

T

Tachycardia, inversion of T waves after long paroxysms of (Maurice Campbell). 49.
Transient inverted T waves after paroxysmal tachycardia (George M. Currie). 149.
Trauma, electrocardiographic changes due to (Hugh Barber). 83.
Tumours, intracardiac (J. L. Hamilton-Paterson and L. I. M. Castleden). 103.
Two cases of digitalis poisoning (K. Douglas Wilkinson). 1.

U

Uhr, J. S. (and W. Stein): Congenital heart block. 7.

V

Vertebrate heart, the conducting system of the (Francis Davis). 66.

W

Wartman, W. B. (and E. H. Cushing, H. S. Feil, and E. J. Stanton): Infarction of the cardiac auricles (atria). 17.
White, Paul D. (and W. Trevor Cooke): Prognosis of paroxysmal tachycardia and paroxysmal auricular fibrillation. 153.
Wilkinson, K. D.: Two cases of digitalis poisoning. 1.
Wood, Paul: Congenital pulmonary stenosis with left ventricular enlargement associated with atrial septal defect. 11.
Wright, Gordon (and William Evans): Electrocardiogram in Friedreich disease. 91.

MADE AND PRINTED IN GREAT BRITAIN BY
D. R. HILLMAN & SONS LTD
FROME